

## Case report

## Oral ulcer as presentation of cavitating pulmonary tuberculosis

Joana Fragoso<sup>a,\*</sup>, Mariana Marques Oliveira<sup>b</sup>, Celina Gonçalves<sup>a,c</sup>, Josefina Méndez<sup>a</sup>, Rui Sarmento-Castro<sup>a</sup>

<sup>a</sup>Serviço de Doenças Infecciosas do Centro Hospitalar Universitário do Porto, Portugal

<sup>b</sup>Serviço de Anatomia Patológica do Centro Hospitalar Universitário do Porto, Portugal

<sup>c</sup>Serviço de Cuidados Intensivos do Centro Hospitalar Universitário do Porto, Portugal

## ARTICLE INFO

## Article history:

Received 22 August 2020

Received in revised form 26 September 2020

Accepted 26 September 2020

## Keywords:

Pulmonary tuberculosis

Tuberculous oral ulcer

*Mycobacterium tuberculosis*

## ABSTRACT

Tuberculosis is an indolent infection that can invade any organ. Although the most frequent form of presentation is pulmonary, it can have an extra-pulmonary presentation, including rare cases of oral tuberculosis.

We present a clinical case of a 44 year-old man, active smoker, with an ulcerated lesion on the posterior third of the tongue, initially interpreted as a probable neoplasm. The pathological study of the biopsy performed on the lesion, showed alterations compatible with a chronic granulomatous process and the presence of acid-fast bacilli. The concomitant diagnosis of pulmonary tuberculosis was made in a subsequent study. The patient started therapy with isoniazid, rifampin, pyrazinamide and ethambutol with complete resolution of the oral lesion and pulmonary tuberculosis. This case exemplifies the importance of including tuberculosis in the differential diagnosis of ulcerated and neoformative lesions and the value of performing a microbiological study alongside the pathological one.

© 2020 The Authors. Published by Elsevier Ltd. This is an open access article under the CC BY-NC-ND license (<http://creativecommons.org/licenses/by-nc-nd/4.0/>).

## Introduction

Tuberculosis is a severe chronic infection caused by *Mycobacterium tuberculosis* and transmitted by aerosols. Although most people do not develop the disease, about 5% of exposed adults will develop the disease in the first two years after exposure [1]. Pulmonary tuberculosis is the most common form of the disease, but extrapulmonary involvement presents in 10–15 % of the cases and may be the only manifestation [2].

Tuberculosis of the oral cavity is uncommon, presenting in 0.05–5% of patients with tuberculosis [3] and may be the first sign of the disease [4]. It usually presents as superficial ulcers, plaques and papillomatous or indurated lesions [5]. Thus, the differential diagnosis of tuberculosis must be considered in ulcerated lesions, in order to have an early diagnosis and treatment aimed at this contagious disease with a relevant clinical and epidemiological impact.

## Case report

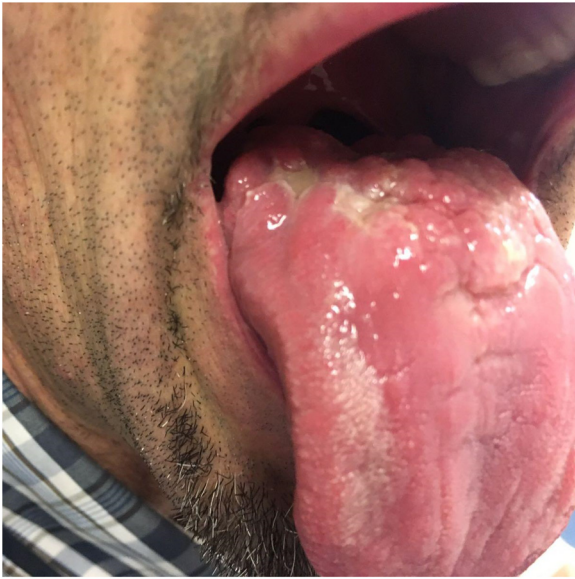A 44-year-old man, smoker of 35 pack years and ex-user of intravenous drugs, came to the emergency department with a

history of a painful ulcerated lesion, in the posterior third on the dorsum of the tongue with four months of evolution. In association, he reported weight loss of seven kilograms (>10 % of usual weight). The patient was evaluated by Otorhinolaryngology, who described a papillomatous, hardened and painful lesion measuring about three centimeters in the posterior third of the tongue, accompanied by bilateral cervical lymphadenopathies, with a tentative diagnosis of squamous cell carcinoma (Fig. 1).

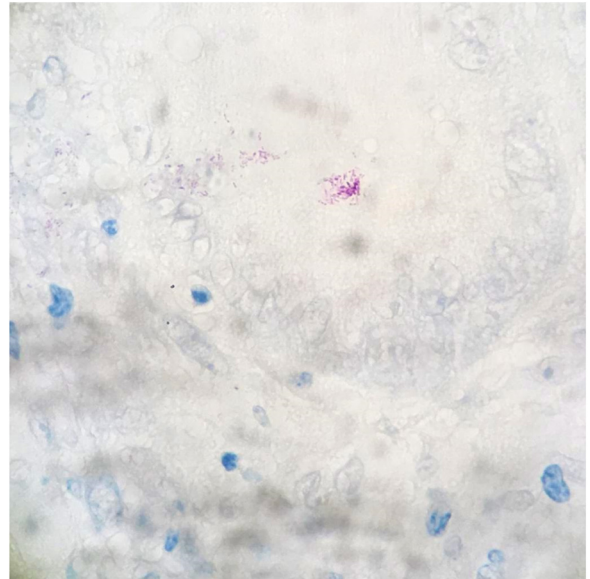
A biopsy was performed one week after the emergency episode, along with a complete study with chest and neck computer tomography (CT) for staging. The anatomical pathology studied excluded a neoplastic lesion, instead, it showed infiltration by numerous epithelioid granulomas, some with central necrosis and frequently accompanied by giant multinucleated cells of the Langhans type (Fig. 2). Ziehl-Neelsen staining revealed the presence of occasional acid-fast bacillary structures (Fig. 3).

In view of these results, the patient was referred to the Infectious Diseases consultation. Exploring the epidemiological context, he reported having a cousin with a recent diagnosis and treatment of tuberculosis (eight months ago) with whom he had daily contact. The patient's tuberculous screening, at the time of his cousin's diagnosis, was negative. The patient denied cough or sputum more than usual (he was an active smoker), night sweats, or asthenia. He also denied anorexia but admitted weight loss, in the previous four months, of seven kilograms (weight at the first consultation of Infectious Diseases was 56 kg, body mass index of 17.8).

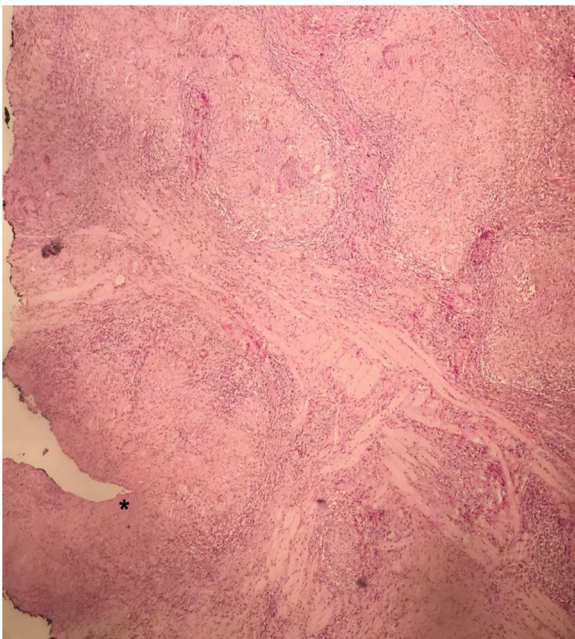
\* Corresponding author at: Serviço de Doenças Infecciosas do Centro Hospitalar Universitário do Porto, EPE, Largo Abel Salazar, 4099-001, Porto, Portugal.  
E-mail address: [joana.fragoso@chporto.min-saude.pt](mailto:joana.fragoso@chporto.min-saude.pt) (J. Fragoso).



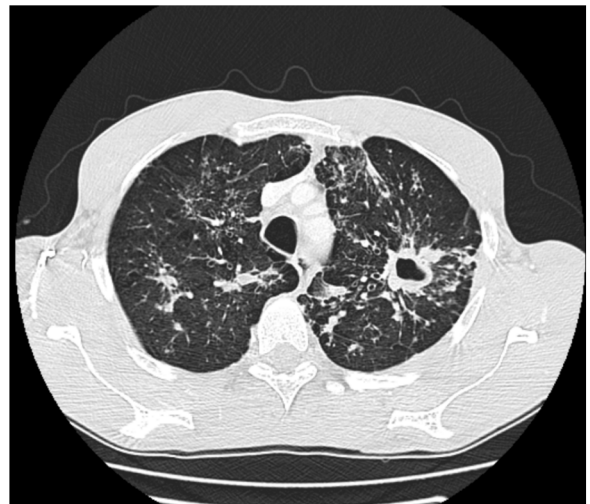
**Fig. 1.** Ulcer on the dorsum of the tongue.



**Fig. 3.** Acid-fast bacilli as seen with the Ziehl-Neelsen staining (1000x).



**Fig. 2.** Numerous epithelioid granulomas that infiltrate the mucous and muscular tissue, along with giant multinucleated cells. Some of the granulomas have central necrosis (\*), (hematoxylin-eosin, 40x).



**Fig. 4.** Thorax computerized tomography demonstrating bilateral tree-in-bud pattern and cavitation in the left lung.

The chest x-ray showed an infiltrate on the left upper lobe on the chest radiograph. The chest CT showed a tree-in-bud pattern and cavitations (Fig. 4.). Analytically without leukocytosis, with sedimentation rate of 74 mm/h, mild anemia of 12.7 g/dL, normochromic and normocytic. Liver function and kidney function were normal. C-reactive protein of 23.7 mg/L (cut-off <5 mg/L).

Bronchial secretions were collected whose auramine study was positive for acid-fast bacilli, and GeneXpert® positive for *Mycobacterium tuberculosis* complex with negative rifampin resistance testing. Mycobacteria culture showed growth of *Mycobacterium tuberculosis*, whose sensitivity test demonstrated susceptibility to all first-line antituberculous drugs. It is also noteworthy to mention that the patient showed negative human

immunodeficiency virus serology (HIV), had past contact with hepatitis B virus (HBV) and was diagnosed with chronic hepatitis C virus infection (HCV) (positive antibody with positive HCV ribonucleic acid (RNA)), which was staged and treated later on. The patient completed nine months of treatment (isoniazid, rifampin, pyrazinamide, and ethambutol regimen), with total resolution of the tongue lesion (Fig. 5.) and weight recovery.

**Discussion**

Tuberculosis has a high prevalence worldwide with a quarter of the world population infected, and 10 000 000 new cases of the disease in 2018 [6]. Portugal is considered, since 2015, a country of low incidence of tuberculosis [7], however, there are regions of the country, namely in the districts of Oporto and Lisbon where this is highest with an incidence rate of 25.3 and 23.7 per 100,000 inhabitants in 2018 [8], respectively. The most common form of presentation of the disease is pulmonary, but up to 15 % of patients have extrapulmonary forms, the most common being ganglionic and pleural [7].

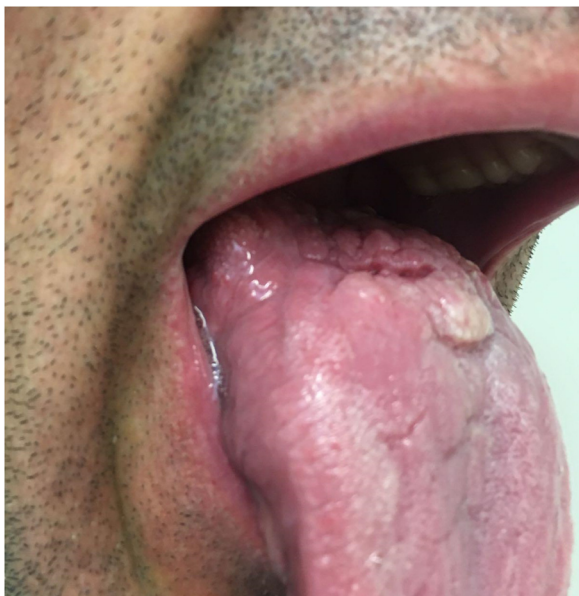

Fig. 5. Dorsum of the tongue, at the end of treatment.

Tuberculosis of the oral cavity is uncommon [3] but can be the primary presentation of the disease. This type of manifestation is more often secondary to pulmonary tuberculosis through contact of the mouth with infected secretions [5,9]. Tuberculosis of the oral cavity can have variable manifestations: ulcers, nodules, fissures, granulomas. The most frequent is the appearance of a superficial ulcer [3]. The diagnostic anatomopathological findings demonstrate granulomas with giant Langhans cells, which may be accompanied by the presence of acid-fast bacilli [4,9].

The present case is nonetheless particular because, the main clinical manifestation, and for which the patient sought health care, was the ulcer on the dorsum of the tongue. Due to the diagnosis of tuberculosis, but also due to a history of intravenous drug use in the past, HIV, HCV and HBV serology was requested. Of these, only HCV serology was positive with HCV-RNA also positive, with a diagnosis of chronic hepatitis C. The treatment was delayed until the end of tuberculosis treatment.

As the antibacterial sensitivity test demonstrated susceptibility to all first-line drugs and since the patient was diagnosed with cavitated pulmonary tuberculosis, he was treated with a classic regimen for nine months. The patient responded well to the treatment with improvement and progressed favourably with weight recovery and complete resolution of the ulcerated lesion (Fig. 5.).

The present case highlights the importance of tuberculosis being considered in the differential diagnosis of this type of lesions, especially when there is a suggestive epidemiological context that should always be questioned to the patient. Adequate diagnosis and treatment are central to curbing the spread of the infection and improving the patient's prognosis.

## Declaration of Competing Interest

The authors declare that they have no conflict of interest in relation to this article.

## Funding

This research did not receive any specific grant from funding agencies in the public, commercial, or not-for-profit sectors.

## Consent

Written informed consent was obtained from the patient for publication of this case report and accompanying images. A copy of the written consent is available for review by the Editor-in-Chief of this journal on request.

## Author contribution

Joana Fragoso – data collection, writing, analysis; Mariana Oliveira – Data collection; Celina Gonçalves – writing, analysis; Josefina Méndez – analysis; Rui Sarmiento-Castro – analysis

## Data confidentiality

The authors declare to have followed the protocols of their work centre regarding the publication of data.

## References

- [1] Menzies NA, Wolf E, Connors D, Bellerose M, Sbarra A, Cohen T, et al. Progression from latent infection to active disease in dynamic tuberculosis transmission models: a systematic review of the validity of modelling assumptions. *Lancet Infect Dis* 2018;18(8):e228–38, doi:http://dx.doi.org/10.1016/S1473-3099(18)30134-8.
- [2] Qian X, Albers AE, Nguyen DTM, Dong Y, Zhang Y, Schreiber F, et al. Head and neck tuberculosis: literature review and meta-analysis. *Tuberculosis* 2019;116 (November 2018):S78–88, doi:http://dx.doi.org/10.1016/j.tube.2019.04.014.
- [3] Jain P, Jain I. Oral manifestations of tuberculosis: step towards early diagnosis. *J Clin Diagn Res* 2014;8(12):ZE18–21, doi:http://dx.doi.org/10.7860/JCDR/2014/10080.5281.
- [4] Kim SY, Byun JS, Choi JK, Jung JK. A case report of a tongue ulcer presented as the first sign of occult tuberculosis. *BMC Oral Health* 2019;19(1):1–5, doi:http://dx.doi.org/10.1186/s12903-019-0764-y.
- [5] Sharma S, Bajpai J, Pathak PK, Pradhan A, Singh PKS. Oral tuberculosis - Current concepts. *J Fam Med Prim Care*. 2019;(8):1308–12.
- [6] Global tuberculosis report 2019. Geneva: World Health Organization; 2019 Licence: CC BY-NC-SA 3.0 IGO.
- [7] Programa nacional para a tuberculose, tuberculose em Portugal, desafios e estratégias 2018. Direcção Geral de Saúde; 2018. . accessed on 28th July 2020 <https://www.dgs.pt/portal-da-estatistica-da-saude/diretorio-de-informacao/diretorio-de-informacao/por-serie-963780-pdf.aspx?v=%3D%3DDwAAAB%2BLCAAAAAAABArySzltzVUy81MsTU1MDAFahzFEfkPAAAA>.
- [8] Programa Nacional para a Tuberculose - Tuberculose em Portugal: dados provisórios- 2018. Direcção Geral de Saúde; 2019. . accessed on 28th July 2020 <https://www.dgs.pt/portal-da-estatistica-da-saude/diretorio-de-informacao/diretorio-de-informacao/por-serie-1104304-pdf.aspx?v=%3D%3DDwAAAB%2BLCAAAAAAABArySzltzVUy81MsTU1MDAFahzFEfkPAAAA>.
- [9] Wu YH, Chang JYF, Sun A, Chiang CP. Oral tuberculosis. *J Formos Med Assoc* 2017;116(1):64–5, doi:http://dx.doi.org/10.1016/j.jfma.2016.10.016.