

## Letter: Penile Kaposi sarcoma: A case of complete resolution with highly active antiretroviral therapy alone

Teresa Pinto-Almeida, Tiago Torres, Aristóteles Rosmaninho, Madalena Sanches, Rosário Alves, Mónica Caetano, Manuela Selores

Dermatology Online Journal 17 (6): 12

Department of Dermatology, Centro Hospitalar do Porto, Hospital de Santo António, Porto, Portugal

### Abstract

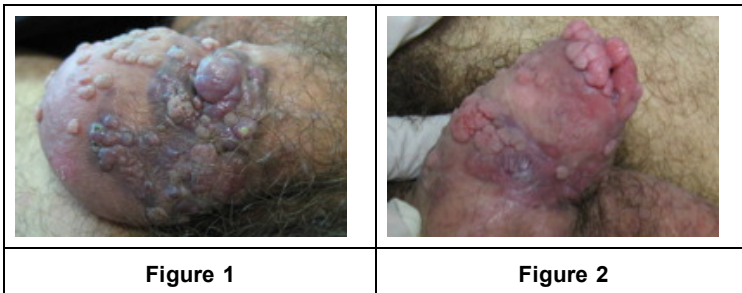
Kaposi sarcoma remains an important cause of morbidity in HIV-infected patients. Regardless of the recent pharmacological progress, treatment of this malignancy is still disappointing. We report the case of a patient with Kaposi sarcoma in an unusual localization, the penis, which completely resolved with highly active antiretroviral therapy alone.

### Introduction

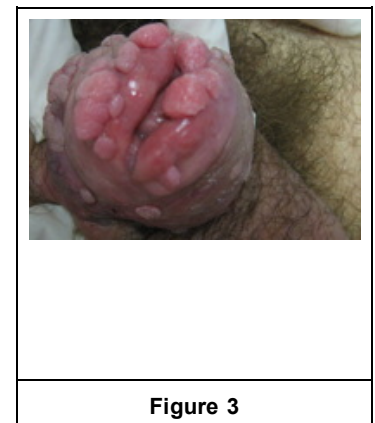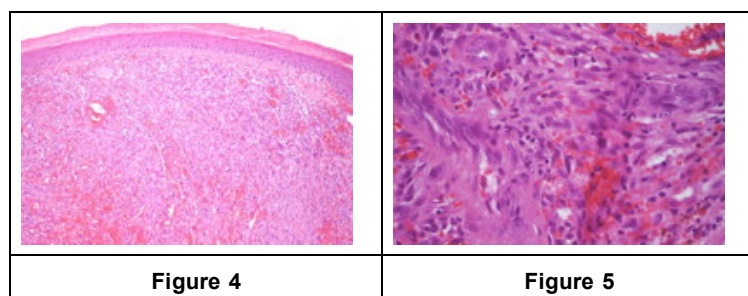
Kaposi sarcoma (KS) is the most common acquired immunodeficiency syndrome (AIDS)-associated malignancy. The initial lesion of AIDS-associated KS usually develops on the face, trunk, or oral mucosa. The presentation of this tumor on the penis is exceedingly rare. Since the introduction of highly active anti-retroviral therapy (HAART), the incidence of KS declined sharply [1, 2, 3]. Nevertheless, the management of KS remains unsatisfactory and a definitive treatment has not yet been established.

### Case report

A 47-year-old man presented with exuberant asymptomatic penile papules and small nodules that rapidly enlarged over the last six months. Human immunodeficiency virus (HIV) type 1 infection had been diagnosed the previous month. No other past medical history was relevant and he was on no regular medication.



Physical examination revealed violaceous confluent nodules with a smooth lobular surface, 5-10 mm in diameter, occupying the entire circumference of the corona. In addition, multiple skin-colored verrucous papules, from 2 to 5 mm in diameter, were distributed over the foreskin and glans. No other findings were noted.



Histopathological examination of the violaceous lesions revealed vascular proliferation at all levels of the dermis; fascicles of spindle cells replaced the dermal collagen and were separated by dilated and angulated vascular spaces, in a slit-like pattern; the mitotic index was low. These findings were consistent with KS.

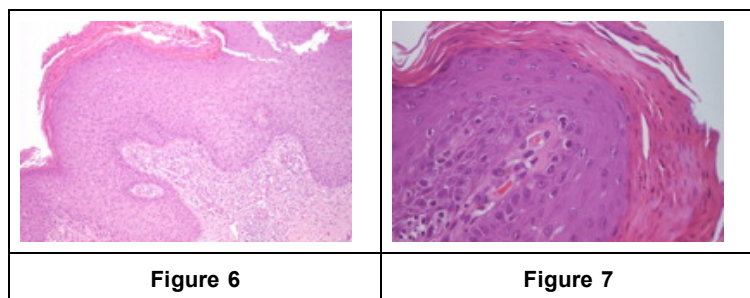


Figure 6

Figure 7

Histopathology of the skin-colored lesions showed acanthosis, parakeratosis, elongation, and fusion of the rete ridges, vascular dilation, and the presence of koilocytes – compatible with genital warts. High risk human papillomaviruses (HPV) were excluded by molecular biology.

CD4 lymphocyte counts were low (69/mm<sup>3</sup>) and viral load was high (16034 copies/mL). The remainder of the blood studies and CT scans of the thorax, abdomen and pelvis were unremarkable. According to these findings and to the AIDS Clinical Trials Group staging classification, this was a low risk KS (tumor confined to skin - T0; CD4 lower than 150/mm<sup>3</sup> - I1; no systemic illness - S0). Surgical treatment was proposed but the patient refused any kind of intervention. In the meantime, he started HAART: emtricitabine 200mg qd, tenofovir 245 mg qd and efavirenz 600 mg qd, with good clinical, immunological and viral responses. Viral suppression was accomplished at the seventh month.

After twenty months of HAART therapy alone, complete clinical remission of the cutaneous lesions, both the KS and the verrucae, was achieved. At this point, his viral load was suppressed (HIV-1 < 20 copies/mL) and CD4 counts were 196/mL. After 1 year of follow-up the patient remains free of lesions.

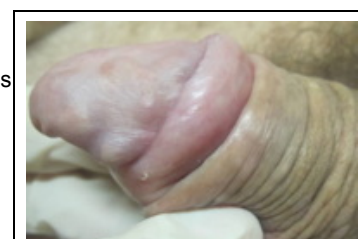


Figure 8

## Discussion

In the pre-HAART era, complete resolution of KS was uncommon and, when it occurred, responses were short-lived. Multiple studies have documented complete remission of KS with HAART alone and support its use as a first line therapy in the management of this malignancy [4]. In localized disease, long lasting responses occur in more than half of the patients [5]. On the other hand, when advanced disease is present, additional therapy is necessary, for instance, chemotherapy. The reason why HAART is effective in KS is not completely elucidated. HIV suppression appears to be crucial and is considered the best predictor of response; this is attributable to the consequent inhibition of Human Herpesvirus 8 (HHV8) replication and a decrease in the HIV-associated Tat protein, which is angiogenic and anti-apoptotic [6, 7, 8]. Immune reconstitution is also important, by recovering the anti-HHV8 response [6, 8]. HAART itself is thought to play a role, with direct anti-angiogenic and anti-tumor properties [6]. Although controversial, KS remission seems to be independent of CD4 counts [7].

Clearly, other mechanisms must be involved, given that not every case of localized KS responds to HAART alone [6] and sometimes KS develops in patients already receiving HAART, despite good control of HIV infection [1, 5]. Further studies are needed to understand better the underlying molecular pathways and will certainly provide new insights into novel targeted therapies.

## References

1. Franceschi S, Dal Maso L, Rickenbach M, Polesel J, Hirschel B, Cavassini M, Bordoni A, Elzi L, Ess S, Jundt G, Mueller N, Clifford GM and the Swiss HIV Cohort Study. Kaposi Sarcoma incidence in the Swiss HIV Cohort Study before and after highly active antiretroviral therapy. *Br J Cancer* 2008; 99: 800-4. [PubMed]
2. Puhan MA, Van Natta ML, Palella FJ, Adessi A, Meinert C. Excess mortality in patients with AIDS in the era of highly active antiretroviral therapy: temporal changes and risk factors. *Clin Infect Dis* 2010;51(8):947-56. [PubMed]
3. Mocroft A, Kirk O, Clumeck N, Gargalianos-Kakolyris P, Trocha H, Chentsova N, Antunes F, Stellbrink HJ, Phillips AN, Lundgren JD. The changing pattern of Kaposi sarcoma in patients with HIV, 1994-2003. The EuroSIDA study. *Cancer* 2004;100:2644-54. [PubMed]
4. Nguyen HQ, Magaret AS, Kitahata MM, Van Rompaey SE, Wald A, Casper C. Persistent Kaposi sarcoma in the era of HAART: characterizing the predictors of clinical response. *AIDS* 2008;22(8):937-45. [PubMed]
5. Nasti G, Martellota F, Berretta M, Mena M, Fasan M, Di Perri G, Talamini R, Pagano G, Montroni M, Cinelli R, Vaccher E, Monforte AA, Tirelli U. Impact of highly active antiretroviral therapy on the presenting features and outcome of patients with acquired immunodeficiency syndrome-related Kaposi sarcoma. *Cancer* 2003; 98: 2440-6. [PubMed]
6. Stebbing J, Portsmouth S, Gazzard B. How does HAART lead to the resolution of Kaposi's sarcoma? *J Antimicrob Chemoth* 2003; 51: 1095-8. [PubMed]
7. Martinez V, Caumes E, Gambotti L, Ittah H, Morini J-P, Deleuze J, Gorin I, Katlama C, Bricaire F, Dupin N. Remission from Kaposi's sarcoma on HAART is associated with suppression of HIV replication and is independent of protease inhibitor therapy. *Br J*

Cancer 2006; 94: 1000-6. [**PubMed**]

8. Viejo-Borbolla A, Schulz TF. Kaposi's sarcoma-associated Herpesvirus (KSHV/HHV8): key aspects of epidemiology and pathogenesis. AIDS Rev 2003; 5: 222-9. [**PubMed**]

9. Dittmer DP, Vahrson W, Staudt M, Hilscher C, Fakhari FD. Kaposi's sarcoma in the era of HAART - An update on mechanisms. Diagnostics and treatment. AIDS Rev 2005;7:56-61. [**PubMed**]

© 2011 Dermatology Online Journal