

A temporary corneal ectasia following airbag trauma

Ana Marta^{*}, Ana Carolina Abreu, Sílvia Monteiro, Maria Pinto

Department of Ophthalmology, Centro Hospitalar Universitário do Porto, Largo do Prof. Abel Salazar, 4099-001, Oporto, Portugal

ARTICLE INFO

Keywords:

Cornea
Ectasia
Airbag trauma
Refractive surgery

ABSTRACT

Purpose: To report a case of a temporary corneal ectasia induced by airbag trauma.

Observations: A patient who suffered a road traffic accident with deployment of the frontal airbag and presented a corneal ectasia in both eyes after 3 months, without changes in visual acuity. After 9 months, he presented a significantly improvement, achieving his basal parameters in pentacam.

Conclusions and importance: This is a rare case of corneal ectasia induced by airbag trauma that spontaneously reverted and it can emphasize the viscoelastic properties of the human cornea.

1. Introduction

Automobile air bags reduced the incidence of fatal and severe injuries with the trade-off of increasing the risk of less severe injuries.¹ In relation to ocular involvement, they can cause corneal abrasions, corneal decompensation, corneal alkali injury, hyphema, angle recession, iris sphincter tears, vitreous hemorrhage, macular retinal pigment epithelium disruption, dislocated posterior chamber intraocular lens, and commotio retinae.^{2,3} There are also rare reports of corneal ectasia induced by airbag in patients with⁴ or without⁵ previous refractive surgery, but none with recovery of tomographic parameters, like in our case.

2. Case report

A 36-year-old male was referenced to our hospital for refractive surgery. He was healthy and had no history of familiar ocular pathology. He had never been submitted to previous ocular surgery. Best corrected visual acuity (BCVA) was 20/20 with -2.00 diopters (D) in the right eye (RE) and 20/20 with $-2.25-0.25 \times 30^\circ$ D in the left eye (LE). The anterior segment examination (ASE), the intraocular pressure (IOP) and the ocular funduscopy (OF) were normal. In the first observation, Oculus Pentacam® HR parameters (Fig. 1) were globally normal, without contraindication to refractive surgery. The thinnest point (TP) was within 0.8mm of the apex, with $530 \mu\text{m}$ in the RE, which is normal⁶ and it was within 1.33mm of the apex, with $502 \mu\text{m}$ in the LE, which is more indicative of ectatic cornea. However, the “Ambrósio Relational Thinnest” maximum (ARTmax) was 415 in the RE and 346 in the LE, both

above the cut off $339 \mu\text{m}$ for normal eyes.⁷ The Corneal Thickness Spatial Profile (CTSP) and the Percentage Thickness Increase (PTI) graphs were parallel to the normal lines and the final deviation value D of the Belin/Ambrosio Enhanced Ectasia Display (BAD) was 0.71 in RE and 1.15 in LE, both below the cut off 1.6 for normal eyes.⁸ According to the ABCD keratoconus grading system⁹ (based on anterior and posterior radius of curvature (ARC, PRC), thinnest pachymetry, BCVA and the presence of corneal scarring), the final grade for both eyes would be A0/B0/C0/D0, representing values more typically seen in normal eyes. Due to the lack of refractive stability, a possible contraindication of refractive surgery and in order to monitor possible subclinical changes, another assessment was schedule 6 months later.

In the follow-up visit, the patient reported head/facial trauma in the setting of a road traffic accident with deployment of the frontal airbag, 3 months earlier. He had no visual subjective symptoms. BCVA, refraction and ASE showed no changes. However Oculus Pentacam® HR parameters revealed important anatomic changes, that contraindicated refractive surgery (Fig. 2). An inferior steepening was noted in both eyes, more pronounced in the RE. The TP changed from $530 \mu\text{m}$ to $376 \mu\text{m}$ in the RE and from 502 to $486 \mu\text{m}$ in the LE. K1 and K2 values remained relatively stable. The ARTmax decreased to 127 in the RE and 291 in the LE, lower than 400 which is the safe cut off to surgery.⁶ The CTSP graph had a severe increase from 2mm and PTI graph was out of the range of 95% confidence interval. BAD showed changes in the RE and in the LE on the pachymetric progression (Dp), on the thinnest value (Dt) and on the thinnest displacement (Da). The combination of these were well outside the normal range with a final “D” value clearly in the red zone at 4.93 SD (standard deviation) in the RE and 1.84 SD in the LE.

^{*} Corresponding author.

E-mail address: analuismarta2@gmail.com (A. Marta).

<https://doi.org/10.1016/j.ajoc.2020.100822>

Received 12 November 2019; Received in revised form 18 May 2020; Accepted 4 July 2020

Available online 7 July 2020

2451-9936/© 2020 The Authors.

Published by Elsevier Inc.

This is an open access article under the CC BY-NC-ND license

(<http://creativecommons.org/licenses/by-nc-nd/4.0/>).

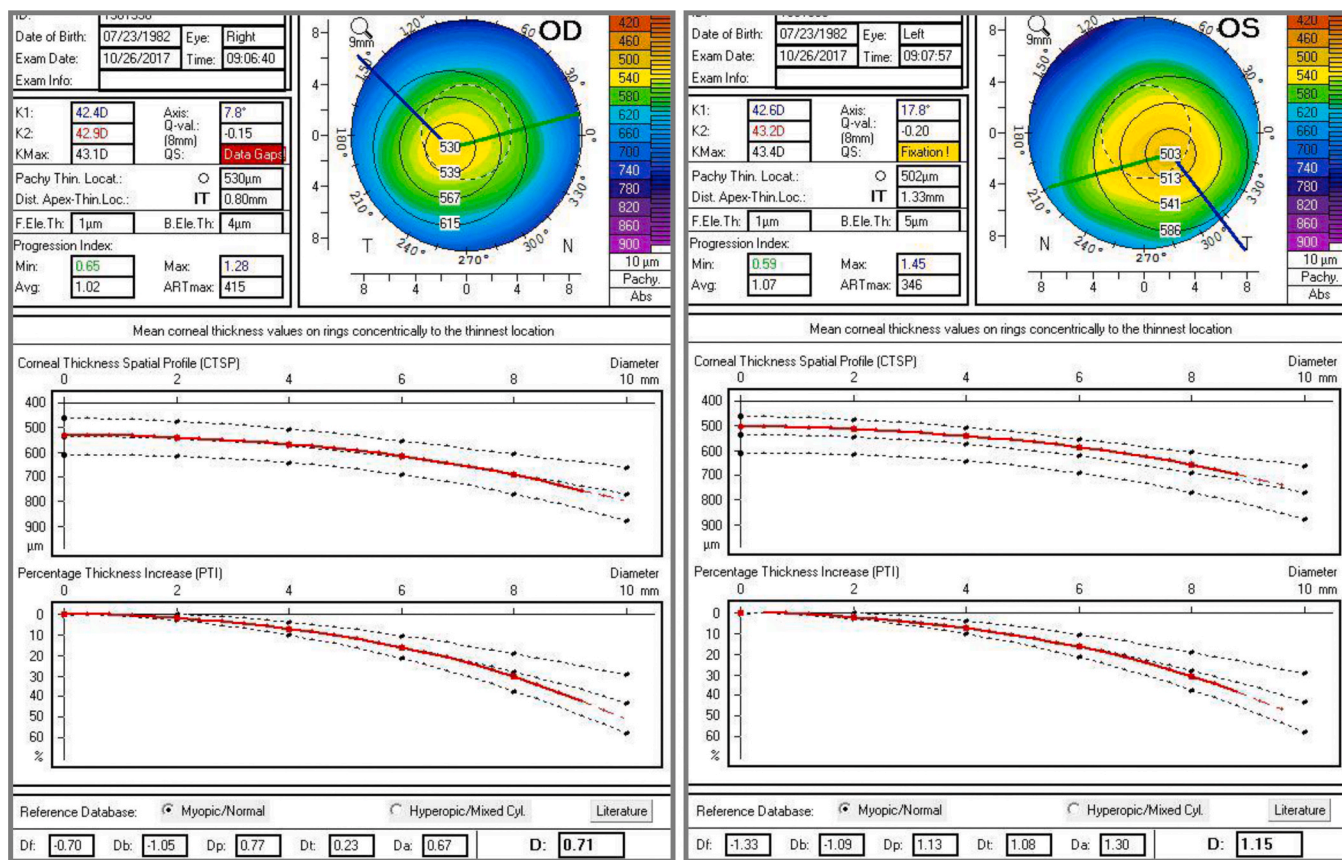


Fig. 1. Belin/Ambrósio Enhanced Ectasia Display of the right eye (left image) and left eye (right image) of the patient at first evaluation.

The topometric indices remained relatively stable, except for the increase of the Index of Height Decentration (IHD) and Index of Height Asymmetry (IHA), in the RE (Table 1). The aberrometric indices also remained relatively stable, except for the increase of the Root Mean Square (RMS) and RMS of Higher Order Aberrations (RMS-HOA), in the RE (Table 1). The patient wasn't prescribed any medication.

At 9 months after the trauma, the patient maintained no visual subjective symptoms, maintaining the same BCVA, refraction and ASE. Surprisingly, we observed a change in the tomographic parameters towards normalization (Fig. 3). On the pachymetric indices, the TP changed from 376µm to 519µm, within 0.63mm of the apex in the RE and from 486 to 515µm, within 0.79mm of the apex in the LE. K1 and K2 remained relatively stable. The ARTmax increased to 461 in the RE and 420 in the LE. The CTSP and the PTI graphs were parallel to the normal lines and the final "D" value also normalized to normal range which is white at 0.39 SD in the RE and 0.81 SD in the LE from the mean.

On the topometric indices, IHD and IHA decreased towards normalization in the RE (Table 1). On the aberrometric indices, RMS-HOA also decrease but RMS-Total continued to increase in the RE (Table 1).

3. Discussion

Literature reports about ocular injuries caused by airbag's trauma, including dislocation flaps or folds in patients with previous refractive surgery and, recently, corneal ectasia development in post-refractive or virgin corneas exists.^{4,5,10} However, the possibility of reversibility of corneal ectasias in this context was never reported.

Our clinical case may be explained by the viscoelastic properties of cornea, which were described by Freidenwald in 1937 and afterwards by Nyquist¹¹ and Woo.¹² In fact, the cornea has some elasticity, the property that allows it to deform reversibly under stress, and some viscosity,

which allows it to slowly deform when external shear force is applied without reversing after the force is removed. These properties allow the cornea to dissipate energy when stress is applied, a process called hysteresis.¹³ However, corneal viscoelastic responses happen in matter of seconds and our patient's recovery time (a period of 9 months) may suggests that the cornea may also have memory properties.

In this clinical case, the external shear forces induced by airbag may have not been enough to cause a permanent corneal ectasia, and the viscoelastic or memory properties may have had a role in the recovery of the corneal parameters. Also it is important to highlight the fact that our patient had not undergone refractive surgery previous to the trauma. The good structural integrity of the cornea may help to explain the recovery seen this case, compared to other cases reported in the literature.

Would this patient have developed ectasia if he had been submitted to laser refractive surgery instead of having suffered airbag trauma? Although at this moment, the patient has good topographic parameters, we have some doubts if this patient had a previous subclinical ectasia before airbag trauma. According to results of Hashemi H. et al¹⁴ in the first observation of our patient, only the TP and ARTmax values of the LE and IHD and keratoconus index (KI) in the RE are clearly in the interval of subclinical keratoconus patients; mean K, "D" value of the BAD, IHA, Central Keratoconus Index (CKI), KI and RMS-HOA of the LE as well as TP, ARTmax, mean K, "D" value, Index of Vertical Asymmetry (IVA), IHA, CKI and RMS-HOA of the RE are simultaneously in intervals of normal and subclinical keratoconus patients. In fact, the detection of subclinical ectasia is a challenge for all ophthalmologists and there are many topographic index and scores with overlap in the intervals of subclinical keratoconus and controls, even using new scores.¹⁵ Despite the limitations, Oculus Pentacam® parameters had an important role in monitoring these subclinical alterations, since the unique alterations in this case were topographic, without BCVA or slit lamp changes in 2nd and 3rd observation, avoiding potential complications of being

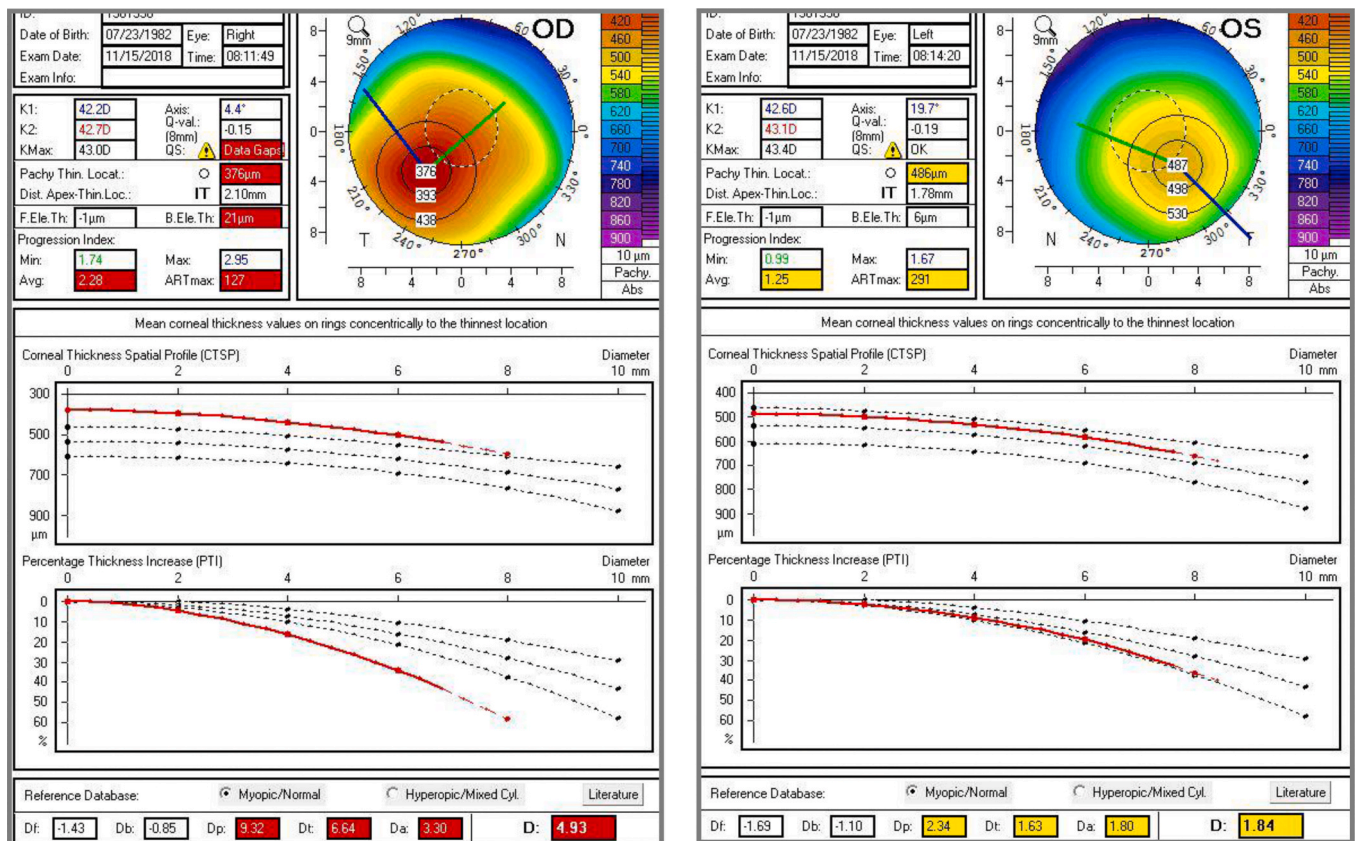


Fig. 2. Belin/Ambrosio Enhanced Ectasia Display of the right eye (left image) and left eye (right image) of the patient 3 months after airbag trauma.

Table 1

Tomographic parameters of the right (RE) and left eye (LE) of the patient before, 3 months and 9 months after airbag trauma.

	Before airbag trauma		3 months after airbag trauma		9 months after airbag trauma	
	RE	LE	RE	LE	RE	LE
Pachymetric indices						
Thinnest Point	530	502	376	486	519	515
RPI avg	1.02	1.07	2.28	1.25	0.94	0.99
RPI max	1.28	1.45	2.95	1.67	1.13	1.23
ART max	415	346	127	291	461	420
BAD-D	0.71	1.15	4.93	1.84	0.39	0.81
Topometric indices						
Index of Height Decentration	0.010	0.003	0.013	0.003	0.010	0.005
Index of Height Asymmetry	1.4	3.0	7.1	3.2	4.7	4.8
Central Keratoconus Index	1.00	1.00	1.00	1.01	1.00	1.00
Minimum sagittal curvature keratoconus index	7.83	7.77	7.86	7.78	7.79	7.78
	1.01	1.00	1.01	1.00	1.02	1.01
Aberrometric indices						
RMS total	0.976	0.771	1.448	0.728	1.773	0.807
RMS-HOA	0.355	0.414	0.686	0.317	0.407	0.322
Others parameters						
ABCD grading system	A0B0C0D0	A0B0C1D0	A0B0C1D0	A0B0C1D0	A0B0C0D0	A0B0C0D0
K mean	42.7	42.9	42.4	42.9	42.7	43.0
Anterior Chamber Depth	3.54	3.45	3.56	3.45	3.54	3.49
Corneal Volume	59.6	56.7	50.8	57.4	57.2	57.2

Abbreviations: RPIavg, average Pachymetric Progression Index; RPImax, maximum Pachymetric Progression Index; ARTmax, maximum Ambrosio Relational Thickness; BAD-D, Belin/Ambrosio enhanced ectasias total deviation value; RMS, Root Mean Square; HOA, Higher Order Aberrations.

submitted to refractive surgery.

Another possible explanation for predominantly pachymetric changes (vs keratometric changes) would be the presence of subtle corneal haze or scarring. This could lead to erroneous measurement of pachymetry by the pentacam and could spontaneously reverse when the corneal haze resolved over a period of time. Anterior segment OCT (AS-OCT) (accurate measurement of pachymetry in the presence of haze)

and densitometry measurements from Oculus Pentacam® (able to measure haze extent, if present) could be useful to evaluate this hypothesis. However, the AS-OCT wasn't performed during follow-up as it is not usually performed for refractive surgery and the densitometry measurement isn't available on the displays of our Oculus Pentacam® machine. Corneal haze or scarring are accompanied by changes on slit lamp observation and in visual acuity, which weren't present in our

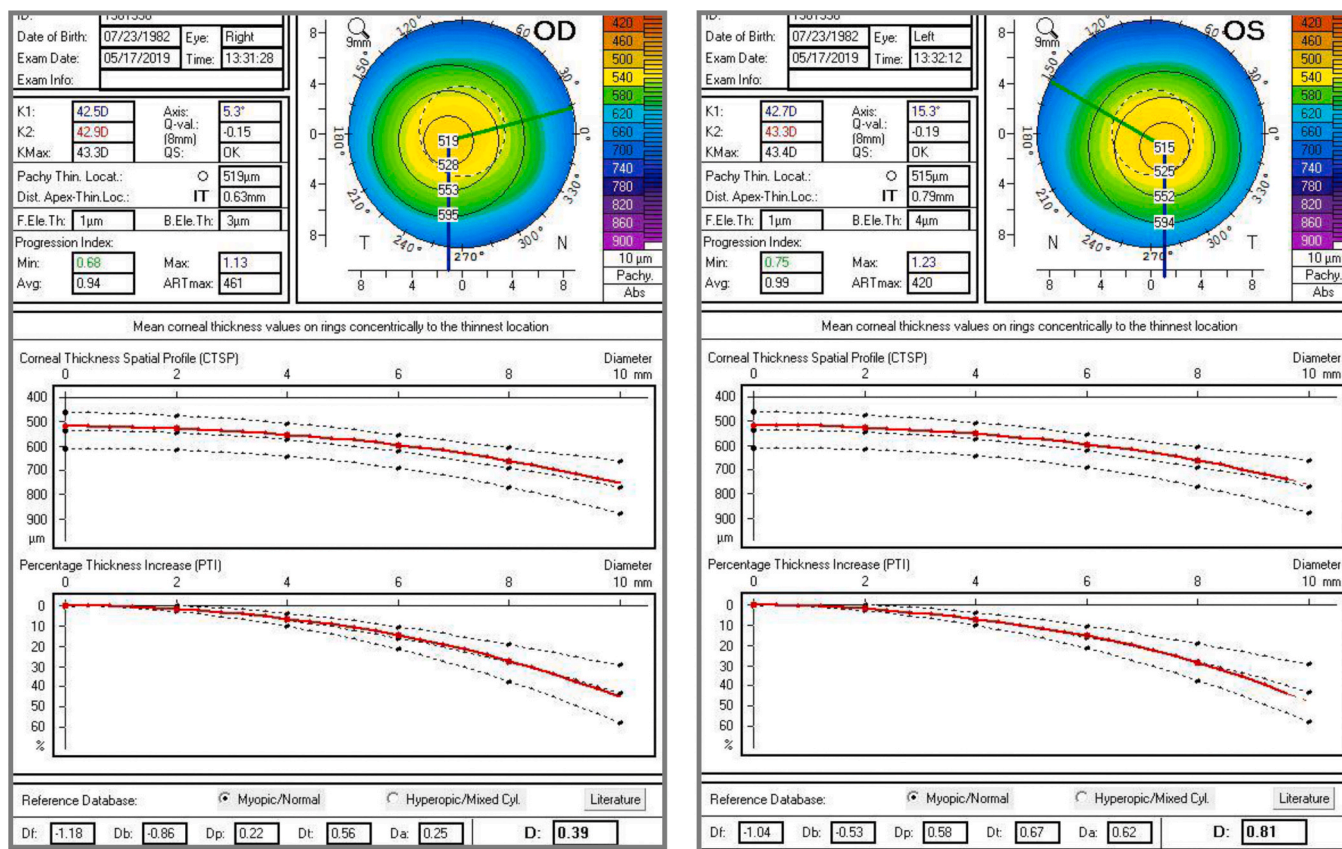


Fig. 3. Belin/Ambrósio Enhanced Ectasia Display of the right eye (left image) and left eye (right image) of the patient 9 months after airbag trauma.

patient.

No evaluation of corneal biomechanical properties was performed in this patient because we don't have equipment in our department. In fact, this is a potential area of development, with some clinical applications in ophthalmology including in glaucoma,¹⁶ myopic eyes,¹⁷ after sclera buckling,¹⁸ after crosslinking,^{19,20} in patients with different degrees of keratoconus²¹ and even in evaluation of the risk of corneal ectasia.²² If this evaluation would have been made in our clinical case before airbag trauma, it could have been useful to evaluate the risk of corneal ectasia. If biomechanical evaluation would have been made after airbag trauma, this could provide values of corneal hysteresis and corneal resistance factor which predict the possibility of recovery. However, we should not forget the possibility of overlap between normal and suspected values, both in biomechanical evaluation²³ as in pentacam parameters. In the future technology may allow for the integration of topographic and biomechanical changes, improving the sensitivity and specificity of these exams in assessing ectasia screening and in the understanding of these cases.

Patient consent

Consent to publish the case report was not obtained. This report does not contain any personal information that could lead to the identification of the patient.

Funding

There was no funding or grant support.

Conflicts of interest

All authors have no financial disclosures.

Authorship

All authors attest that they meet the current ICMJE criteria for Authorship.

Acknowledgements

None.

References

1. Duma SM, Jernigan MV, Stitzel JD, et al. The effect of frontal air bags on eye injury patterns in automobile crashes. *Arch Ophthalmol.* 2002;120(11):1517–1522. <https://doi.org/10.1001/archophth.120.11.1517>.
2. Scarlett A, Gee P. Corneal abrasion and alkali burn secondary to automobile air bag inflation. *Emerg Med J.* 2007;24(10):733–734.
3. Ball DC, Boucharad CS. Ocular morbidity associated with airbag deployment: a report of seven cases and a review of the literature. *Cornea.* 2001;20(2):159–163.
4. Norden RA, Perry HD, Donnenfeld ED, Montoya C. Air bag-induced corneal flap folds after laser in situ keratomileusis. *Am J Ophthalmol.* 2000;130(2):234–235.
5. Lemley HL, Chodosh J, Wolf TC, Bogie CP, Hawkins TC. Partial dislocation of laser in situ keratomileusis flap by air bag injury. *J Refract Surg.* 2000;16(3):373–374.
6. Ambrósio RJR. Simplifying ectasia screening with pentacam corneal tomography. In: *Highlights of ophthalmology journal.* 38. 2010. 3.
7. Ambrósio Jr R, Faria-Correia F, Ramos I, et al. Enhanced screening for ectasia susceptibility among refractive candidates: the role of corneal tomography and biomechanics. *Curr. Ophthalmol. Rep.* 2013;1:28–38.
8. Valbon BF, Santos RT, Ramos I, Canedo AL, Nogueira L, Ambrósio RJR. Simplifying ectasia screening with corneal and anterior segment tomography. *Rev Bras Oftalmol.* 2013;72(1):54–58.
9. Belin MW, Duncan JK. *Keratoconus: the ABCD Grading System.* Klin Monbl Augenheilkd. 233. 2016:701–707, 6.

10. Mearza AA, Koufaki FN, Aslanides IM. Airbag induced corneal ectasia. *Contact Lens Anterior Eye*. 2007;31:38–40.
11. Nyquist Gw. Rheology of the cornea: experimental techniques and results. *Exp Eye Res*. 1968;7(2):183–188.
12. Woo SL, Kobayashi AS, Lawrence C, Schlegel WA. Mathematical model of the corneo-scleral shell as applied to intraocular pressure-volume relations and applanation tonometry. *Ann Biomed Eng*. 1972;1(1):87–98.
13. Deol M, Taylor DA, Radcliffe NM. Corneal hysteresis and its relevance to glaucoma. *Curr Opin Ophthalmol*. 2015;26(2):96–102.
14. Hashemi H, et al. Pentacam top indices for diagnosing subclinical and definite keratoconus. *J. Curr. Ophthalmol*. 2016;28:21–26.
15. Ambrósio RJR, Caiado AL, Guerra FP, et al. Novel pachymetric parameters based on corneal tomography for diagnosing keratoconus. *J Refract Surg*. 2011;27(10):753–758.
16. Chen M, Kueny L, Schwartz AL. The role of corneal hysteresis during the evaluation of patients with possible normal-tension glaucoma. *Clin Ophthalmol*. 2018;12:555–559.
17. Ali Amr, et al. Variations of corneal hysteresis in myopic patients with normal pentacam findings. *Egypt. J. Hosp. Med*. 2018;71(5):3131–3135.
18. Esfahani MR, Jafarzadehpur E, Hashemi H, Ghaffari E. Evaluation of corneal biomechanical properties following scleral buckling using the ocular response analyzer. *Iran. J. Ophthalmol*. 2013;25(2):151–154.
19. Gkika M, Labiris G, Giarmoukakis A, Koutsogianni A, Kozobolis V. Evaluation of corneal hysteresis and corneal resistance factor after corneal cross-linking for keratoconus. *Graefes Arch Clin Exp Ophthalmol*. 2012;250(4):565–573.
20. Murat Uzel Mehmet, Mustafa Koc, Cigdem Can, Sibel Polat, Pelin Yilmazbaş, Dilek Ileri. Effect of accelerated corneal crosslinking on ocular response analyzer waveform-derived parameters in progressive keratoconus [Internet] *Arq Bras Oftalmol*; 2019 Feb:18–24. <https://doi.org/10.5935/0004-2749.20190003> [cited 2019 Aug 24]; 82(1) http://www.scielo.br/scielo.php?script=sci_arttext&pid=S0004-27492019000100018&lng=en. Epub Nov 01, 2018.
21. Martinez-Afanador AM, Ortiz-Nieva G. Hysteresis and corneal resistance factor evaluation in patients with different stages of keratoconus. *Invest Ophthalmol Vis Sci*. 2008;49:4349.
22. Sergienko NM, Shargorodska IV. Evaluation of the risk of corneal ectasia. *New Front Ophthalmol*. 2016;2(1):52–54.
23. Moshirfar M, Edmonds JN, Behunin NL, Christiansen SM. Corneal biomechanics in iatrogenic ectasia and keratoconus: a review of the literature. *Oman J Ophthalmol*. 2013;6:12–17.