

Research Article

Anterior Chamber Flare as an Objective and Quantitative Noninvasive Method for Oculopathy in Transthyretin V30M Amyloidosis Patients

João Beirão ¹, Vasco Miranda,² Beatriz Pinheiro-Torres,³ João Coelho ²,
Maria-João Menéres,² and Pedro Menéres¹

¹Instituto de Ciências Biomédicas Abel Salazar, Universidade do Porto, Porto, Portugal

²Centro Hospitalar Porto, Porto, Portugal

³Alimera Sciences, Alpharetta, USA

Correspondence should be addressed to João Beirão; brandaobeirao@gmail.com

Received 20 January 2018; Accepted 17 August 2018; Published 20 September 2018

Academic Editor: Miguel Rechichi

Copyright © 2018 João Beirão et al. This is an open access article distributed under the Creative Commons Attribution License, which permits unrestricted use, distribution, and reproduction in any medium, provided the original work is properly cited.

Purpose. Assess the aqueous humor flare in transthyretin V30M amyloidosis patients (ATTRV30M). **Materials and Methods.** This is a retrospective, cross-sectional, noninterventional comparative study including 28 ATTRV30M patients with a unilateral scalloped iris. For comparative analysis, the fellow eye, the nonscalloped iris eye, from each patient was used as control. All patients underwent aqueous humor flare meter and intraocular pressure (IOP) measurements. **Results.** Mean aqueous humor flare was significantly higher in the eyes with the scalloped iris than the control group with the nonscalloped iris (14.1 ± 2.2 versus 6.5 ± 0.9 pc/ms, respectively). No significant differences in IOP were found in the scalloped iris eyes than those in the nonscalloped iris control group (17.1 ± 0.8 versus 16.8 ± 0.7 mmHg, respectively). No significant correlation was not found between the flare and the IOP value within groups. **Conclusions.** In this study, aqueous humor flare values in the scalloped iris eyes may be a valid marker for controlling the stage of the oculopathy in ATTRV30M patients.

1. Introduction

Hereditary transthyretin V30M amyloidosis (ATTRV30M) is an autosomal dominant disorder and is a very common form of hereditary amyloidosis caused by extracellular deposition of variants of transthyretin (TTR) in several tissues, including the eye [1, 2]. More than 100 amyloidogenic TTR mutations have been documented [3], but in the Portuguese type, the variant TTR has a substitution of methionine for valine at position 30. Despite the worldwide distribution of the disease, Portugal remains the main geographic focus of amyloidosis TTR V30M [4]. ATTRV30M patients are usually classified as presenting an early onset disease (onset before 50 years of age) or a late-onset disease (onset after 50 years of age). Early onset is associated with a more aggressive, rapidly progressing disease, especially if symptoms appear before 40 years of age [5]. Most Portuguese ATTRV30M patients are early-onset cases, with a worse

prognosis regarding the severity of symptoms and an expected survival of 10 to 15 years without treatment. Liver transplantation is one of the treatments for ATTRV30M amyloidosis as it removes circulating mutant TTR and interrupts the progression of the disease and improve survival and quality of life [6]. Tafamidis, an oral, non-NSAID, highly specific TTR stabilizer has emerged as the new standard of care for ATTRV30M and remains the only medicine approved for the treatment of transthyretin amyloidosis in adult patients with stage 1 symptomatic polyneuropathy [7].

Nevertheless, the intraocular production of TTR V30M by the retinal and ciliary pigment epithelium remains unchanged, contributing to the progression of amyloid deposition-associated ocular manifestations such as abnormal conjunctival vessels, dry eye, scalloped pupils, deposition of amyloid on the anterior surface of the lens and on the pupil border, vitreous amyloidosis, glaucoma, and retinal angiopathy. Moreover, their prevalence increases over time [8].

Glaucoma is an ocular neurodegenerative disease and one of the most common causes of blindness worldwide [9]. It is characterized by retinal ganglion cell degeneration which can lead to optic atrophy and visual field defects [10]. Multiple factors play a role in the etiology and pathology of the disease, being intraocular pressure (IOP) the most important risk factor usually caused by abnormal aqueous humor outflow [11]. Extensive research over the last decade has shown that no amyloid secondary glaucomatous proteomics and oxidative damage can also lead to unfavourable effects on the trabecular meshwork and increased resistance to intraocular aqueous humor drainage [11–19]. Moreover, assessments of the involvement of ATTRV30M in ocular complications showed that glaucoma was strongly associated with the presence of scalloped iris [20]. Still, the nature of the interaction mechanism of iris deformation and aqueous humor flow was not evaluated and is not fully understood yet [8, 21].

However, the presence of scalloped iris before the onset of glaucoma was also observed [20]. Laser flare cell meter is an objective, sensitive, and noninvasive method for evaluating the aqueous flare and allows a quantitative assessment of anterior chamber inflammation and breakdown of the blood-aqueous barrier [22–24]. Several studies have shown altered flare values in glaucomatous eyes and speculated the role of the anterior chamber aqueous flare in predicting the risk of glaucoma [25–30]. Therefore, the aim of this analysis is to assess the blood-aqueous barrier (BAB) function with the use of a laser flare meter in ATTRV30M Portuguese patients with and without scalloped iris.

2. Materials and Methods

This was a retrospective, cross-sectional, noninterventive study conducted at the Ophthalmic Department from Centro Hospitalar do Porto, Porto. Written informed consent was obtained from all patients. This study was performed in accordance with the Declaration of Helsinki of the World Medical Association and was approved by the Ethics Committee of the Centro Hospitalar do Porto.

2.1. Patients. The study included a retrospective cohort of 28 consecutive patients (60.7% men; mean age: 46.5 (35–61) years) examined for ocular abnormalities at the Ophthalmology Service of Centro Hospitalar do Porto. All patients had the ATTR V30M mutation confirmed by genetic analysis and presented unilateral scalloped iris. These patients presented in both eyes no abnormalities in optic nerve and visual field nor ongoing treatment with ocular hypotensive eyedrops and/or previous glaucoma or ocular surgery. The only ocular treatment was artificial tears, and all eyes had best corrected visual acuity of 1.0 (Snellen equivalent). For comparative analysis, the fellow eye, the nonscalloped iris eye, from each patient was used as control. Data collection was from patients' medical records and included demographic data summarized in Table 1.

2.2. Measurement of Blood-Aqueous Barrier Function. To clarify the relationship between IOP increase and the blood-aqueous barrier function in both scalloped iris eyes and

TABLE 1: Demographic and clinical data of ATTRV30M patients.

Characteristics	ATTRV30M patients ($n = 28$)
Age, years	46.9 ± 5.6
Male/female	60.7%/39.3%
Time of ATTRV30M diagnosis, years	14.6 ± 3.9
Liver transplantation, %	96.4%
Time from liver transplantation, years	12.3 ± 3.4
Patients under tafamidis treatment, n	1

nonscalloped iris eyes (control), we measured the IOP values by using Goldmann applanation tonometry and the anterior chamber flare. Flare values were measured quantitatively by laser flare meter (LFM) (Kowa FM-700, Berkshire, UK) without pupil dilatation. On each occasion, 10 readings with a variation of less than 5% were taken. The highest and lowest values were discarded, and the remaining eight were averaged to obtain the flare measurement. Laser flare values were expressed in photon counts/millisecond (pc/ms) and standard deviation (SD) was calculated. Calibration of the laser flare meter was performed according to the manual.

2.3. Statistical Analysis. For continuous variables, such as IOP and anterior chamber flare, the observed values were summarized descriptively (mean ± SD). Student's two-group paired t-test was used to determine the significance of between-group differences in IOP and anterior chamber flare. Association between IOP and flare within each group was analyzed using Pearson's correlation coefficient. Statistical significance was declared at a type 1 error rate of 0.050. Statistical calculations and analyses were performed using SAS for PC, version 9.3 (SAS Inc, Cary, NC).

3. Results

Fifty-six eyes of 28 ATTRV30M patients participated in this analysis. Patients' characteristics are shown in Figure 1 and Table 1. In this study, highly statistical significant differences were found in the disorder in the BAB between the scalloped iris eyes and the nonscalloped iris eyes (control). The aqueous humor flare values in the eyes with a scalloped iris were significantly higher than those in the nonscalloped iris control group ($p < 0.001$), while there were no significant differences in IOP between groups ($p = 0.163$) (Table 2; Figures 2 and 3). There was no significant correlation between the flare and the IOP values within groups (scalloped iris eyes group, Spearman-rho = -0.06 , $p = 0.749$; nonscalloped iris eyes group (control), Spearman-rho = 0.28 , $p = 0.135$).

4. Discussion

The present study demonstrated that the aqueous humor flare values were significantly higher in the ATTRV30M scalloped iris eyes than those in the nonscalloped iris eyes (control group), and the IOP value was not significantly correlated with the increase in flare in both groups.

We previously reported a strong association between glaucoma and scalloped iris and advise to increase the frequency of IOP surveillance and look for glaucoma in these

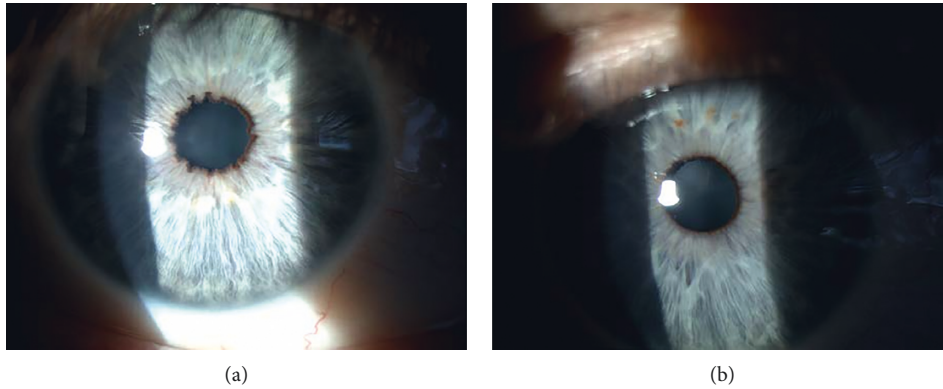


FIGURE 1: ATTRV30M scalloped iris eye (a) and the nonscalloped iris eye (control) (b) same patient.

TABLE 2: IOP and aqueous flare values.

Parameters	Scalloped iris	Nonscalloped iris (control group)	<i>p</i> value
Mean flare (pc/ms)	14.1 ± 2.2	6.5 ± 0.9	<i>p</i> < 0.001
Mean IOP (mmHg)	17.1 ± 0.8	16.8 ± 0.7	<i>p</i> = 0.163

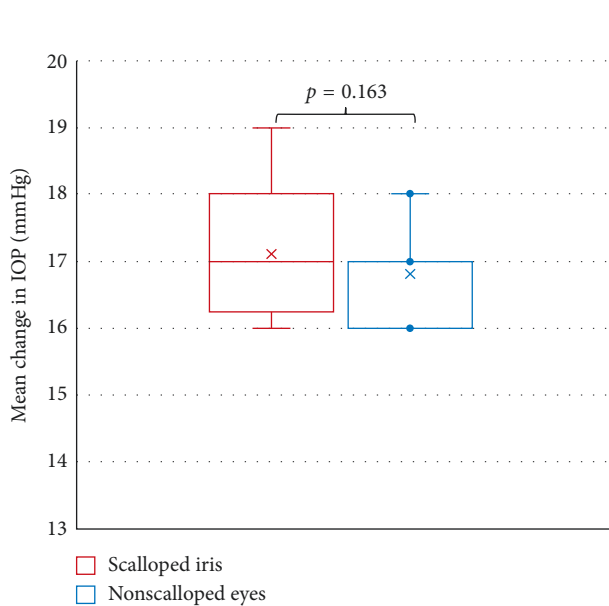


FIGURE 2: IOP distribution of ATTRV30M patients with scalloped iris and nonscalloped iris eyes (control).

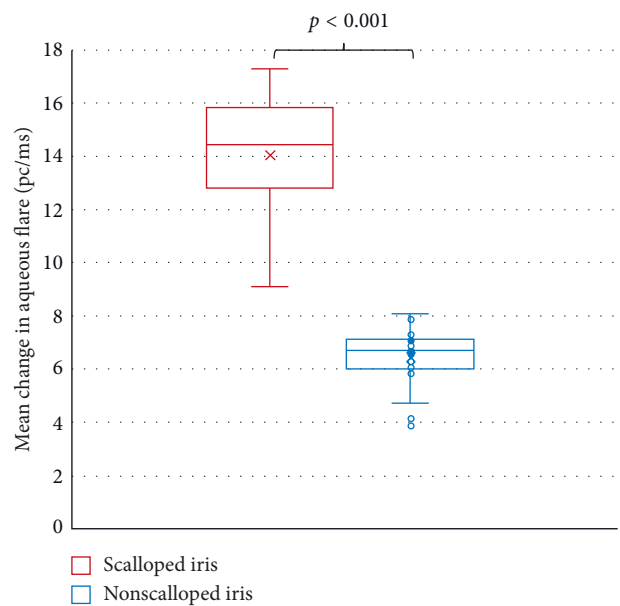


FIGURE 3: Aqueous flare distribution of ATTRV30M patients with scalloped iris and nonscalloped iris eyes (control).

eyes [20, 28]. Nevertheless, our study showed no significant increase in IOP and no increased protein concentration in the aqueous humor in the scalloped iris eyes. These results may suggest the use of the flare meter method for predicting the risk of glaucoma in ATTRV30M scalloped iris eyes.

Several studies have addressed the changes to the aqueous humor proteome in glaucoma using other techniques with collection of aqueous humor samples after and/or during surgery [11, 13–19]. Inoue et al. reported higher levels of cytokines and growth factors in the aqueous humor of open-angle glaucoma eyes using multiplex bead immunoassay [13]. Imbalanced metabolism, lack of reactive oxygen species detoxification, low-grade, and chronic

inflammation in the aqueous humor of open-angle glaucoma eyes were also assessed by several groups by mass spectrometry [15–21].

The laser flare meter is a precise, objective, and non-invasive method that can reliably measure the function of the BAB and the level of inflammation [25, 31]. The increase in aqueous flare echoes a disruption of the BAB, which allows leakage of serum proteins, as well as inflammatory molecules and cells, into the anterior segment by causing a change in aqueous protein composition and concentration [13, 26].

Evaluation of the anterior aqueous flare in patients with glaucoma has also been addressed recently [27–29, 32]. Many groups have assessed the anterior chamber aqueous

flare in glaucomatous eyes after treatment with anti-glaucomatous drugs. Interestingly, Kahloun et al. used the flare meter to evaluate the anterior chamber aqueous flare in patients with pseudoexfoliation syndrome with or without glaucoma and found that a high anterior aqueous flare could be a predictor for the development of glaucoma [27].

In our study, we observed an increased protein concentration in the aqueous humor of ATTRV30M patients with scalloped iris eyes without IOP increased values. An increase in protein concentration in the aqueous is the most straightforward evidence for the breakdown of the BAB [25].

Some authors hypothesize that the breakdown of BAB initially is due to endothelial injury caused by the mutant TTR [33, 34], but there must be another complementary mechanism since patients are transplanted and have no TTR mutant in circulation. The damage should be from outside the vessels where circulates the mutant TTR (aqueous humor and vitreous). As ATTR V30M patients have a proinflammatory state [35], we hypothesize that in response to this stimulation, the ciliary pigmented epithelium may release a large variety of cytokines and fibrin aggregates which may induce the breakdown of the BAB and outflow resistance in the anterior segment of the eye in ATTRV30M patients. As described previously, the intraocular production of TTR V30M by the retinal and ciliary pigment epithelium remains unchanged in these patients [8]. And the total aqueous humor TTR levels are almost the same in liver transplanted and nontransplanted ATTR V30M patients [10]. Thus, we hypothesize that an increased concentration of the unstable TTR V30M in patients' eyes could also contribute to the breakdown of the BAB and increased development of a mechanical barrier to the outflow of the aqueous humor, resulting in IOP elevation and worsening the prognostic for glaucoma development [30].

Therefore, anterior aqueous flare measurements should be considered in the staging and evaluation of the risk progression to glaucoma and be considered as a marker of ocular disease progression in ATTRV30M patients. The flare cell meter may help us to objectify the action of a possible treatment directed to the oculopathy and indirectly targeting the central nervous system [36, 37]. Further, longitudinal studies are warranted to assess the predictive value of aqueous flare for glaucoma development.

This study had some limitations. Further analysis is needed in order to determine which mediators are associated with the breakdown of the BAB function in these ATTRV30M patients. Furthermore, further histological or biochemical analysis to determine whether the source of increased aqueous flare values resulted from the breakdown of the BAB itself or simply from proteins diffusing from the posterior segment caused by the breakdown of the blood-retinal barrier.

5. Conclusions

In this study, we found that the aqueous humor flare value was significantly higher in the scalloped iris eyes than that in the nonscalloped eyes in ATTRV30M patients without significant differences in IOP between groups. As a marker for inflammation, and breakdown of the BAB, flare values suggest that controlling the stage and progression of glaucoma might

be key in the surveillance scalloped iris eyes in ATTRV30M patients and may be considered as an evaluation method of future treatments.

Data Availability

The data used in this study are available with the corresponding author. The access to data is restricted for legal and patient privacy reasons.

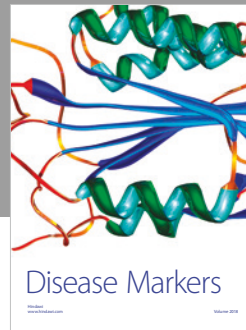

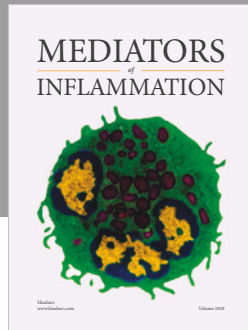
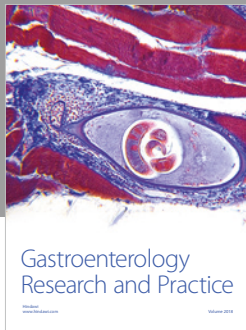
Conflicts of Interest

The authors declare that there are no conflicts of interest.

References

- [1] N. M. Beirão, V. Miranda, I. Beirão et al., "The use of intravitreal ranibizumab to treat neovascular glaucoma because of retinal amyloid angiopathy in familial amyloidosis transthyretin v30m related," *Retinal Cases & Brief Reports*, vol. 7, no. 1, pp. 114–116, 2013.
- [2] A. Rousseau, G. Kaswin, D. Adams et al., "Ocular involvement in familial amyloid polyneuropathy," *Journal Français d'Ophthalmologie*, vol. 36, no. 9, pp. 779–788, 2013.
- [3] L. H. Connors, A. M. Richardson, R. Théberge, and C. E. Costello, "Tabulation of transthyretin (TTR) variants as of 1/1/2000," *Amyloid*, vol. 7, no. 1, pp. 54–69, 2000.
- [4] J. M. Beirão, J. Malheiro, C. Lemos et al., "Impact of liver transplantation on the natural history of oculopathy in Portuguese patients with transthyretin (V30M) amyloidosis," *Amyloid*, vol. 22, no. 1, pp. 31–35, 2015.
- [5] C. Lemos, T. Coelho, M. Alves-Ferreira et al., "Overcoming artefact: anticipation in 284 Portuguese kindreds with familial amyloid polyneuropathy (FAP) ATTRV30M," *Journal of Neurology, Neurosurgery & Psychiatry*, vol. 85, no. 3, pp. 326–330, 2014.
- [6] T. Yamashita, Y. Ando, S. Okamoto et al., "Long-term survival after liver transplantation in patients with familial amyloid polyneuropathy," *Neurology*, vol. 78, no. 9, pp. 637–643, 2012.
- [7] Vyndaqel® Summary of Characteristics, http://www.ema.europa.eu/docs/en_gb/document_library/epar__product_information/human/002294/wc500117862.pdf, October 2017.
- [8] J. M. Beirão, J. Malheiro, C. Lemos, I. Beirão, P. Costa, and P. Torres, "Ophthalmological manifestations in hereditary transthyretin (ATTR V30M) carriers: a review of 513 cases," *Amyloid*, vol. 22, no. 2, pp. 117–122, 2015.
- [9] M. Munar-Qués, L. Salva-Ladaria, P. Mulet-Perera, M. Solé, F. R. López-Andreu, and M. J. M. Saraiva, "Vitreous amyloidosis after liver transplantation in patients with familial amyloid polyneuropathy: ocular synthesis of mutant transthyretin," *Amyloid*, vol. 7, no. 4, pp. 266–269, 2000.
- [10] K. Haraoka, Y. Ando, E. Ando et al., "Presence of variant transthyretin in aqueous humor of a patient with familial amyloidotic polyneuropathy after liver transplantation," *Amyloid*, vol. 9, no. 4, pp. 247–251, 2002.
- [11] H. A. Quigley and A. T. Broman, "The number of people with glaucoma worldwide in 2010 and 2020," *British Journal of Ophthalmology*, vol. 90, no. 3, pp. 262–267, 2006.
- [12] Y. H. Kwon, J. H. Fingert, M. H. Kuehn, and W. L. M. Alward, "Primary open-angle glaucoma," *New England Journal of Medicine*, vol. 360, no. 11, pp. 1113–1124, 2009.
- [13] T. Inoue, T. Kawaji, and H. Tanihara, "Elevated levels of multiple biomarkers of Alzheimer's disease in the aqueous humor of eyes

- with open-angle glaucoma," *Investigative Ophthalmology & Visual Science*, vol. 54, no. 8, pp. 5353–5358, 2013.
- [14] U. Roy Chowdhury, C. R. Hann, W. D. Stamer, and M. P. Fautsch, "Aqueous humor outflow: dynamics and disease," *Investigative Ophthalmology & Visual Science*, vol. 56, no. 5, pp. 2993–3003, 2015.
- [15] M. A. Kaeslin, H. E. Killer, C. A. Fuhrer, N. Zeleny, A. Robert Huber, and A. Neutzner, "Changes to the aqueous humor proteome during glaucoma," *PLoS One*, vol. 11, no. 10, Article ID e0165314, 2016.
- [16] C. Benoist d'Azy, B. Pereira, F. Chiambaretta, and F. Dutheil, "Oxidative and anti-oxidative stress markers in chronic glaucoma: a systematic review and meta-analysis," *PLoS One*, vol. 11, no. 12, Article ID e0166915, 2016.
- [17] E. Ergan, F. Ozturk, E. Beyazyildiz et al., "Oxidant/antioxidant balance in the aqueous humor of patients with glaucoma," *International Journal of Ophthalmology*, vol. 9, no. 2, pp. 249–252, 2016.
- [18] S. Funke, N. Perumal, K. Bell, N. Pfeiffer, and F. H. Grus, "The potential impact of recent insights into proteomic changes associated with glaucoma," *Expert Review of Proteomics*, vol. 14, no. 4, pp. 311–334, 2017.
- [19] J. Cabrerizo, J. A. Urcola, and E. Vecino, "Changes in the lipidomic profile of aqueous humor in open-angle glaucoma," *Journal of Glaucoma*, vol. 26, no. 4, pp. 349–355, 2017.
- [20] A. Goyal, A. Srivastava, R. Sihota, and J. Kaur, "Evaluation of oxidative stress markers in aqueous humor of primary open angle glaucoma and primary angle closure glaucoma patients," *Current Eye Research*, vol. 39, no. 8, pp. 823–829, 2014.
- [21] F. J. Hernández-Martínez, P. Piñas-García, A. V. Lleó-Pérez et al., "Biomarkers of lipid peroxidation in the aqueous humor of primary open-angle glaucoma patients," *Archivos de la Sociedad Española de Oftalmología*, vol. 91, no. 8, pp. 357–362, 2016.
- [22] W. Wang, X. Quian, H. Song, M. Zhang, and Z. Liu, "Fluid and structure coupling analysis of the interaction between aqueous humor and iris," *BioMedical Engineering OnLine*, vol. 15, no. 2, p. 133, 2016.
- [23] M. He, Y. Lu, X. Liu, T. Ye, and P. J. Foster, "Histologic changes of the iris in the development of angle closure in Chinese eyes," *Journal of Glaucoma*, vol. 17, no. 5, pp. 386–392, 2008.
- [24] S. Schröder, P. S. Muether, A. Caramoy et al., "Anterior chamber aqueous flare is a strong predictor for proliferative vitreoretinopathy in patients with rhegmatogenous retinal detachment," *Retina*, vol. 32, no. 1, pp. 38–42, 2012.
- [25] M. Sawa, Y. Tsurimaki, T. Tsuru, and H. Shimizu, "New quantitative method to determine protein concentration and cell number in aqueous in vivo," *Japanese Journal of Ophthalmology*, vol. 32, no. 2, pp. 132–142, 1988.
- [26] M. Sawa, "Clinical application of laser flare-cell meter," *Japanese Journal of Ophthalmology*, vol. 34, no. 3, pp. 346–363, 1990.
- [27] R. Kahloun, S. Attia, I. Ksaa et al., "Anterior chamber aqueous flare, pseudoexfoliation syndrome, and glaucoma," *International Ophthalmology*, vol. 36, no. 5, pp. 671–674, 2016.
- [28] F. Selen, O. Tekeli, and Ö. Yanık, "Assessment of the anterior chamber flare and macular thickness in patients treated with topical antiglaucomatous drugs," *Journal of Ocular Pharmacology and Therapeutics*, vol. 33, no. 3, pp. 170–175, 2017.
- [29] K. Ishida, N. Moroto, K. Murata, and T. Yamamoto, "Effect of glaucoma implant surgery on intraocular pressure reduction, flare count, anterior chamber depth, and corneal endothelium in primary open-angle glaucoma," *Japanese Journal of Ophthalmology*, vol. 61, no. 4, pp. 334–346, 2017.
- [30] M. Cellini, R. Caramazza, D. Bonsanto, B. Bernabini, and E. C. Campos, "Prostaglandin analogs and blood-aqueous barrier integrity: a flare cell meter study," *Ophthalmologica*, vol. 218, no. 5, pp. 312–317, 2004.
- [31] C. Rosenfeld, M. O. Price, X. Lai et al., "Distinctive and pervasive alterations in aqueous humor protein composition following different types of glaucoma surgery," *Molecular Vision*, vol. 21, pp. 911–918, 2015.
- [32] E. Strobbe, M. Cellini, M. Fresina, and E. C. Campos, "ET-1 plasma levels, aqueous flare, and choroidal thickness in patients with retinitis pigmentosa," *Journal of Ophthalmology*, vol. 2015, Article ID 292615, 6 pages, 2015.
- [33] H. Koike, S. Ikeda, M. Takahashi et al., "Schwann cell and endothelial cell damage in transthyretin familial amyloid polyneuropathy," *Neurology*, vol. 87, no. 21, pp. 2220–2229, 2016.
- [34] A. Rousseau, C. Terrada, S. Touhami et al., "Angiographic signatures of the predominant form of familial transthyretin amyloidosis (Val30Met mutation)," *American Journal of Ophthalmology*, vol. 192, pp. 169–177, 2018.
- [35] M. L. Fiszman, M. Di Egidio, K. C. Ricart et al., "Evidence of oxidative stress in familial amyloidotic polyneuropathy type 1," *Archives of Neurology*, vol. 60, no. 4, pp. 593–597, 2003.
- [36] A. C. Silva-Araújo, M. A. Tavares, J. S. Cotta, and J. F. Castro-Correia, "Aqueous outflow system in familial amyloidotic polyneuropathy, Portuguese type," *Graefe's Archive for Clinical and Experimental Ophthalmology*, vol. 231, no. 3, pp. 131–135, 1993.
- [37] L. F. Maia, R. Magalhães, J. Freitas et al., "CNS involvement in V30M transthyretin amyloidosis: clinical, neuropathological and biochemical findings," *Journal of Neurology, Neurosurgery & Psychiatry*, vol. 86, no. 2, pp. 159–167, 2015.



Hindawi

Submit your manuscripts at
www.hindawi.com

