

Enzymatic vitreolysis for the treatment of tractional diabetic macular edema

Bernardete Pessoa , João Coelho , Constança Coelho , Sílvia Monteiro, Carolina Abreu, João Figueira, Angelina Meireles and João Nuno Melo Beirão

Ther Adv Ophthalmol

2019, Vol. 11: 1–10

DOI: 10.1177/
2515841419869511

© The Author(s), 2019.
Article reuse guidelines:
sagepub.com/journals-
permissions

Abstract

Background: A new approach to address focal vitreomacular adhesion in patients with diabetic macular edema may control and stabilize diabetic macular edema with fewer anti-vascular endothelial growth factor injections.

Objectives: The aim of this study was to demonstrate that diabetic macular edema can be improved by inducing the release of a vitreomacular adhesion, with less than 2500 μm , with enzymatic vitreolysis.

Methods: From a retrospective analysis of clinical records from patients with diabetic retinopathy, patients with diabetic macular edema and vitreomacular adhesion $<2500 \mu\text{m}$ were selected for a single-arm prospective study. The primary endpoint was to control diabetic macular edema with fewer anti-vascular endothelial growth factor injections after an observed vitreomacular adhesion release. A statistical subanalysis was performed for the following two groups: the group with vitreomacular adhesion release (group 1) and the group without vitreomacular adhesion release (group 2).

Results: A total of 23 eyes from 19 patients were included. A reduction of the median number of injections was achieved in group 1 ($p = 0.006$). Adverse events were mild and transitory.

Conclusion: Release of vitreomacular adhesion $<2500 \mu\text{m}$ through enzymatic vitreolysis contributed to the control and stabilization of diabetic macular edema with fewer anti-vascular endothelial growth factor injections, reducing the burden and the risks related to these invasive and frequently chronic treatments.

Keywords: anti-vascular endothelial growth factor injections, diabetic macular edema, ocriplasmin, vitreolysis, vitreomacular traction

Received: 27 December 2018; revised manuscript accepted: 22 July 2019.

Introduction

The pathogenesis of diabetic macular edema (DME) is multifactorial and not fully understood.^{1–3} Many reports correlate the posterior cortical vitreous interaction with the macula with DME development.^{3–7} Furthermore, some authors have highlighted that the presence of posterior vitreous detachment (PVD) has a positive effect on the evolution of DME.^{1,4–8}

Schulze and colleagues⁹ suggested that vitreomacular adhesion/traction (VMA) induces a cut-off from blood supply in the macula, leading to ischemia-induced vascular endothelial growth

factor (VEGF) release. Moreover, VMA is regarded as a risk factor for proliferative-type complications such as proliferative vitreoretinopathy and epiretinal gliosis.¹⁰ These macular proliferations may induce additional edema which further impairs vision.¹¹ Taken together, these tractional mechanic factors may antagonize the effect of anti-VEGF or corticosteroid intravitreal (IV) injections and may be the lead causing factors for pharmacological resistance in patients with macular edema.¹²

Until recently, the only treatment option available for VMA was vitrectomy. Given its risks, the

Correspondence to:
Bernardete Pessoa
Departamento de
Oftalmologia, Hospital
de Santo António, Centro
Hospitalar Universitário
do Porto, Largo Prof.
Abel Salazar—Edifício
Neoclássico, Porto 4099-
001, Portugal.
bbtpessoa@gmail.com

Bernardete Pessoa
Angelina Meireles
João Nuno Melo Beirão
Departamento de
Oftalmologia, Hospital
de Santo António, Centro
Hospitalar Universitário
do Porto, Porto, Portugal;
Instituto de Ciências
Biomédicas Abel Salazar,
Universidade do Porto,
Porto, Portugal

João Coelho
Departamento de
Oftalmologia, Hospital
de Santo António, Centro
Hospitalar Universitário
do Porto, Porto, Portugal;
Department of Surgery
and Physiology, Faculty
of Medicine, University of
Porto, Porto, Portugal

Constança Coelho
Genetics Laboratory,
Institute of Environmental
Health, Lisbon Medical
School, University of
Lisbon, Lisbon, Portugal

Sílvia Monteiro
Carolina Abreu
Departamento de
Oftalmologia, Hospital
de Santo António, Centro
Hospitalar Universitário do
Porto, Porto, Portugal

João Figueira
Centro Hospitalar e
Universitário de Coimbra,
Coimbra, Portugal; Faculty
of Medicine, University
of Coimbra, Coimbra,
Portugal; Association for
Innovation and Biomedical
Research on Light and
Image, Coimbra, Portugal

standard of care has generally been conservative until visual symptoms from VMA have deteriorated sufficiently to justify surgical intervention. Furthermore, post-vitreotomy DME is considered more difficult to treat with IV therapy, as those eyes eliminate drugs more quickly than nonvitreotomized eyes, usually needing a higher number of injections during the first 12 months of treatment.^{13–16}

Ocriplasmin has been reported to be efficient in improving different types of macular edema through VMA release, total PVD, and increase in oxygen concentration in the vitreous cavity.^{4,7,17–19} In this study, we report the results of ocriplasmin treatment in patients with DME and a VMA with less than 2500 μm , with the purpose to induce a VMA release and better DME control.

Materials and methods

Study design

From a retrospective analysis of 1484 clinical records from patients with diabetic retinopathy, 23 eyes from 19 patients with DME and VMA with less than 2500 μm were selected for a prospective single center study, conducted at the Department of Ophthalmology, Hospital de Santo António—Centro Hospitalar do Porto (HSA-CHP), Portugal, between July 2016 and July 2017. This study was divided into two phases: a retrospective pre-vitreolysis phase, in which patients received anti-VEGF injections for DME in a *pro re nata* (PRN) regimen and were followed-up for 26 weeks, and a second prospective phase, after administering the ocriplasmin injection, in which patients were also treated with anti-VEGF, if needed, and followed-up for 24 weeks, with a 1 month possible interval between ocriplasmin injection and the next anti-VEGF IV, if needed.

Inclusion and exclusion criteria

Patients aged ≥ 18 years with type 1 or 2 diabetes and DME were eligible if their best-corrected visual acuity (BCVA) was between 20 and 80 Early Treatment Diabetic Retinopathy Study (ETDRS) letters and met the following inclusion criteria: (1) DME with central subfield foveal thickness (CSFT) of at least 300 μm , with a VMA less than 2500 μm in length within the 6-mm central retinal field using spectral domain optical coherence tomography (SD-OCT, Spectralis HRA+OCT, version 1.10.2.0; Heidelberg Engineering, Heidelberg,

Germany) and (2) ability to provide written informed consent. Patients were excluded if they had the following: (1) evidence of epiretinal membrane (ERM) on optical coherence tomography (OCT); (2) history of other retinal vascular diseases; (3) previous vitrectomy; (4) undergone intraocular surgery in the previous 6 months, namely, phacoemulsification, retinal photocoagulation, or YAG LASER capsulotomy; (5) history of IV corticosteroid therapy; (6) suffered vitreous hemorrhage or other opacifications which can conceal fundus visualization and OCT measurements; (7) proliferative diabetic retinopathy (PDR); (8) active ocular inflammation or infection in either eye; (9) uncontrolled glaucoma in either eye [intraocular pressure (IOP) > 24 mmHg with treatment]; (10) history of stroke in the previous 6 months; (11) uncontrolled arterial hypertension (systolic blood pressure > 160 mmHg or diastolic blood pressure > 100 mmHg); or (12) be a ward of the state.

The study was conducted according to the tenets of the Declaration of Helsinki in its latest amendment (Brazil, 2013) and was approved by the ethics committee of HSA-CHP [2017.093 (084-DEFI/082-CES)]. All patients signed an informed consent form.

Patient assessment

Baseline demographics and glycemic control (HbA1c) data as well as history of previous ocular treatments were collected. Each patient had a complete ophthalmological evaluation, along with a papillary and macular OCT to assess the status of posterior vitreous cortex, VMA, DME, and PVD, conducted at baseline, on the day of the ocriplasmin injection, on day 4 after the ocriplasmin injection and then monthly until the end of follow-up. Maintenance of vitreous adhesion on the papillary area was considered a non-PVD achievement. In cases of doubt of the vitreous adhesion, an ocular ultrasonography (Eye Cubed™, Ellex, version 2.5.0.1) was performed with a 10-MHz sealed B-Scan probe. PVD was considered complete when the posterior vitreous cortex was well defined and completely separated from the retina situated posterior to the equator. Fluorescein angiography was performed on all patients at baseline.

During the follow-up period the following two phases were considered: 26 weeks before and 24 weeks after ocriplasmin treatment.

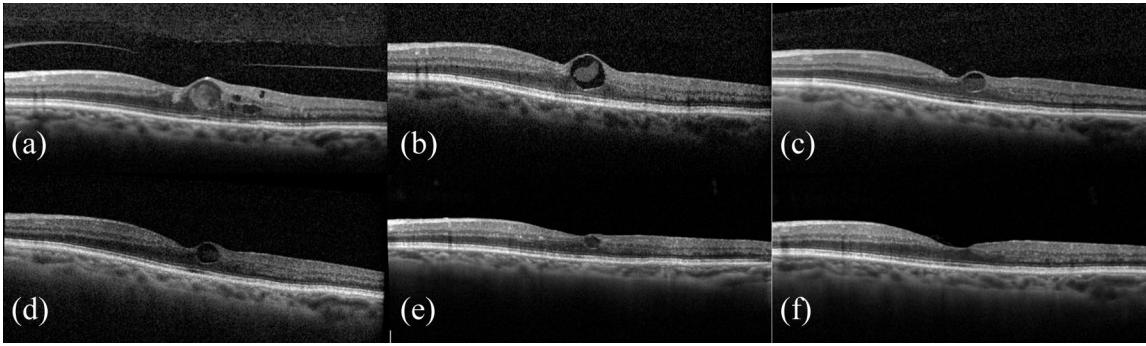


Figure 1. Spectral-domain optical coherence tomography macular images of one case with a central focal edema, a VMA and a CSFT between 300 and 350 μm . The images are from a 71-year old female patient, phakic, with a DME and a focal VMA with at least 16 months of duration, treated only with LASER therapy and no intravitreal injections. (a) immediately pre-ocriplasmin—OCT image with a CSFT of 350 μm and a BCVA of 7/10; (b–e) day 4, month 1, 3, and 6 post ocriplasmin, respectively, with a progressively normalization of the macular anatomy. At month 6 of follow-up (e and f) the patient had a BCVA of 20/20, 85 ETDRS letters, and a CSFT of 295 μm . The release of VMA was documented at the day 4 after ocriplasmin.

SD-OCT acquisition

A highly trained technician conducted SD-OCT scans. The acquisition infrared (IR) 30° + OCT 20° was applied. The circle scan OCT mode, for vitreous-optic disk adhesion analyses, and dense line scan OCT mode, for macula and posterior pole, were used. The follow-up function and auto-rescan with active eye tracking were also utilized. SD-OCT images were classified according to presence and length of VMA, CSFT, detachment of neurosensory retina, and integrity of the ellipsoid zone. CSFT was obtained automatically from equipment readings. The longer VMA length was measured using the macular scan, by two experienced medical retinal specialists, B.P. and J.N.M.B., and the mean value of these measurements considered. The presence of VMA was also evaluated by the same doctors and incongruent cases assessed by a third senior medical retinal specialist, A.M.

Treatment protocol

All patients were monitored with SD-OCT scan. Patients with DME and CSFT > 350 received anti-VEGF treatment. If CSFT was above 350 μm , anti-VEGF treatment was performed in a PRN regimen, with at least a 1 month interval (Figure 1). The choice of anti-VEGF treatment drug (ranibizumab or aflibercept), when required, was dependent on the previously administered anti-VEGF. The same anti-VEGF option was maintained during the follow-up period. LASER or steroid treatments were not allowed during the follow-up period. The same anti-VEGF protocol

treatment was applied for the retrospective phase, when DME and VMA with less than 2500 μm coexisted.

Patients with persistent VMA in the pre-ocriplasmin phase were treated with an IV injection of 125 $\mu\text{g}/0.1$ ml of ocriplasmin (Jetrea; ThromboGenics, Inc., Iselin, New Jersey, US; Alcon/Novartis Farma, Porto Salvo, Portugal) on week 26, 2 weeks after administering the IV anti-VEGF if that had been the case. Anti-VEGF injections were counted from 26 weeks previously to ocriplasmin because the last anti-VEGF injection was performed, if needed, 2 weeks before ocriplasmin. The 24-week period after ocriplasmin is sufficient to include the same maximum potential number of anti-VEGF injections (six). All injections were performed in the operating room following standard protocol: injection through *pars plana* (3.5 or 4.0 mm from the limbus for pseudophakic and phakic patients, respectively), under sterile conditions.

Study endpoints

The primary endpoint was to determine the number of anti-VEGF injections to control DME after the ocriplasmin injection, comparing eyes that exhibited VMA release with eyes with persistent VMA. Secondary endpoints included the following: (1) the percentage of eyes with spontaneous nonsurgical resolution of VMA during follow-up, (2) BCVA and CSFT changes after ocriplasmin injection, (3) achievement of PVD, and (4) safety. An increase of ≥ 5 letters was considered to be a clinical significant increase.

Table 1. Baseline characteristics of the study population.

Parameter	Study population	Group 1	Group 2	<i>p</i> value
Age, years	68.0 (59.0–75.00; 8.1)	70.7 (58.9–75.0; 8.4)	66.9 (60.6–72.6; 6.7)	0.089
Age > 65 years, eyes <i>n</i> (%)	18 (75.0)	11 (78.6)	7 (77.9)	0.964
Males; eyes <i>n</i> (%)	15 (65.2)	9 (64.3)	6 (66.7)	0.906
High blood pressure; eyes <i>n</i> (%)	19 (82.6)	12 (85.7)	7 (77.8)	0.624
Phakic; eyes <i>n</i> (%)	14 (60.9)	9 (64.3)	5 (55.6)	0.675
Laser therapy (peripheral and macular)	23 (100)	14 (100)	9 (100)	1.000
Macular LASER	21 (91.3)	12 (85.7)	9 (100)	0.668
Peripheral LASER	22 (95.7)	13 (92.9)	9 (100)	0.820
HbA1c (%)	7.4 (6.5–10.0; 1.5)	7.0 (6.5–10.0; 0.7)	8.1 (6.7–9.1; 1.8)	0.032
Duration of DME (months)	22.0 (5.7–68.9; 13.6)	19.5 (5.7–68.9; 19.4)	28.3 (12.3–59.0; 19.7)	0.369
Duration of VMA (months)	5.0 (1.0–16.0; 6.0)	5.5 (1.0–15.0; 7.8)	3.8 (1.8–16.0; 5.5)	0.643
VMA length (μm)	425 (128–2115; 528)	417 (128–2115; 428)	582 (324–1820; 1002)	0.680
Eyes with focal VMA (<1500 μm), <i>n</i>	20	7	13	0.538
Baseline BCVA (letters)	65.0 (40.0–80.0; 10.0)	67.5 (60.0–80.0; 9.0)	65.0 (40.0–83.0; 15.0)	0.926
CSFT (μm)	326.0 (199.0–416.0; 67.0)	322.5 (199.0–416.0; 43.0)	328.0 (206.0–400.0; 105.0)	0.829

BCVA, best-corrected visual acuity; CSFT, central subfield foveal thickness; DME, diabetic macular edema; IQR, interquartile range; VMA, vitreomacular adhesion.

Group 1—with VMA release; group 2—without VMA release. Values are presented as median (range, IQR). Baseline defined as the day of ocriplasmin injection (pre-injection). BCVA in ETDRS letters; CSFT at ocriplasmin injection day. *p* value pertains to the comparison between groups. All significant values are represented in bold.

Statistical analysis

After testing for the normality of all variables using the Shapiro–Wilk test, nonparametric statistics methods were used. Changes in BCVA, CSFT, VMA length, number of IV injections, and glycemic control in the overall sample over time were evaluated with a Wilcoxon test for paired samples. A statistical subanalysis was performed for two groups, group 1 with VMA release and group 2 without VMA release. The Mann–Whitney test was used for comparisons between patients with and without VMA release. The χ^2 test was used for comparison of proportions. Values are presented as median (range, interquartile range) unless otherwise specified. Data analyses were performed using SPSS 23th edition (IBM Corporation, Armonk, New York, US). Tests were considered significant at $\alpha < 0.05$ significance level (two-sided).

Results

Demographic and baseline data

No cases initially enrolled in the study were excluded during the study period. Before inclusion in the prospective study 18 eyes (78.3%) had received IV anti-VEGF. The remaining demographic and baseline data are summarized in Table 1.

Primary endpoint

From a total of 23 eyes, 17 received a median of 3 injections (1–6, 2) in the pre-ocriplasmin phase and a median of 2 injections (0–6, 3.5) post-ocriplasmin ($p = 0.005$). The remaining six eyes did not receive anti-VEGF treatment because CSFT was successfully maintained below 350 μm, during the entire follow-up period. The median

Table 2. Median number of anti-VEGF injections, pre- and post-ocriplasmin, between and within groups.

	All patients	Group 1	Group 2	<i>p</i> value
Number of intravitreal anti-VEGF in the pre-ocriplasmin phase	3.0 (1.0–6.0; 2.0)	3.0 (1.0–6.0; 1.5)	4.0 (1.0–6.0; 3.5)	0.376
Number of intravitreal anti-VEGF in the post-ocriplasmin phase	2.0 (0.0–6.0; 3.5)	1.0 (0.0–5.0; 2.5)	4.0 (1.0–6.0; 2.75)	0.022
<i>p</i> value	0.005	0.006	0.564	

IQR, interquartile range; IV, intravitreal; VEGF, vascular endothelial growth factor; VMA, vitreomacular adhesion. Group 1—with VMA release; group 2—without VMA release. Values are presented as median [range, IQR]. For these analyses, only the 17 eyes that needed IV injections of anti-VEGF in pre-ocriplasmin phase were considered. *p* value on the right column refers to comparison between groups 1 and 2 in pre- and post-ocriplasmin phase, respectively. Statistically significant values are represented in bold.

number of anti-VEGF injections, pre- and post-ocriplasmin, between and within groups is summarized in Table 2. The number of anti-VEGF injections was significantly higher before VMA release, with a median of three injections (1–6, 1.5), than after VMA release, with a median of one injection (0–5; 2.5), $p = 0.006$.

Secondary endpoints

The overall VMA resolution rate was 60.9% ($n = 14$). VMA resolution was achieved in 50% of the eyes between the first and fourth day following the ocriplasmin injection, in 21.4% between day 4 and the first month, and in 28.6% after the first month of follow-up. VMA resolution was observed in one of the three broad adhesion VMA cases ($\geq 1500 \mu\text{m}$; Figure 2).²⁰

In the six eyes with no indication for treatment with anti-VEGF previous to the ocriplasmin injection, five exhibited VMA release with resolution of the focal macular edema (Figure 1 exemplifies one of those cases), and the eye without VMA release maintained DME with less than 350 μm during the entire follow-up period.

In both groups, BCVA was clinically and statistically higher at the end of follow-up, having increased in group 1 ($p = 0.012$) from a median of 67.5 (60.0–80.0; 9.0) to 76.0 ETDRS letters (60.0–85.0; 14.0) and in group 2 ($p = 0.038$) from a median of 65.0 (40.0–83.0; 15.0) to 76.0 ETDRS letters (53.0–85.0; 17.0; Figure 3).

In the last visit, 8.7% of the eyes lost 5–10 ETDRS letters with no statistical differences between groups (7.1% in group 1 and 11.1% in group 2, $p > 0.05$). None of the eyes lost more than 10 ETDRS letters. With regard to CSFT, there were

no differences between groups at any time point ($p > 0.05$; Figure 4). The number and percentage of patients who needed injections at each time point (1, 2, 3, 4, 5, and 6 months, respectively) was: group 1—4 (28.6%), 2 (14.3%), 1 (7.1%), 3 (21.4%), 2 (14.3%), and 3 (21.4%); group 2—7 (77.8%), 6 (66.7%), 7 (77.8%), 5 (55.6%), 4 (44.4%), and 1 (11.1%).

Complete PVD was achieved in 50% of the eyes in group 1, with no statistically significant differences in the number of IV injections between patients with and without complete PVD.

With respect to glycemic control, HbA1c was not statistically significant different within groups during the follow-up period (median of 7.0% at baseline and at end of follow-up in group 1, $p = 0.310$, and 8.1% at baseline and 7.8% at the end of follow-up in group 2, $p = 0.684$). Comparing group 1 with group 2, HbA1c was statistically significant inferior in group 1 both at baseline ($p = 0.032$) and at the end of follow-up ($p = 0.009$).

There were no statistically significant differences between groups regarding the remaining baseline characteristics ($p > 0.05$).

Safety

The adverse events reported (mild visual acuity decrease in 21.7% of the patients, pain or discomfort in 26.1%, floaters in 26.1%, and photopsias in 8.7%) were transitory, well tolerated, and none was present or reported beyond the first follow-up visit. No changes in the ellipsoid layer or the occurrence of a neurosensory retinal detachment¹⁷ were observed. No suspected unexpected serious adverse reactions (SUSARS) were

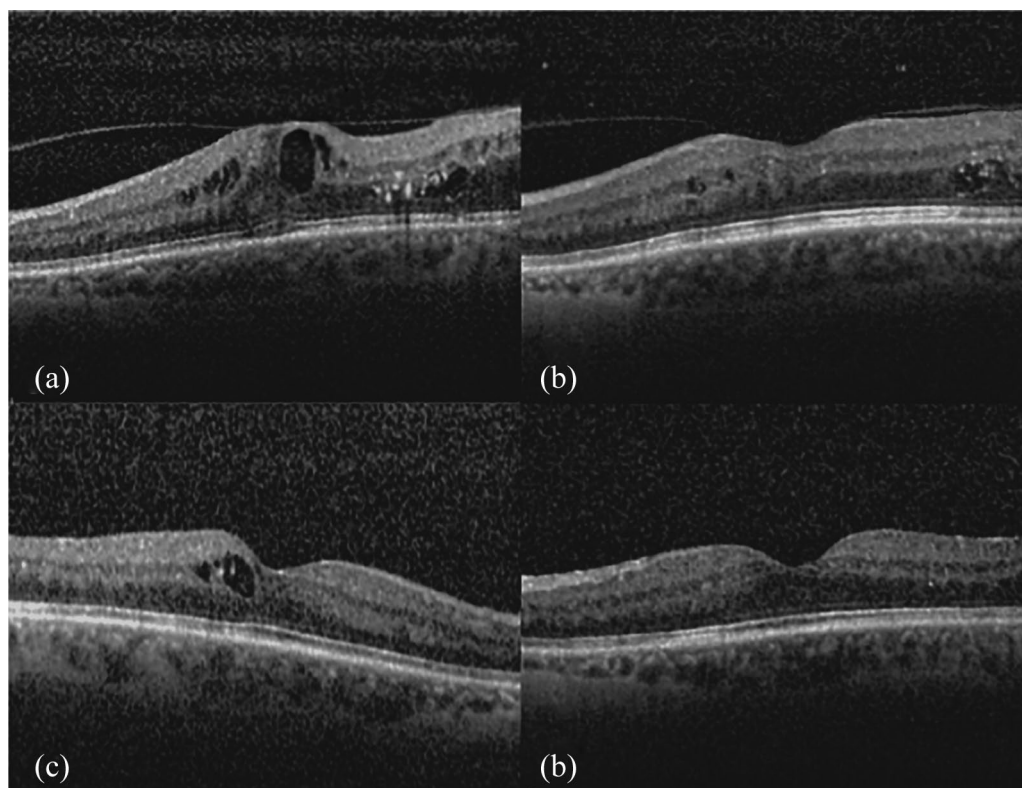


Figure 2. Spectral-domain optical coherence tomography images of a 71-year old phakic male patient with DME and a broad VMA adhesion. (a) DME status after LASER therapy and out of the window effect of multiple anti-VEGF intravitreal injections (CSFT of 559 μm). (b) Pre-ocriplasmin injection condition, 15 days after an anti-VEGF injection (CSFT of 382 μm). (c) VMA resolution 1 day after ocriplasmin injection. (d) Six months later the patient had a BCVA of 20/20, 85 ETDRS letters, and a CSFT of 310 μm . There was no need for further additional treatment during the follow-up period, with a stable macular anatomy since the first month post ocriplasmin.

observed regarding drugs and procedures applied in this study.

Discussion

DME, even when VMA is present, may recede with different therapeutic measures (metabolic control, LASER therapy, and anti-VEGF or corticosteroid IV injections). However, it is believed that the response to these measures might be less efficient and last less time when a VMA is present.

The Food and Drug Administration (FDA) approved ocriplasmin in 2012 and the European Medicines Agency (EMA) in 2013 for the treatment of symptomatic VMA. As inflammatory, sometimes ischemic and fibrovascular proliferation stimuli underlie diabetic retinopathy disease, these eyes are particularly at risk of experiencing cellular migration, taut posterior hyaloid, ERMs'

formation, and vitreomacular traction, which can also be promoted by the laser retinal treatments;^{11,20,21} it would be expected that the effect of ocriplasmin, in this particular patient subgroup, would be less efficient. However, in this study, VMA resolution was achieved in a relatively high percentage of patients (60.9%), compared with other series which reported rates from 26.5% to 64% mainly in nondiabetic patients.^{10,22} Positively skewing our results may be the exclusion of patients with ERMs, known to be a negative prognostic factor for the efficacy of ocriplasmin.²³ Nonetheless, our sample has some possible negative prognostic factors, such as the percentage of previous LASER therapy (100%) and broad adhesions (13%).^{20,23}

Reflecting on other possible determining factors, there were no statistically significant differences in baseline characteristics (phakic status, age, gender, type of DR, history of hypertension,

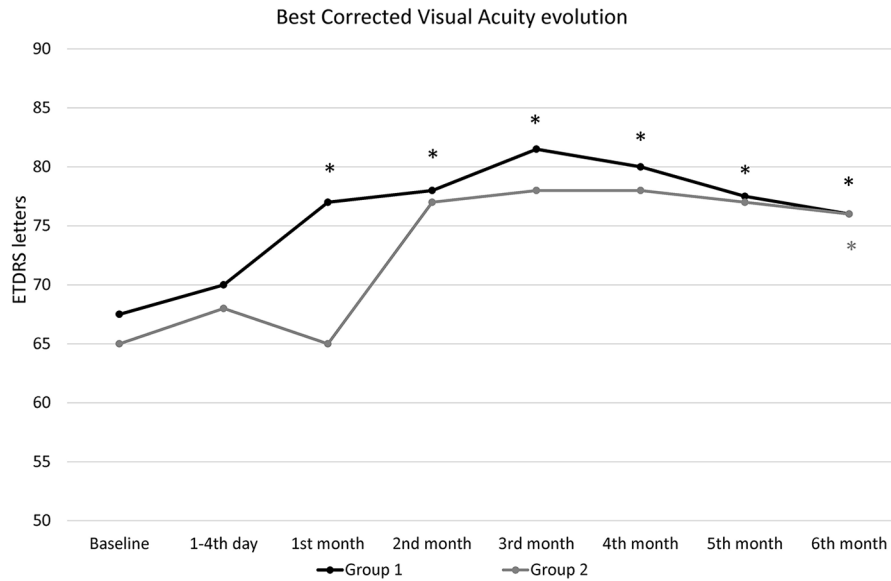


Figure 3. Best-corrected visual acuity (BCVA) evolution in ETDRS letters after ocriplasmin injection. Group 1—with VMA release; group 2—without VMA release. Values are presented as median. There were no differences between groups at any time point ($p > 0.05$).
* $p < 0.05$ within groups compared with baseline.

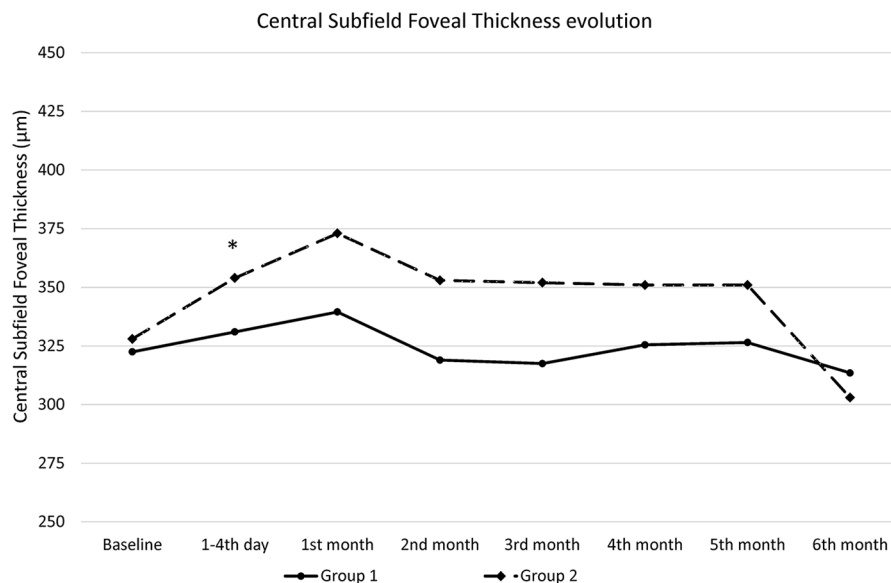


Figure 4. Central subfield foveal thickness (CSFT) evolution after ocriplasmin injection. Group 1—with VMA release; group 2—without VMA release. Values are presented as median. There were no differences between groups at any time point ($p > 0.05$).
* $p < 0.05$ within groups compared with baseline.

duration of DME, duration and length of VMA, BCVA, and CSFT) between the two groups analyzed (with and without VMA release). HbA1c levels were statistically significantly lower in group 1 compared with group 2, both at baseline and at the end of follow-up.^{21,22} However, HbA1c

levels do not correspond robustly to anti-VEGF treatment effects in the eye, and neither the absolute benefit nor the prognosis is associated with HbA1c levels.²¹ Future studies are required to prove that HbA1c level is not relevant for the VMA release process.

The VMA resolution occurred in the majority of the patients until the first month after ocriplasmin, which is in line with outcomes described in other series.^{10,22}

At the end of follow-up, an increase in BCVA, overall and in each assessed group, was noted. However, BCVA values showed a more rapid increase in group 1 compared with group 2. In group 1 that achievement occurred since the first month after ocriplasmin injection, whereas a similar increase was only observed in group 2 at the end of the follow-up period. This difference may be explained by the stability induced by the elimination of the traction effect on DME evolution, in group 1, with less fluctuations in macular thickness, due to the edema. Previous trials have shown that the number of anti-VEGF injections decrease with time.²⁴ In our series that decrease was documented only in group 1. Patients in group 2 maintained the same median number of injections in post-ocriplasmin phase because DME was not controlled without them, and the anti-VEGF treatment maintained the edema under control. This may explain the median CSFT value, without variation during the post-ocriplasmin phase. In group 1, the same stability in CSFT was achieved but with a lower number of IV injections needed, and in some cases without the need of any IV injections.

The increase in BCVA, both in group 1 and in group 2 compared with baseline (in eyes already being under treatment before), may be explained by a more tight monthly follow-up after the inclusion in this prospective study as pre-defined in the study protocol. The authors acknowledge that in real-life, PRN IV anti-VEGF regimens may lead to a DME insufficient treatment approach with subsequent suboptimal functional and anatomical results. Also, the known positive effect of ocriplasmin on increasing oxygen concentration in the vitreous cavity may have played a role.⁴

Regarding safety issues, side effects of ocriplasmin were transitory and well tolerated. Mild visual acuity of less than six letters decrease, pain or discomfort, floaters, and photopsias were not referred beyond the first follow-up visit (performed at the fourth day post-ocriplasmin). Although there are evidence suggesting that DME patients with VMA have a higher potential to improve visual acuity,²⁴⁻²⁶ these are based on study methods in which a non-VMA adhesion was assumed based only on OCT images and not

confirmed with eye ultrasonography. OCT is not completely accurate to diagnose vitreous attachment or PVD, particularly when the adhesion cannot be seen, especially in diabetic eyes in which vitreoschisis is highly prevalent.²⁷ There is still a lack of studies comparing both methods on the evaluation of vitreoretinal interface. In the Read 3 study,²⁴ there is also a contradiction: the best functional and anatomical outcomes were verified in PVD cases (obtained spontaneously in four out of the low number of five eyes with focal VMA), the paradigm of a complete non-VMA status. In fact, a broad *versus* a focal type of adhesion are different types of adhesions and cannot be assumed as having the same influence in DME evolution.

The lack of a standardized anti-VEGF drug may be considered a weakness of this study. However, the type of anti-VEGF used has not been reported as a relevant factor for VMA occurrence. The same anti-VEGF option was maintained during both the retrospective and prospective phases.

In addition, although the majority of studies use less than 350 μm of thickness as the threshold for treatment, it is our opinion that when a focal VMA exists (Figure 1) an extra mechanical factor influences the distribution of intra-retinal macular edema, near the focal adhesion region, sometimes with an almost dry adjacent peri-foveal area.

It may also be questionable why vision improvement was relatively higher after inclusion in the prospective period, in both groups (8.5 letters in group 1 and 11 letters in group 2). This result may suggest that patients were being undertreated before entering the trial. In our opinion that fact can add even more value to the results of this study: with a higher previous number of injections a more significant reduction in the number of injections would have been expected in group 1.

The results of this study favor the positive effect in DME obtained by the release of a focal VMA even without a PVD achievement. The VMA release seems to be more important than the PVD occurrence itself for DME evolution. Nevertheless, that inference cannot be claimed as relevant in this study because of the small absolute number of eyes with PVD in the group with VMA release.

To our knowledge, this is the first study reporting the use of ocriplasmin specifically in a DME

group of patients. On the subanalyses of the two phase 3 clinical trials, the basis for the approval of ocriplasmin for vitreomacular traction and macular holes, ocriplasmin was referred to be used in diabetic retinopathy in 6.9% of the 652 patients included (45 patients), with no specific considerations regarding DME control or diabetic retinopathy status.^{22,23}

Furthermore, although the authors acknowledge that a focal VMA release may be anticipated earlier as a spontaneous occurrence, especially in eyes that underwent IV injections,²⁵ in this study the majority of the eyes showed a VMA release within the first month after ocriplasmin injection, increasing the probability of this event as a result of ocriplasmin treatment and not a haphazard development.

This study has some limitations, such as the absence of a control group, the small cohort included and also the relatively short duration of follow-up, with the additional difficulty inherent to the multifactorial nature of DME. Future studies with a larger number of cases are warranted to confirm the benefits attained in our study population.

Conclusion

The main result of this study was that if the VMA disappears after ocriplasmin injection the anti-VEGF injection burden could be reduced. However, if inflammation is the main cause of sustained DME rather than VMA, VMA release may be less effective in improving DME, and this approach can be unsuccessful in some patients. Indeed, in one case there was still a need for five anti-VEGF injections for 6 months. Therefore, a VMA release may not be the solution for all DME cases. However, when the gold standard therapy fails or if the anti-VEGF burden is too high, this treatment strategy should be considered. The results of this study emphasize the importance of VMA as an anatomic biomarker, when there is a need to decide which is the best treatment approach in DME.

Author contributions

All authors contributed equally to this paper regarding the design of the study, data collection, and statistical analysis. B.P. wrote the first draft of the paper which was critically reviewed and discussed by all authors prior to submission. All authors have seen and approved the submitted version of the paper.

Conflict of interest statement

The authors declared no potential conflicts of interest with respect to the research, authorship, and/or publication of this article.

Ethical approval

The study protocol has been approved by the research institute's committee on human research.

Funding

The authors received no financial support for the research, authorship, and/or publication of this article.

Informed consent

Subjects have given their written informed consent.

ORCID iDs

Bernardete Pessoa  <https://orcid.org/0000-0002-5673-1561>

João Coelho  <https://orcid.org/0000-0003-2261-5682>

Constança Coelho  <https://orcid.org/0000-0002-5331-2257>

References

1. Hikichi T, Fujio N, Akiba J, *et al.* Association between the short-term natural history of diabetic macular edema and the vitreomacular relationship in type II diabetes mellitus. *Ophthalmology* 1997; 104: 473–478.
2. Johnson MW. Posterior vitreous detachment: evolution and complications of its early stages. *Am J Ophthalmol* 2010; 149: 371.e1–382.e1.
3. Klein R, Moss SE, Klein BE, *et al.* The Wisconsin epidemiologic study of diabetic retinopathy. XI. The incidence of macular edema. *Ophthalmology* 1989; 96: 1501–1510.
4. Holekamp NM. The vitreous gel: more than meets the eye. *Am J Ophthalmol* 2010; 149: 32–36.
5. Lewis H, Abrams GW, Blumenkranz MS, *et al.* Vitrectomy for diabetic macular traction and edema associated with posterior hyaloidal traction. *Ophthalmology* 1992; 99: 753–759.
6. Nasrallah FP, Jalkh AE, Van Coppenolle F, *et al.* The role of the vitreous in diabetic macular edema. *Ophthalmology* 1988; 95: 1335–1339.
7. Quiram PA, Leverenz VR, Baker RM, *et al.* Microplasmin-induced posterior vitreous

- detachment affects vitreous oxygen levels. *Retina* 2007; 27: 1090–1096.
8. Adelman R, Parnes A, Michalewska Z, *et al.* Strategy for the management of diabetic macular edema: the European vitreo-retinal society macular edema study. *Biomed Res Int* 2015; 2015: 352487.
 9. Schulze S, Hoerle S, Mennel S, *et al.* Vitreomacular traction and exudative age-related macular degeneration. *Acta Ophthalmol* 2008; 86: 470–481.
 10. Figueira J, Martins D, Pessoa B, *et al.* The Portuguese Experience with Ocriplasmin in Clinical Practice. *Ophthalmic Res* 2016; 56: 186–192.
 11. Capeans C, Lorenzo J, Santos L, *et al.* Comparative study of incomplete posterior vitreous detachment as a risk factor for proliferative vitreoretinopathy. *Graefes Arch Clin Exp Ophthalmol* 1998; 236: 481–485.
 12. Trevino A, Martinez MR and Ophir A. Chronic macular edema associated with extrafoveal vitreoretinal traction. *Int J Ophthalmol* 2010; 3: 321–325.
 13. Bressler SB, Melia M, Glassman AR, *et al.* Ranibizumab plus prompt or deferred laser for diabetic macular edema in eyes with vitrectomy before anti-vascular endothelial growth factor therapy. *Retina* 2015; 35: 2516–2528.
 14. Chin HS, Park TS, Moon YS, *et al.* Difference in clearance of intravitreal triamcinolone acetonide between vitrectomized and nonvitrectomized eyes. *Retina* 2005; 25: 556–560.
 15. Lee SS, Ghosn C, Yu Z, *et al.* Vitreous VEGF clearance is increased after vitrectomy. *Invest Ophthalmol Vis Sci* 2010; 51: 2135–2138.
 16. Yanyali A, Aytug B, Horozoglu F, *et al.* Bevacizumab (Avastin) for diabetic macular edema in previously vitrectomized eyes. *Am J Ophthalmol* 2007; 144: 124–126.
 17. Meyer JC, Shah GK, Blinder KJ, *et al.* Early evolution of the vitreomacular interface and clinical efficacy after ocriplasmin injection for symptomatic vitreomacular adhesion. *Ophthalmic Surg Lasers Imaging Retina* 2015; 46: 209–216.
 18. Novack RL, Staurenghi G, Girach A, *et al.* Safety of intravitreal ocriplasmin for focal vitreomacular adhesion in patients with exudative age-related macular degeneration. *Ophthalmology* 2015; 122: 796–802.
 19. Sakuma T, Mizota A, Inoue J, *et al.* Intravitreal injection of autologous plasmin enzyme for macular edema associated with branch retinal vein occlusion. *Am J Ophthalmol* 2010; 150: 876–882.
 20. Johnson MW. Etiology and treatment of macular edema. *Am J Ophthalmol* 2009; 147: 11.e1–21.e1.
 21. Schmidt-Erfurth U, Garcia-Arumi J, Bandello F, *et al.* Guidelines for the management of diabetic macular edema by the European Society of Retina Specialists (EURETINA). *Ophthalmologica* 2017; 237: 185–222.
 22. Stalmans P, Benz MS, Gandorfer A, *et al.* Enzymatic vitreolysis with ocriplasmin for vitreomacular traction and macular holes. *N Engl J Med* 2012; 367: 606–615.
 23. Haller JA, Stalmans P, Benz MS, *et al.* Efficacy of intravitreal ocriplasmin for treatment of vitreomacular adhesion: subgroup analyses from two randomized trials. *Ophthalmology* 2015; 122: 117–122.
 24. Sadiq MA, Soliman MK, Sarwar S, *et al.* Effect of vitreomacular adhesion on treatment outcomes in the ranibizumab for edema of the macula in diabetes (READ-3) Study. *Ophthalmology* 2016; 123: 324–329.
 25. Gerendas B, Simader C, Deak GG, *et al.* Morphological parameters relevant for visual and anatomic outcomes during anti-VEGF therapy of diabetic macular edema in the RESTORE trial. *Invest Ophthalmol Vis Sci* 2014; 55: 1791.
 26. Gerendas BS, Prager SG, Deak GG, *et al.* Morphological parameters relevant for long-term outcomes during therapy of diabetic macular edema in the RESTORE Extension trial. *Invest Ophthalmol Vis Sci* 2015; 56: 4686.
 27. Schwatz SD, Alexander R, Hiscott P, *et al.* Recognition of vitreoschisis in proliferative diabetic retinopathy. A useful landmark in vitrectomy for diabetic traction retinal detachment. *Ophthalmology* 1996; 103: 323–328.