

Case Report

Isolated traumatic posterior dislocation of the radial head in an adult, a rare injury: New case report

Hélder Fonte*, Cláudia Rodrigues, João Vale, Joaquim Ramos, José Costa e Castro

Orthopaedics Department, Centro Hospitalar Universitário do Porto EPE, Porto, Portugal

ARTICLE INFO

Keywords:

Elbow
Traumatic dislocation
Radial head
Isolated
Adult

ABSTRACT

Isolated radial head dislocations are rare in adults with only 23 cases published in 45 years. The diagnosis may be easily missed on radiographs and a CT-scan is often required. If managed promptly patient can restore normal range of motion and elbow function. Authors report a new case of a 67-year-old female presenting a posttraumatic isolated posterior dislocation of the radial head. Treatment consisted of closed reduction followed by immobilization for four weeks in a plaster cast with the elbow flexed at 90°, followed by active mobilization and physiotherapy. At 18 months of follow-up, functional outcome is excellent with no differences between both sides.

Introduction

Isolated dislocation of the radial head without concomitant ulnar fracture or humeroulnar subluxation in adults is a rare injury, thereafter it can be easily unnoticed. Most of the reported cases suffered from posterior dislocation of radial head [1]. The evolved pathomechanism is unclear and the treatment is controversial [2]. We report a case of isolated, acute posttraumatic posterior dislocation of radial head in an adult, treated conservatively and with complete clinical and functional recovery, with 18 months of follow-up.

Statement of informed consent

Informed consent was obtained from the patient for publication of this case.

Case presentation

A 67-year-old woman, with no significant history, presented at the emergency department at our hospital after a fall of her height on the outstretched hand of her dominant upper limb, with indirect trauma of the right elbow. We speculate the mechanism in our patient to be hyperextension of the elbow with forearm in prone position. She had immediate onset of pain and presented with the elbow held in 90° of flexion and partial pronation, unable to mobilize the joint. Minimal swelling and some degree of tenderness were present on the lateral aspect of the elbow. Neurovascular examination of the upper limb was normal, with no evidence of posterior interosseous nerve palsy. An imaging study with radiographs and a CT-scan with three-dimensional reconstruction (Fig. 1) was performed, which revealed a posterior dislocation of the radial head, with no evidence of fractures or other concomitant injuries, neither lesions on homolateral shoulder or wrist. Closed reduction was achieved with gentle traction, by extending and supinating the

* Corresponding author at: Largo do Prof. Abel Salazar, 4099-001 Porto, Portugal.

E-mail address: u11681@chporto.min-saude.pt (H. Fonte).

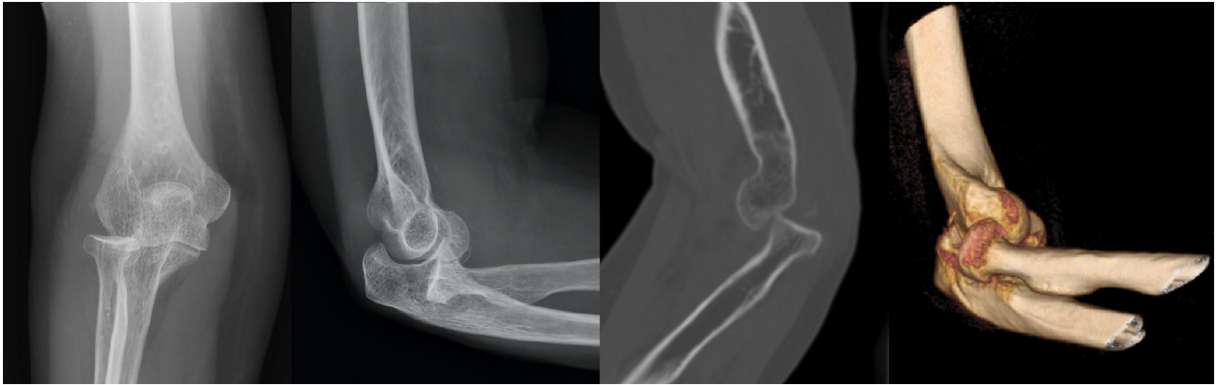

Fig. 1. X-Ray and CT scan (sagittal view and 3D reconstruction) of the right elbow, performed in the emergency department, showing a posterior isolated radial head dislocation, no evidence of fractures or other concomitant injuries.

forearm and applying pressure on the radial head (Fig. 2). Immobilization was done with an above elbow posterior cast with the elbow in 90° of flexion and slightly pronated which was maintained for four weeks. Further screening was done weekly to make sure that the radial head was in a reduced position. Active elbow mobilization was started after removal of the cast and the patient underwent a supervised physiotherapy program. At 6 months of follow-up, the patient had recovered clinically and functionally, with complete flexion-extension, 0–90° of supination, 0–80° of pronation. At 18 months of follow-up, functional outcome is excellent compared with the contralateral elbow with no differences between both sides (Fig. 3) and there was no recurrence of the lesion and the radiograph evaluation revealed no signs of complications (Fig. 4).

Discussion

Isolated dislocation of radial head is sparsely reported in the literature, with 23 cases published in 45 years. It has been predominantly posterior [3]. Whereas the dislocation of the radial head occurs usually associated with fractures of the forearm, like in the setting of a Monteggia lesion, isolated dislocation is extremely rare in adults [1,2]. A large number of previously reported isolated dislocations of the radial head in children are now thought to represent radial head dislocations accompanied by ulnar bowing [1,4]. Radial head dislocation accompanied by ulnar bowing has not been described in adults, with only a few cases of truly isolated dislocations of the radial head have been reported. This frequency seems underestimated because this lesion probably corresponds to an aborted postero-lateral elbow dislocation [5]. Numerous studies have examined distal radioulnar joint instability, but a paucity of information exists regarding the biomechanics of the proximal radioulnar joint [2]. The mechanism leading to an isolated radial head dislocation has been variously described and most authors describe an indirect trauma [6,7]. Various mechanisms have been postulated for isolated dislocation of radial head, like hyperpronating force acting on an already pronated forearm while falling backwards with an extended elbow or falling forward on an extended elbow with the forearm in pronation and rolling of the body causing further hyperpronation [7]. Bonatus et al. speculated the injury to occur in a position of hyperextension and supination and also proposed that the reduction manoeuvre to reduce the dislocation depended upon initial position of the forearm at presentation. Those presenting with the forearm in pronation required a supination force for reduction and vice versa [7].

To diagnose and reduce the dislocation promptly is of utmost importance. It can be easily missed on elbow radiographs and it is of paramount importance to have a high level of suspicion. The CT-scan seems important in this setting to identify the isolated radial head dislocation and exclude concomitant injuries. There is no consensus on which position of forearm rotation is best for

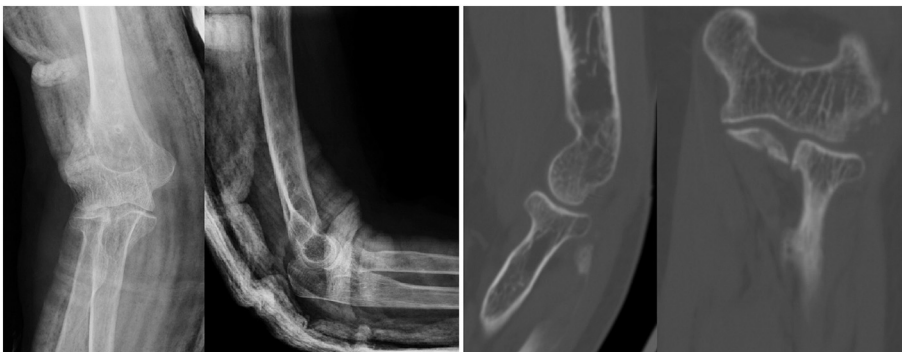

Fig. 2. X-Ray and CT-scan performed after closed reduction and immobilization, showing a correct reduction.

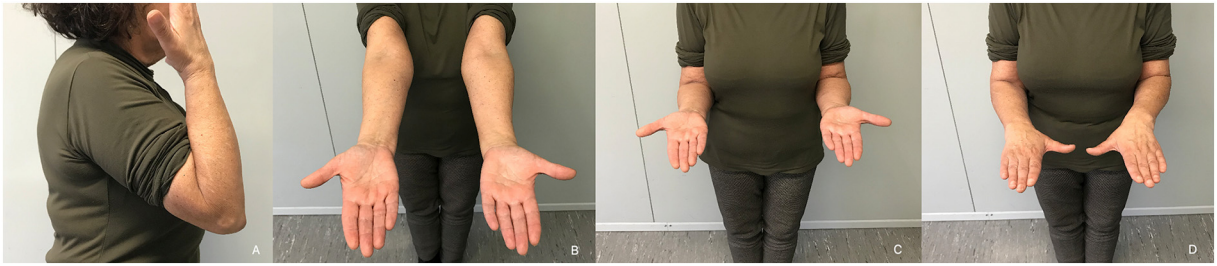


Fig. 3. Right elbow with normal range-of-motion at 18 months of follow-up (A – flexion, B – extension, C – supination, D – pronation).

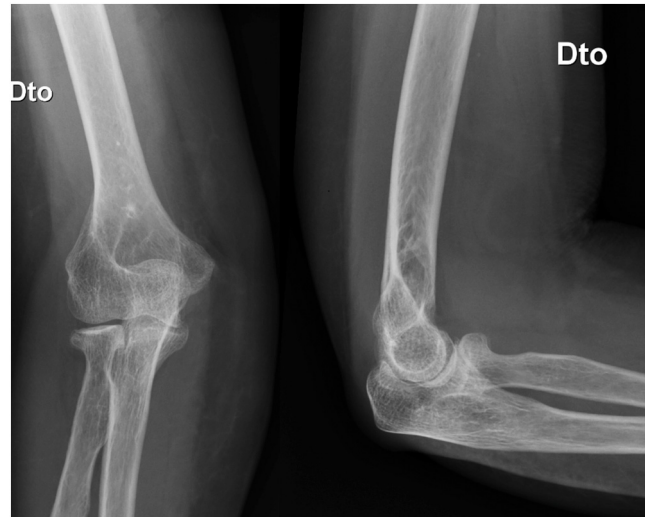


Fig. 4. X-Ray at 18 months of follow-up, showing no signs of complications.

stabilization of the radial head [2]. Several authors have recommended that the forearm be immobilized in supination rather than in neutral rotation or pronation, while others have recommended the neutral rotation after manual reduction of the radial head [8–10]. Closed reduction has been successful in most of the reported injuries like it was in this presenting case. In very few situations, open reduction has been required [3]. The results comparing stability among different forearm positions indicate that the ideal stabilizing position may differ depending on the direction of radial head dislocation. In patients with lateral radial head dislocation, supination may be recommended during post-reduction immobilization. In contrast, immobilization in pronation is recommended following closed reduction of posterior radial head dislocation [10].

Because radial head instability sometimes develops after reduction, treatments such as radial head excision, Kirschner-wire fixation, and modified Bell-Tawse repair have been proposed [1]. Closed reduction may not be successful in all cases. After the reduction, stability should always be checked. Such injuries should be addressed on a priority basis to prevent complications as elbow stiffness or recurrent radial head instability [5].

In conclusion, posttraumatic isolated radial head dislocations are extremely rare in adults and require a high index of suspicion. The diagnosis may be easily missed on radiographs and a CT-scan is often required. Early reduction is important to avoid the necessity for surgical treatment and its associated complications. If managed promptly and under a regular and supervised physiotherapy regime, the patient can restore normal range of motion and elbow function.

Declaration of competing interest

The authors declare that they have no conflicts of interest concerning this paper.

References

- [1] K. Watanabe, S. Iwabu, T. Hosoya, Traumatic isolated anterior dislocation of the radial head in an adult: a case report, *J. Shoulder Elb. Surg.* 14 (2005) 554–556.
- [2] N. Hayami, et al., Biomechanical study of isolated radial head dislocation, *BMC Musculoskelet. Disord.* 18 (2017) 1–7.
- [3] L. Obert, D. Hout, D. Lepage, P. Garbuio, Y. Tropet, Luxation traumatique isolée de la tête radiale chez l'adulte: À propos d'un cas et revue de la littérature, *Chir. Main* 22 (2003) 216–219.
- [4] Lincoln, T. L. & Mubarak, S. J. 'Isolated' traumatic radial-head dislocation. *J. Pediatr. Orthop.* 14, 454–7.
- [5] R. Kansay, S. Gupta, A. Soni, A. Malhotra, S.K. Garg, Isolated anterior dislocation of radial head in an adult with atypical presentation: a case report, *Rev. Bras.*

- Ortop. (English Ed.) (2018) 8–12, <https://doi.org/10.1016/j.rboe.2018.03.003>.
- [6] N. Manasseh, V. Madhuri, T.S. Jepeganmam, V.T. Kayalakagathu, Isolated, traumatic anterior dislocation of the radial head in an adult, *Eur. J. Trauma* 31 (2005) 170–173.
 - [7] T. Bonatus, M.W. Chapman, N. Felix, Traumatic anterior dislocation of the radial head in an adult, *J. Orthop. Trauma* 9 (1995) 441–444.
 - [8] E. Horii, et al., Surgical treatment for chronic radial head dislocation, *J. Bone Joint Surg. Am.* 84-A (2002) 1183–1188.
 - [9] K. Oka, T. Murase, H. Moritomo, K. Sugamoto, H. Yoshikawa, Morphologic evaluation of chronic radial head dislocation: three-dimensional and quantitative analyses, *Clin. Orthop. Relat. Res.* 468 (2010) 2410–2418.
 - [10] A. Dhawan, P.P. Hospodar, Isolated posttraumatic posterior dislocation of the radial head in an adult, *Am. J. Orthop. (Belle Mead. NJ)* 31 (83–6) (2002).