






CASE REPORTS

Lipschütz ulcer: a diagnosis to remember in acute genital ulceration in adolescents

Úlcera de Lipschütz: um diagnóstico a lembrar perante úlcera genital aguda na adolescência

Margarida Camacho de Sampaio¹ , Cátia Martins¹ , Patrícia Pereira² , Elsa Hipólito² , Maria Manuel Flores² 

ABSTRACT

Lipschütz ulcer (LU) is a rare cause of acute genital ulceration, usually in a mirror pattern, that mainly affects adolescents without previous sexual contact. The aetiology is unclear, but infectious and idiopathic causes have been associated with its onset. LU can cause significant pain but is self-limited and typically resolves within two to six weeks.

A case report of a 12-year-old girl with LU is presented, who was initially misdiagnosed with genital herpes. After excluding other causes of genital ulceration, she was ultimately diagnosed with LU and treated with symptomatic medication for pain control and healing optimization.. The patient fully recovered after five weeks and remained asymptomatic after one year.

LU is a rare cause of vaginal ulceration in non-sexually active adolescents that can be easily overlooked in the differential diagnosis. The disease is self-limited, but in some cases may require hospitalization for pain management.

Keywords: adolescents; Lipschütz; ulcer; vagina; vulva

RESUMO

A Úlcera de Lipschütz (UL) é uma causa rara de ulceração genital aguda, em padrão em espelho, que ocorre em adolescentes sem atividade sexual. Caracteriza-se pelo aparecimento súbito de ulcerações necróticas dolorosas na vulva e/ou vagina e a sua etiologia é incerta, embora tenham sido associados alguns agentes infecciosos. Pode condicionar dor severa, mas, habitualmente, é um quadro autolimitado com resolução em duas a seis semanas.

É apresentado o caso de uma adolescente de 12 anos com UL, que foi inicialmente diagnosticada com herpes genital. Ficou internada por dor intensa e, após excluir outras causas de úlcera genital, foi diagnosticada com UL, tendo realizado tratamento de suporte. Após cinco semanas teve recuperação completa e um ano após o episódio, mantém-se assintomática.

A UL é um diagnóstico de exclusão, raro e por vezes esquecido no diagnóstico diferencial de ulceração vaginal em adolescentes que não sejam sexualmente ativas. É uma doença autolimitada, no entanto pode condicionar dor intensa com necessidade de internamento para controlo algico.

Palavras-chave: adolescência; Lipschütz; úlcera; vagina; vulva

1. Department of Pediatrics, Hospital Pediátrico de Coimbra, Unidade Local de Saúde de Coimbra. 3000-602 Coimbra, Portugal
margaridacamachosampaio@gmail.com; aitacmartins@gmail.com
2. Department of Pediatrics, Unidade Local de Saúde de Aveiro. 3810-164 Aveiro, Portugal.
patrigpereira@gmail.com; elsachipolito@gmail.com; mariamanueflores@gmail.com

INTRODUCTION

Lipschütz ulcer (LU) is a rare cause of acute genital ulceration (AGU) of nonvenereal origin that mostly affects young women and adolescents without previous history of sexual contact. It is characterized by painful necrotic ulcerations on the vulva and/or vagina.⁽¹⁾ This pathology is poorly understood and probably underdiagnosed, making its true incidence impossible to estimate. Literature on the subject is scarce, based mostly on reports and case series.^(1, 2)

LU is usually associated with fever and malaise, and sometimes associated with other conditions, including asthenia, myalgia, pharyngotonsillitis, adenopathy, and headache. The ulcers are deep, necrotic, with purplish single or multiple margins, presenting in a mirror pattern, and primarily affect the medial face of the labia minora.⁽¹⁾

The differential diagnosis includes sexually transmitted infections (genital herpes, syphilis, Human Immunodeficiency Virus (HIV)), local manifestations of systemic diseases (Behçet's disease, Crohn's disease, pyoderma gangrenosum), autoimmune blistering diseases (pemphigus, pemphigoid), trauma, malignant tumors of the vulva and drug reactions.⁽³⁾

Although there are no strict criteria for the diagnosis, the following characteristics usually are required: age less than 20 years, first episode of AGU, sudden and acute evolution, presence of one or multiple vulvar ulcerations; absence of immunodeficiency; and exclusion of other known causes of genital ulceration.⁽⁴⁾

CASE REPORT

We present a case of a 12-year-old healthy female adolescent with no previous history of recurrent genital/oral ulcers or sexual intercourse up to that moment, that was admitted to the Emergency Service (ES) with a three-day history of fever, vulvar pain and vaginal secretions that progressively worsened. There was no history of recent infectious disease or trauma. Gynecology was consulted and described three ulcers in labia minora, the largest one with 1,5 cm of diameter and red-violaceous borders and a necrotic base covered with an adherent gray-black eschar. The diagnosis of genital herpes was assumed and she was discharged from the ES medicated with oral and topical antiviral (acyclovir). She returned to the ES four days later, on D7 of the illness due to worsening pain (dysuria and difficulty walking due to severe pain). On physical examination she presented an exuberant vulvar edema, three deep ulcers on the internal surface of the left and right labia minora, with a violaceous border and partially symmetric appearance ("kissing lesions"), see **figure 1**. Laboratory evaluation showed leukocytosis (23.300/uL) and neutrophilia (18.869/uL), slight lymphopenia (1.320/uL), elevated protein C reactive (17,05mg/dl), Serum electrolytes and transaminases without alterations. Given the severe pain that was

not controlled with oral analgesics and the suspicion of bacterial superinfection she was hospitalized for parenteral analgesics and antibiotics, with amoxicillin and clavulanic acid. For complementary investigation it was performed serology for EBV, CMV, HIV, Hepatitis C (HCV), Mycoplasma and Chlamydia trachomatis that were found to be negative as well as Venereal Disease Research Laboratory (VDRL). Ulcer swab for Herpes Simplex Virus (HSV) 1 and 2 DNA by polymerase chain reaction (PCR) was also negative. Urinalysis revealed no infection. She was consulted by Rheumatology and underwent complementary investigation with autoimmunity markers, which was also negative.

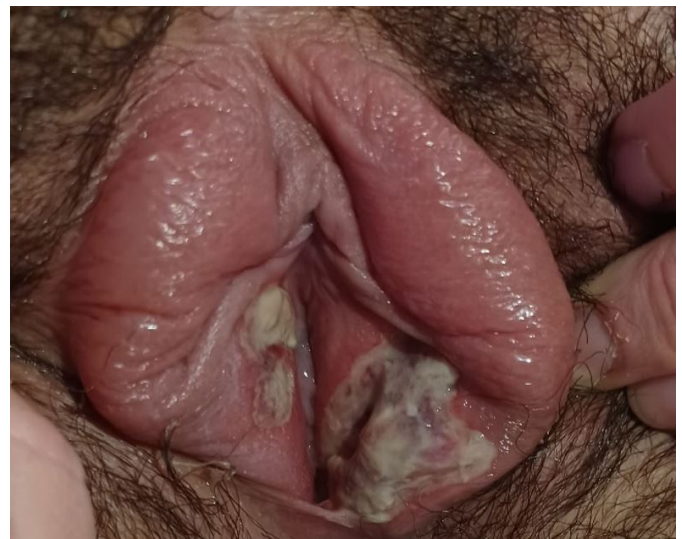

Figure 1 - kissing lesions on day 7 of disease

She required intravenous analgesia every four hours with acetaminophen and dipyron associated with a topical anaesthetic (lidocaine 2%). She accomplished five days of methylprednisone and maintained oral valacyclovir and topical acyclovir (total seven days) until the result of the HSV investigation was known. After excluding other causes for genital ulceration, the diagnosis of Lipschütz ulcer was assumed.

She was hospitalized for a total of ten days with slowly but progressive improvement of cicatrization of the lesions and associated pain, **figure 2**. Five weeks after the onset of the symptoms she had total resolution and re-epithelization of the lesions, **figure 3**. One year later the patient remained asymptomatic.

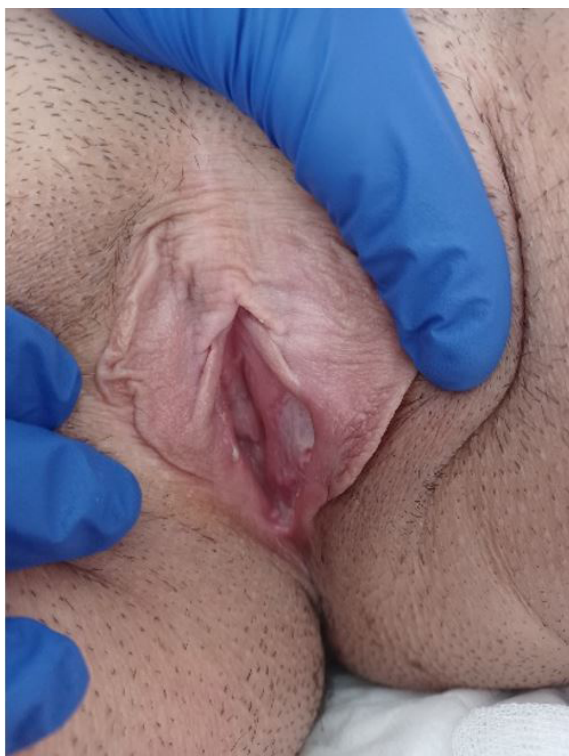

Figure 2 - Lipschütz ulcer at discharged (day 17 of disease)

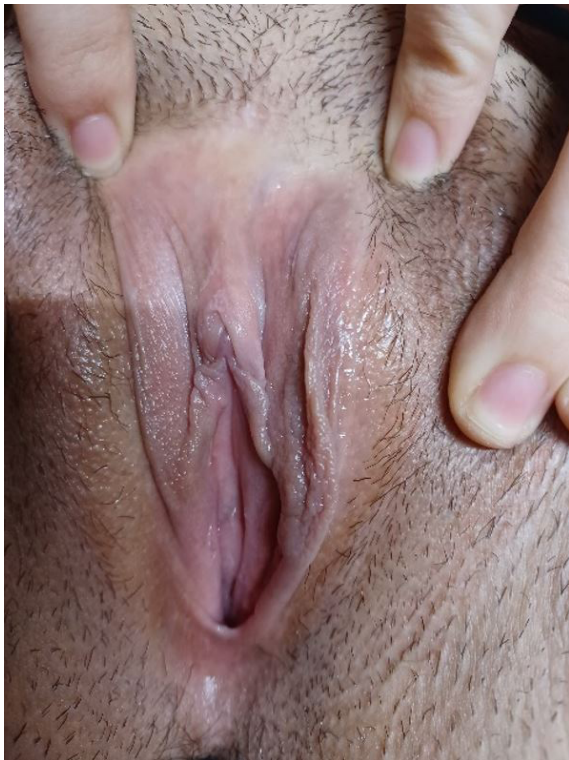

Figure 3 - Lesions five weeks after onset with complete cicatrization

DISCUSSION

In 1913, the Australian dermatologist Benjamin Lipschütz identified a type of medical condition that presents as painful genital ulcerations accompanied by fever and swelling of the lymph nodes, and which typically affects adolescents without any history of sexual contact. This condition is known as LU.^(1,2) LU usually appear as one or more shallow ulcers with raised, distinct borders that may have a gray exudate or an adherent gray-brown eschar. The affected area may also show erythema and significant oedema, as in our case. Typically, these ulcers occur on the medial aspects of the labia minora, but they can also occur on the labia majora, perineum, and lower vagina. It's common to find "kissing" ulcers on opposing surfaces. The size of the ulcers can vary, and lesions greater than 1 cm have been reported. Similar to our report, in addition to the ulcers, patients with LU may experience symptoms such as malaise, fever, asthenia, myalgia, headache, sore throat or tonsillitis, and lymphadenopathy.^(5,6)

Males can also be affected, although more rarely, by LU in the form of scrotal or penile ulcer.⁽²⁾

Since the first description several etiologies have been discussed. Viral pathogens may cause ulcers. The reported rate of EBV associated with AGU seems to be around 30%. Pathological agents have been found to be associated with episodes of AGU, including CMV, paratyphoid fever, influenza A, *Toxoplasma gondii*, *Mycoplasma* and mumps. It has been suggested a direct cytotoxic effect, a role of B lymphocytes EBV-infected or a reactive process typically triggered by a distant infection with immune complex deposition causing a type III hypersensitivity reaction but recent case reports have detected EBV directly from ulcer swabs and biopsy specimens via PCR.^(4,5) Most of the viral infections mentioned above are more frequent in children and young people, facts that could justify the greater involvement of that population.

In individuals who were previously healthy, vulvar ulcers are commonly caused by sexually transmitted microorganisms such as *Treponema pallidum*, HSV, and, less frequently, certain strains of *Chlamydia trachomatis*. In some cases, primary infection with the HIV can also lead to vulvar ulcers. Non-infectious causes of vulvar ulcers include autoimmune disorders such as Behçet's disease and Crohn's disease, cancer (such as leukemia), drug reactions, and physical trauma.⁽²⁾

It's important to recognize that the presence of genital ulcers in children may indicate sexual abuse or early sexual activity. Diagnosis of this entity is made by exclusion, sometimes retrospectively. Therefore, healthcare providers should be aware of the various causes of non-sexually transmitted ulcers, including Lipschütz ulcer, so that each case can be evaluated appropriately, based on the specific characteristics of the lesion, associated symptoms, and clinical manifestations. A thorough examination, medical history, and diagnostic testing may be necessary to properly diagnose the underlying condition.⁽¹⁾

Laboratory evaluation should always include a complete blood cell

count, serological test for syphilis, EBV, HIV and PCR assays for HSV, bacterial culture and viral culture or PCR of the lesion. Sometimes, skin biopsy from an ulcer edge could be necessary to rule out other conditions but histological examination is not of diagnostic value for its nonspecific findings, namely superficial oedema and dilated capillaries with neutrophilic infiltration and ulceration. When diagnostic tests are negative, the patient fits the clinical criteria for LU.⁽⁵⁾

Vieira-Baptista et al. conducted a retrospective study and found 110 cases of acute genital ulcer in a clinical center specialized in vulvar lesions. Of these, 33 (30%) patients were diagnosed as LU, including women of any age, sexually active or not, with recurrence or not. The analysis of those cases indicated the need for less strict criteria for diagnosing LU.⁽⁷⁾

In a systemic review between 1966 and 2019, of Vismara et al, 112 where included reports corresponding to 180 patients (3 reports were from Portugal) and 90% of the patients were ≤ 20 years of age and sexually inactive. Lesions were usually one to about three (more than 80% of cases), painful, larger than 10mm, well-delimited, with a fibrinous, necrotic, or purulent center and often (45%) a symmetric mirror-like vulvar distribution. Voiding disorders (32%) and enlarged inguinal lymph nodes were observed in a large subset (24%) of cases. Oral ulcers were noted in 10% of patients. The disease resolved on average after 15 days. A duration of over 28 days was observed in about 10% of cases. No recurrence was reported. LU occurred concomitantly with an infectious disease in 139 (88%) of the 158 cases: a flu-like syndrome in 79 and a well-defined infection in 56 cases.⁽²⁾

The goals of treatment are pain relief, improve healing and prevent scarring. Empiric treatment includes sitz baths, topical anesthetic, and topical corticosteroids. If the patient has severe pain or malaise, hospitalization is indicated. Broad-spectrum antibiotics to cover skin flora should be considered. Systemic corticosteroids are often prescribed if concomitant infectious mononucleosis.^(8,9) Usually is a self-limited condition that resolves spontaneously in two to six weeks. Recurrences have been reported in approximately 30 to 50 percent of the cases.^(7,10,11)

Is important to note that LU may be underdiagnosed because acute genital ulcers rarely lead to hospitalization or hospital care. These patients usually seek gynecological, dermatological, or clinical outpatient care, and LU is misdiagnosed and treated as a herpes simplex infection in many cases, as it occurred in our case. Moreover, the availability of serologic evaluation is limited and, therefore, it is common that some patients remain idiopathic.⁽¹⁾

CONCLUSION

Lipschütz ulcer is rare and sometimes forgotten in the differential diagnosis of vaginal ulceration in non-sexually active adolescents. Differential diagnosis is extensive and includes ulcers of venereal and

non-venereal origin, non-infectious diseases, trauma, and malignant tumors of the vulva.

It is a self-limited disease, with spontaneous and complete healing of the ulcer in two to six weeks; however, it may cause intense pain and require hospitalization for pain control.

AUTHORSHIP

Margarida Camacho de Sampaio - Research and elaboration of the manuscript; Clinical evaluation of patients and drafting of the manuscript; approve the final version version

Cátia Martins - Research and elaboration of the manuscript; Clinical evaluation of patients and drafting of the manuscript; approve the final version version

Patrícia Pereira - Clinical evaluation of patients and drafting of the manuscript; approve the final version version

Elsa Hipólito - Clinical evaluation of patients and drafting of the manuscript; Revision of the manuscript; approve the final version version

Maria Manuel Flores - Clinical evaluation of patients and drafting of the manuscript; Revision of the manuscript; approve the final version version

REFERENCES

1. Schindler Leal AA, Piccinato CA, Beck APA, Gomes MTV, Podgaec S. Acute genital ulcers: keep Lipschütz ulcer in mind. *Arch Gynecol Obstet.* 2018;298(5):927-31. Epub 2018/08/26. doi: <https://doi.org/10.1007/s00404-018-4866-6>. PubMed PMID: 30143859.
2. Vismara SA, Lava SAG, Kottanattu L, Simonetti GD, Zraggen L, Clericetti CM, et al. Lipschütz's acute vulvar ulcer: a systematic review. *Eur J Pediatr.* 2020;179(10):1559-67. Epub 2020/04/17. doi: <https://doi.org/10.1007/s00431-020-03647-y>. PubMed PMID: 32296983.
3. Ueda Y, Kamiya K, Ohtsuki M. Reactive nonsexually related acute genital ulcers. *J Gen Fam Med.* 2018;19(1):30-1. Epub 2018/01/18. doi: <https://doi.org/10.1002/jgf2.139>. PubMed PMID: 29340264; PubMed Central PMCID: PMC5763018.
4. Haidari G, MacMahon E, Tong CY, White JA. Genital ulcers: it is not always simplex *Int J STD AIDS.* 2015;26(1):72-3. Epub 2014/06/28. doi: <https://doi.org/10.1177/0956462414541241>. PubMed PMID: 24970475.
5. Delgado-García S, Palacios-Marqués A, Martínez-Escoriza JC, Martín-Bayón TA. Acute genital ulcers. *BMJ Case Rep.* 2014;2014. Epub 2014/01/30. doi: <https://doi.org/10.1136/bcr-2013-202504>. PubMed PMID: 24473429; PubMed Central PMCID: PMC3912377.
6. Popatia S, Chiu YE. Vulvar aphthous ulcer after COVID-19

- vaccination. *Pediatr Dermatol.* 2022;39(1):153-4. Epub 2021/12/11. doi: <https://doi.org/10.1111/pde.14881>. PubMed PMID: 34888935.
7. Vieira-Baptista P, Lima-Silva J, Beires J, Martinez-de-Oliveira J. Lipschütz ulcers: should we rethink this? An analysis of 33 cases. *Eur J Obstet Gynecol Reprod Biol.* 2016;198:149-52. Epub 2015/08/25. doi: <https://doi.org/10.1016/j.ejogrb.2015.07.016>. PubMed PMID: 26297242.
 8. McKercher A, Aksoy T. Lipschutz Ulcer: A Rare Cause of Acute Genital Ulcers. *J Obstet Gynaecol Can.* 2018;40(8):1001. Epub 2017/07/16. doi: <https://doi.org/10.1016/j.jogc.2017.05.001>. PubMed PMID: 28709766.
 9. Arellano J, Fuentes E, Moreno P, Corredoira Y. [Ulcer of Lipschütz, a diagnosis to consider in the pediatric population]. *Arch Argent Pediatr.* 2019;117(3):e305-e8. Epub 2019/05/08. doi: <https://doi.org/10.5546/aap.2019.e305>. PubMed PMID: 31063323.
 10. Farhi D, Wendling J, Molinari E, Raynal J, Carcelain G, Morand P, et al. Non-sexually related acute genital ulcers in 13 pubertal girls: a clinical and microbiological study. *Arch Dermatol.* 2009;145(1):38-45. Epub 2009/01/21. doi: <https://doi.org/10.1001/archdermatol.2008.519>. PubMed PMID: 19153341.
 11. Rosman IS, Berk DR, Bayliss SJ, White AJ, Merritt DF. Acute genital ulcers in nonsexually active young girls: case series, review of the literature, and evaluation and management recommendations. *Pediatr Dermatol.* 2012;29(2):147-53. Epub 2012/02/04. doi: <https://doi.org/10.1111/j.1525-1470.2011.01589.x>. PubMed PMID: 22300420.

CORRESPONDENCE TO

Margarida Camacho de Sampaio
Department of Pediatrics,
Hospital Pediátrico de Coimbra
Unidade Local de Saúde de Coimbra
R. Dr. Afonso Romão
3000-602 Coimbra
Email: margaridacamachosampaio@gmail.com

Received for publication: 02.01.2024

Accepted in revised form: 18.09.2024