

# Non-Small Cell Lung Cancer: Screening, Diagnosis, and Staging

João Pedro Ferreira<sup>1</sup>, Manuel Magalhães<sup>2</sup>, Estrela Rocha<sup>2</sup> and Franklin Marques<sup>2</sup>

**Affiliations:** <sup>1</sup>Internal Medicine Department, Centro Hospitalar do Porto, Porto, Portugal and <sup>2</sup>Oncology Department, Centro Hospitalar do Porto, Porto, Portugal (Submission Date: 26 November 2011; Accepted Date: 21 March 2012; Publication Date: 26 April 2012)

## ABSTRACT

Lung cancer is the leading cause of cancer deaths worldwide. Tobacco consumption is the primary cause of lung cancer, accounting for more than 85%–90% of all lung cancer deaths. Non-small cell lung cancer accounts for about 85% of all lung cancers.

Several studies have shown that low-dose helical CT of the lung detects more nodules and lung cancers, including early-stage cancers, than does chest radiography. The National Lung Cancer Screening Trial results show that three annual rounds of low-dose CT screening reduce mortality from lung cancer. Despite the great debate around lung cancer screening, recently the National Comprehensive Cancer Network has come out in favor of lung cancer screening in an updated set of guidelines.

All patients who present with suspect lung cancer should have a complete and meticulous history and physical examination performed to identify symptoms or physical findings suggestive of locally extensive or metastatic disease, assess pulmonary health status, identify significant comorbidities, and assess overall health status.

Tissue sampling is required to confirm a diagnosis in all patients with suspected lung cancer. Non-surgical approaches, surgical approaches, or both may be used to obtain a tissue sample. Evaluation of the mediastinal lymph nodes is a key step in the further staging of the patient. The best way of evaluating mediastinal lymph nodes is still a matter of debate.

The tumor node metastasis (TNM) International Staging System provides useful prognostic information and is used to stage all patients with non-small cell lung cancer.

Recent trials added new data on screening and diagnostic approach. Those data will be reviewed in this paper.

**Keywords:** Lung, cancer, screening, diagnosis, mediastinal, nodes, staging

**Correspondence:** João Pedro Ferreira, MD (Resident 4th year), Internal Medicine Department, Centro Hospitalar do Porto, Largo Prof. Abel Salazar 4099-001 Porto e-mail: jp7ferreira@hotmail.com

## INTRODUCTION

Lung cancer is the leading cause of cancer deaths worldwide.<sup>1</sup> Tobacco consumption is the primary cause of lung cancer, accounting for more than 85%–90% of all lung cancer deaths. While tobacco smoking remains the primary cause of lung cancer worldwide, more than 60% of new lung cancer occur in former smokers (smoked  $\geq 100$  cigarettes per lifetime, quit  $\geq 1$  year) or never smokers (smoked  $< 100$  cigarettes per lifetime). Moreover, one in five women and one in 12 men diagnosed with lung cancer have never smoked. Environmental tobacco smoke or secondhand smoke, occupational exposure to asbestos, arsenic, nickel, mustard gas, bischloromethyl ether, hexavalent chromium, polycyclic aromatic hydrocarbons, and ionizing radiation are also established risk factors for lung cancer.<sup>2</sup> Lung cancer susceptibility and risk also are increased in inherited cancer syndromes caused by rare germ-line mutations in p53,<sup>3</sup> retinoblastoma,<sup>4</sup> and other genes.<sup>5,6</sup>

The two major forms of lung cancer are non-small cell lung cancer (NSCLC, about 85% of all lung cancers) and small-cell lung cancer (about 15%). Despite advances in early detection and standard treatment, NSCLC is often diagnosed at an advanced stage and has a poor prognosis. NSCLC

can be divided into three major histologic subtypes: (1) squamous-cell carcinoma, (2) adenocarcinoma, and (3) large-cell lung cancer. Smoking causes all types of lung cancer but is most strongly linked with small-cell lung cancer and squamous-cell carcinoma; adenocarcinoma is the most common type in patients who have never smoked.<sup>7–9</sup>

Recent trials added new data on screening and diagnostic approach. Those data will be reviewed here.

## EARLY DETECTION AND SCREENING

For a screening program to be successful, the burden of the disease in the population must be high, effective treatment must be available, the test must be low risk, reproducible, accessible, cost-effective, and both sensitive and specific, and there should be an effective treatment or intervention for patients identified through early detection, with evidence of early treatment leading to better outcomes than late treatment.

The large majority of NSCLC patients present with symptoms in a late advanced stage, and diagnosis occurs mostly in locally advanced or metastatic disease with a very poor rate of cure. The issue of lung cancer screening has

consequently a strong rationale, to increase the detection of early NSCLC potentially cured by surgery.

Although effective mass screening of high-risk groups could potentially be of benefit, randomized trials of screening with the use of chest radiography with or without cytologic analysis of sputum specimens have shown no reduction in lung-cancer mortality.<sup>10</sup>

Advances in multidetector computed tomography (CT), however, have made high-resolution volumetric imaging possible in a single breath hold at acceptable levels of radiation exposure.<sup>11</sup> Several studies<sup>10,12–17</sup> have shown that low-dose helical CT of the lung detects more nodules and lung cancers, including early-stage cancers, than does chest radiography.

The National Lung Cancer Screening Trial (NLST),<sup>18</sup> a large prospective randomized trial funded by the National Cancer Institute (NCI), to determine whether screening with low-dose CT, as compared with chest radiography (CXR), would reduce mortality from lung cancer among high-risk persons. In this trial 53,454 participants, between 55 and 74 years of age and a history of heavy smoking, were enrolled. Participants were randomly assigned to undergo three annual screenings with either low-dose CT (26,722 participants) or single-view posteroanterior chest radiography (26,732 participants). Non-calcified nodules measuring 4 mm were considered to be positive, as were abnormalities such as effusions and adenopathy. During median follow-up of 6.5 years, lung cancer–specific mortality was significantly lower in the CT group than in the CXR group—relative reduction of 20.0% (95% CI, 6.8–26.7;  $P = .004$ ). Deaths attributed to invasive diagnostic procedures and cancer treatments were considered lung cancer–related deaths. The number needed to screen to prevent one lung cancer death was about 320. False-positive screenings were common: 39% of participants in the CT group and 16% in the CXR group had at least one positive screen, and 95% of those results were false-positives. The NLST results show that three annual rounds of low-dose CT screening reduce mortality from lung cancer. However, many questions remain. For example, will radiologists generally be able to duplicate the performance of NLST study radiologists? In the community, will low-dose CT (as opposed to standard-dose CT) be readily available and will evaluation and follow-up of screen-positive patients maximize benefit and minimize harm? Given the high false-positive rate, how should we weigh the costs and morbidity of screening and its sequelae? Because of many pending questions, one should wait for further information before endorsing screening.<sup>19,20</sup> For those patients who want to be screened, physicians need to discuss the possible risks and benefits of screening. While lung cancers may be found, patients are at risk for more radiation exposure and false-positive results. The latter can result in multiple follow-up CTs and possible invasive procedures, with potential added costs, anxiety, and morbidity and mortality rates.<sup>2</sup>

Despite the great debate around lung cancer screening, which is a complex and controversial topic, recently the National Comprehensive Cancer Network (NCCN) has come out in favor

of lung cancer screening in an updated set of guidelines.<sup>21</sup> It recommends the use of helical low-dose CT screening for selected patients at high risk for the disease—risk assessment and screening modalities are discussed in the guidelines.

## CLINICAL MANIFESTATIONS

All patients who present with suspect NSCLC should have a complete and meticulous history and physical examination performed to identify symptoms or physical findings suggestive of locally extensive or metastatic disease, assess pulmonary health status, identify significant comorbidities, and assess overall health status. Each impacts the therapeutic options, patient's ability to tolerate treatment, and disease course in ways that are independent of the disease stage.<sup>20,22</sup>

Most symptoms and signs (eg, cough, hemoptysis, and postobstructive pneumonia) are non-specific. However, some signs and symptoms, such as weight loss, bone pain, dysphagia, neurologic abnormalities, superior vena cava syndrome, pericardial effusion, enlarged supraclavicular and scalene lymph nodes, and hepatomegaly or right upper quadrant pain, may suggest extensive disease.

NSCLC may cause paraneoplastic syndromes. These are characterized by endocrinopathy, neurologic disorders, metabolic abnormalities, hematologic disease, or skeletal syndromes and may be the presenting finding or the first sign of recurrence. In addition, paraneoplastic syndromes may mimic metastatic disease and, unless detected, lead to inappropriate palliative rather than curative treatment. In some cases, the pathophysiology of the paraneoplastic syndrome is known, particularly when a hormone with biologic activity is secreted by the tumor or an immunologic-mediated mechanism is involved. Often the paraneoplastic syndrome may be relieved with successful treatment of the tumor.<sup>2</sup> A detailed description of paraneoplastic syndromes is beyond the scope of this review.

## DIAGNOSTIC ASSESSMENT AND STAGING INVESTIGATIONS

Initial evaluation must include performance status, CT of the neck, chest and upper abdomen, including adrenals, complete blood count and platelets, chemistry profile, smoking cessation program (if needed), and pathology review (specific mutations may be a therapy target).<sup>23</sup>

Tissue sampling is required to confirm a diagnosis in all patients with suspected lung cancer. Pathologic evaluation is performed to classify the histologic type of the lung cancer, determine the extent of invasion, determine whether it is primary lung cancer or metastatic disease, establish the cancer involvement status of the surgical margins, and do molecular diagnostic studies to determine whether certain gene mutations are present (eg, EGFR mutations).

There are several options for sampling a primary tumor, including: (1) conventional flexible bronchoscopy with forceps biopsy, (2) blind transbronchial fine-needle aspiration, (TBNA), (3) image-guided percutaneous fine-needle aspiration or core-needle biopsy, (4) surgical biopsy, (5) endobronchial

ultrasound (EBUS)-guided biopsy, and/or (6) transesophageal endoscopic ultrasound-guided biopsy (EUS).

In patients with suspected metastatic disease, a diagnosis may be confirmed by percutaneous biopsy of a soft tissue mass, lymph node, lytic bone lesion, bone marrow, pleural or liver lesion, or an adequate cell sample obtained from a malignant pleural effusion. In patients with a suspected malignant pleural effusion, if the initial thoracentesis is negative, a repeat thoracentesis is recommended.<sup>2</sup> Series examining the diagnostic rate for malignancy of pleural cytology have reported a mean sensitivity of 60% (range 40%–87%).<sup>24–27</sup> In patients suspected of having lung cancer with an accessible pleural effusion, if the pleural fluid cytology finding is negative (after at least two thoracentesis), thoracoscopy is recommended as the next step if establishing the cause of the pleural effusion is thought to be clinically important. Thoracoscopic biopsy of the pleura is safe and can provide a definitive diagnosis with a high degree of accuracy and minimal risk to the patient. The reported sensitivity rate ranges between 80% and 99%. However, percutaneous, closed pleural biopsy is reported to be diagnostic for malignancy in only 50% of cases.<sup>28</sup>

The diagnostic yield of any biopsy depends on several factors including location and size of the tumor, tumor type, and technical aspects of the procedure. In general, central lesions are more readily diagnosed by bronchoscopic examination, while peripheral lesions are more amenable to transthoracic biopsy.<sup>29</sup> Bronchoscopic specimens include bronchial brush, bronchial wash, bronchioloalveolar lavage, and transbronchial biopsy (forceps biopsy, TBNA, and EBUS). Overall sensitivity for bronchoscopic methods is 85%–90%. Transthoracic FNA specimens have also great sensitivity (70%–95%).<sup>28–31</sup>

For patients who have multiple comorbidities or contraindications to invasive biopsy, sputum cytology should be considered, especially for patients with centrally located tumors, but pooled sensitivity is low (66%).<sup>28</sup>

Non-surgical approaches, surgical approaches, or both may be used to obtain a tissue sample from patients with suspected lymph node metastasis.<sup>23</sup> Depending on the location, lymph node sampling may occur via EBUS, EUS, or blind biopsy. In patients with palpable lymph nodes, a needle biopsy or needle aspiration may be used to obtain a tissue sample. Successful application of the non-surgical approaches may eliminate the need for a surgical staging procedure.

Evaluation of the mediastinal lymph nodes is a key step in the further staging of the patient. To detect mediastinal metastases, patients are routinely investigated with CT and positron emission tomography (PET), followed by mediastinal tissue staging for enlarged ( $\geq 10$  mm) or PET-positive intrathoracic nodes,<sup>32,33</sup> as imaging alone is inaccurate to replace invasive lymph node staging on tissue specimens.<sup>34–37</sup> In addition, the visual location of intrathoracic lymph nodes with PET is not always unequivocal because of the low spatial resolution of the PET images.<sup>38–40</sup> Integrated PET/CT scans theoretically overcome this problem because of the co-acquisition of CT and PET images, resulting in

so-called fusion images. However, no difference in accuracy was noted when integrated PET/CT scans were compared with CT scans alone.<sup>41</sup> A prospective study assessed the accuracy of the integrated PET/CT scan in the nodal staging of NSCLC and evaluated if tissue-confirmed lymph node staging by surgery or echo-endoscopy could be avoided.<sup>34</sup> This study found that integrated PET/CT scanning has an overall accuracy, which is too low to replace invasive intrathoracic lymph node staging. Another study found that integrated PET/CT provides low sensitivity and accuracy in intrathoracic nodal staging of NSCLC patients and underscore the continued need for histologic diagnosis.<sup>42</sup>

Undetected preoperative mediastinal metastases are a major cause of unnecessary thoracotomies, occurring in 28% of patients.<sup>36</sup> Unnecessary thoracotomies result in suboptimal treatment, significantly impaired functional health status, and avoidable mortality.<sup>43,44</sup>

Mediastinal tissue staging is classically performed by mediastinoscopy, a surgical diagnostic procedure with a sensitivity of approximately 80%.<sup>33</sup> Mediastinal lymph nodes can also be sampled under real-time ultrasound control from either the esophagus (EUS)<sup>45</sup> or the airways (EBUS).<sup>46</sup> Combined EUS and EBUS can reach almost all mediastinal nodal stations with a reported sensitivity of 93% (CI<sub>95%</sub>, 81%–99%) and 97% specificity (CI<sub>95%</sub>, 91%–99%) for establishing the presence of mediastinal disease in lung cancer patients.<sup>47</sup> Current lung cancer staging guidelines acknowledge endosonography as a minimally invasive alternative to surgical staging (mediastinoscopy) to detect nodal disease,<sup>21</sup> reducing the need for surgical staging in up to two thirds of patients.<sup>48,49</sup> A study was designed to examine the hypothesis that minimally invasive combined endoscopic procedures were as good as or even better than surgical staging (mediastinoscopy) for the evaluation of mediastinal lymph nodes in patients with lung cancer.<sup>49</sup> In this study, patients were eligible for mediastinal nodal sampling if they had mediastinal nodes with short axis  $\geq 10$  mm on CT or PET-positive mediastinal or hilar nodes or centrally located lung tumor. Patients with proven distant metastasis, irresectable disease (as judged by the thoracic surgeon on the available imaging), or small peripheral lung tumors without evidence of enlarged or PET-positive intrathoracic nodes were not considered for eligibility. The primary outcome was sensitivity for mediastinal nodal metastases. Secondary outcomes were rates of unnecessary thoracotomy and complications. Two hundred forty-one patients were randomized, 118 to surgical staging and 123 to endosonography, of whom 65 also underwent surgical staging. Nodal metastases were found in 41 patients (35%) by surgical staging versus 56 patients (46%) by endosonography ( $P = .11$ ) and in 62 patients (50%) by endosonography followed by mediastinoscopy ( $P = .02$ ). This study has shown that commencing mediastinal nodal staging with endosonography significantly improves the detection of nodal metastases and reduces the rate of unnecessary thoracotomies compared with mediastinoscopy alone, in patients with resectable NSCLC. This combined approach, with mediastinoscopy reserved for those patients with negative

**Table 1.** TNM Staging System for Lung Cancer (7th Edition)

Primary tumor (T)			
T1	Tumor $\leq 3$ cm diameter, surrounded by lung or visceral pleura, without invasion more proximal than lobar bronchus		
T1a	Tumor $\leq 2$ cm in diameter		
T1b	Tumor $> 2$ cm but $\leq 3$ cm in diameter		
T2	Tumor $> 3$ cm but $\leq 7$ cm, or tumor with any of the following features:		
	1. Involves main bronchus, $\geq 2$ cm distal to carina		
	2. Invades visceral pleura		
	3. Associated with atelectasis or obstructive pneumonitis that extends to the hilar region but does not involve the entire lung		
T2a	Tumor $> 3$ cm but $\leq 5$ cm		
T2b	Tumor $> 5$ cm but $\leq 7$ cm		
T3	Tumor $> 7$ cm or any of the following:		
	1. Directly invades any of the following: chest wall, diaphragm, phrenic nerve, mediastinal pleura, parietal pericardium, main bronchus $< 2$ cm from carina (without involvement of carina)		
	2. Atelectasis or obstructive pneumonitis of the entire lung		
	3. Separate tumor nodules in the same lobe		
T4	Tumor of any size that invades the mediastinum, heart, great vessels, trachea, recurrent laryngeal nerve, esophagus, vertebral body, carina, or with separate tumor nodules in a different ipsilateral lobe		
Regional lymph nodes (N)			
No	No regional lymph node metastases		
N1	Metastasis in ipsilateral peribronchial and/or ipsilateral hilar lymph nodes and intrapulmonary nodes, including involvement by direct extension		
N2	Metastasis in ipsilateral mediastinal and/or subcarinal lymph node(s)		
N3	Metastasis in contralateral mediastinal, contralateral hilar, ipsilateral or contralateral scalene, or supraclavicular lymph node(s)		
Distant metastasis (M)			
Mo	No distant metastasis		
M1	Distant metastasis		
M1a	Separate tumor nodule(s) in a contralateral lobe; tumor with pleural nodules or malignant pleural or pericardial effusion		
M1b	Distant metastasis (in extrathoracic organs)		
Stage groupings			
Stage IA	T1a-T1b	No	Mo
Stage IB	T2a	No	Mo
Stage IIA	T1a, T1b, T2a	N1	Mo
	T2b	No	Mo
Stage IIB	T2b	N1	Mo
	T3	No	Mo
Stage IIIA	T1a, T1b, T2a, T2b	N2	Mo
	T3	N1, N2	Mo
	T4	No, N1	Mo
Stage IIIB	T4	N2	Mo
	Any T	N3	Mo
Stage IV	Any T	Any N	M1a or M1b

Note: Adapted from: Goldstraw P, Crowley J, Chansky K, et al. The IASLC Lung Cancer Staging Project: Proposals for the revision of the TNM stage groups in the forthcoming (seventh) edition of the TNM classification of malignant tumours. *J Thorac Oncol.* 2007;2:706–16.

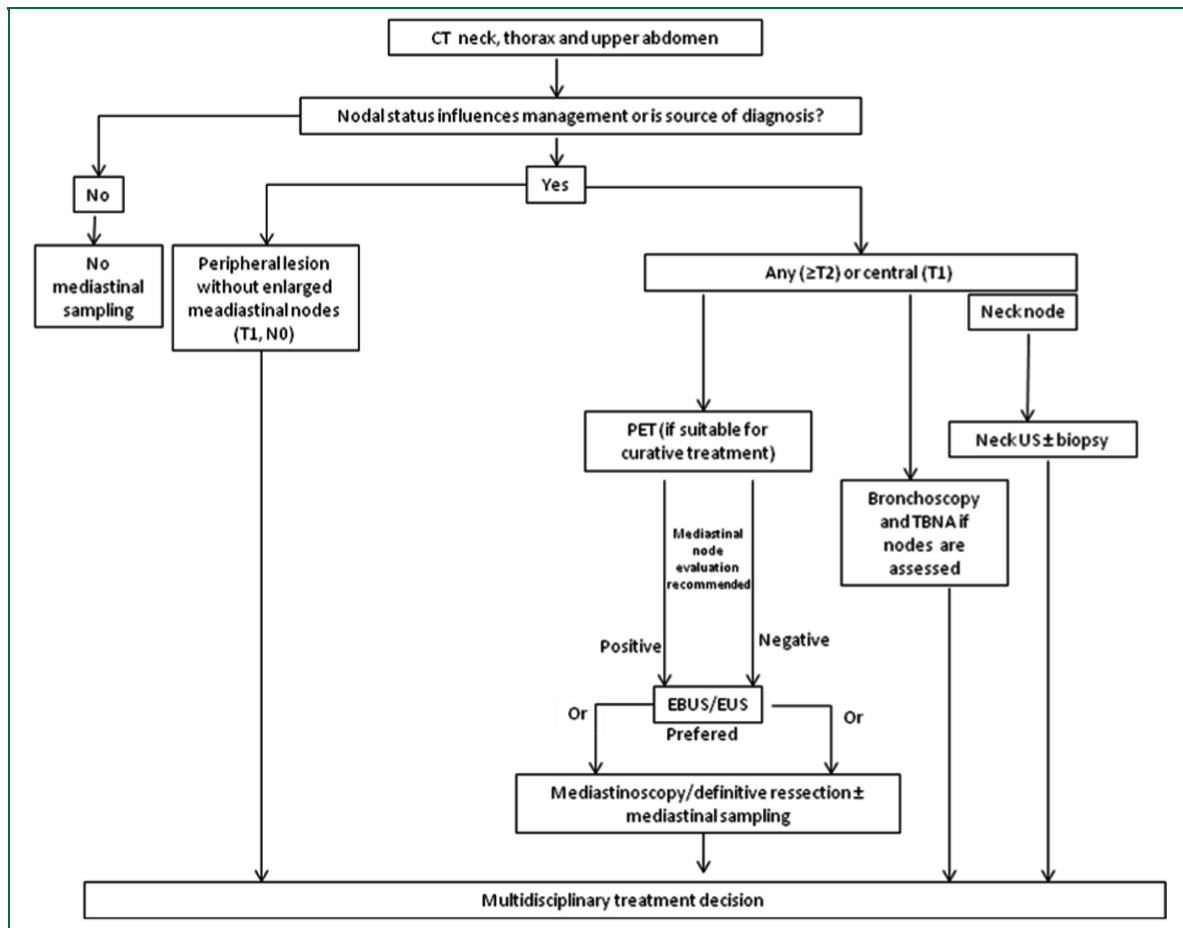


Figure 1. Detail of mediastinal diagnosis and staging.

findings on EBUS/EUS resulted in superior sensitivity and negative predictive value over mediastinoscopy alone. This benefit was not associated with a greater rate of complications. These results are consistent with findings of other studies.<sup>50</sup>

Missing mediastinal nodal metastases during preoperative surgical staging results in patients needlessly undergoing thoracotomy. Because almost all mediastinal nodes can be covered, a combined endosonography (EBUS/EUS) investigation could be superior to mediastinoscopy staging in the detection of nodal disease. Furthermore, endosonography does not require general anesthesia, is preferred by patients,<sup>51</sup> and is considered cost-effective<sup>52</sup> compared with surgical staging.

Even though this emerging technology of endoscopic study can have excellent results for predicting both positive and negative values, referral centers with highly skilled interventionalists are required to provide these good results.<sup>53</sup>

Mediastinal node evaluation is straightforward when patients have a positive PET and/or CT scan ( $\geq 10$  mm). Noteworthy, mediastinal node evaluation is also appropriate for patients with T<sub>2/3</sub> and central T<sub>1</sub> lesions, even if the PET/CT scan do not suggest mediastinal node involvement.<sup>23,54,55</sup> In other hand, because of the low prior probability of lymph node involvement in patients with peripheral T<sub>1</sub>, clinical No

lesions, some authors do not use routine mediastinoscopy in these patients.<sup>56</sup>

Regarding adrenal nodules, it should be noted that adrenal gland nodules or masses may be found by CT in 3%–4% of patients.<sup>57–59</sup> In patients with lung cancer, most adrenal nodules are benign adenomas (fewer than half are metastasis). All adrenal lesions in patients with suspected lung cancer require direct evaluation if it will determine the disease stage. A malignant adrenal nodule is considered distant metastasis. Conventional CT and MRI imaging of adrenal lesions permits initial characterization of adrenal nodules. Protocols that measure the washout of attenuation following the administration of intravenous contrast significantly improve the sensitivity and specificity of CT for characterizing adrenal lesions.<sup>60–62</sup> PET imaging may also improve the sensitivity, specificity, and accuracy of adrenal gland imaging.<sup>63</sup>

An adrenal gland biopsy should be performed if confirmation of the adrenal pathology will determine the disease stage and treatment options. Image-guided fine needle biopsy is the most common approach.<sup>63</sup>

## STAGING SYSTEM

The TNM International Staging System provides useful prognostic information and is used to stage all patients with NSCLC. The various T (tumor size), N (regional node

involvement), and M (presence or absence of distant metastasis) are combined to form different stage groups. The 7th edition of the TNM staging system is the most recent version (Table 1).<sup>64</sup>

Four types of staging can be performed in patients with NSCLC. All are based on the TNM staging system:

1. The clinical-diagnostic stage (the focus of this review) is based upon medical history, physical examination, laboratory testing, physiologic evaluation, radiologic testing, tissue sampling, and any other investigation undertaken prior to primary therapy. It is assigned the prefix *c* (p.e. cT<sub>3</sub>N<sub>2</sub>M<sub>0</sub>).
2. The surgical-pathologic evaluation is based on the clinical-diagnostic stage plus histopathologic data from the resected tumor. It provides confirmation of the T descriptor, N descriptor, and histologic type. In addition, it takes into account the histologic grade, resection margins, and presence or absence of lymphovascular invasion. The surgical-pathologic stage is assigned the prefix *p* (p.e. pT<sub>3</sub>N<sub>2</sub>M<sub>0</sub>).
3. A retreatment stage is assigned if there is recurrence of disease and a new treatment program is planned.
4. An autopsy stage is recorded when a patient dies and has a postmortem examination performed.

Patients who may be a candidate for surgical resection of the NSCLC should undergo complete pulmonary function testing and consultation with a cardiothoracic surgeon.<sup>65</sup>

## SUMMARY

When a patient presents with suspected NSCLC, the diagnosis should be confirmed and both the histologic type and disease stage should be determined.

All patients should undergo a detailed history, CT of the neck, chest, and upper abdomen, including adrenals, complete blood count and platelets, chemistry profile, smoking cessation program (if needed), and pathology review.

Undetected mediastinal metastases are a major cause of unnecessary thoracotomies. Unnecessary thoracotomies result in suboptimal treatment, significantly impaired functional health status, and avoidable mortality. To detect mediastinal metastases, patients are routinely investigated with CT and PET, followed by mediastinal tissue staging for enlarged ( $\geq 10$  mm) or PET-positive intrathoracic nodes. However, integrated PET/CT scanning has an overall accuracy, which is too low to replace invasive intrathoracic lymph node staging. Mediastinal tissue staging is classically performed by mediastinoscopy. Current lung cancer staging guidelines acknowledge endosonography as a minimally invasive alternative to surgical staging (mediastinoscopy) to detect nodal disease. A combined endosonography investigation could be superior to mediastinoscopy staging in the detection of nodal disease (Figure 1).

Staging is based upon the TNM staging system for NSCLC (Table 1)

Disclosure: The authors declare no conflict of interest.

## REFERENCES

1. Siegel R, Ward E, Brawley O, Jemal A. Cancer statistics, 2011: the impact of eliminating socioeconomic and racial disparities on premature cancer deaths. *CA Cancer J Clin.* 2011;61:212–236.
2. Horn L, Pao W, Johnson DH. Neoplasms of the Lung. In: Longo D, Kasper D, Jameson JL, Fauci AS, Hauser SL, Loscalzo J, eds. *Harrison's Principles of Internal Medicine.* 18th ed. Mc Graw Hill Medical, 2011; pp. 737–753.
3. Hwang SJ, Cheng LS, Lozano G, Amos CI, Gu X, Strong LC. Lung cancer risk in germline p53 mutation carriers: association between an inherited cancer predisposition, cigarette smoking, and cancer risk. *Hum Genet.* 2003;113:238–243.
4. Sanders BM, Jay M, Draper GJ, Roberts EM. Non-ocular cancer in relatives of retinoblastoma patients. *Br J Cancer.* 1989;60:358–365.
5. Bailey-Wilson JE, Amos CI, Pinney SM, et al. A major lung cancer susceptibility locus maps to chromosome 6q23–25. *Am J Hum Genet.* 2004;75:460–474.
6. Bell DW, Gore I, Okimoto RA, et al. Inherited susceptibility to lung cancer may be associated with the T790M drug resistance mutation in EGFR. *Nat Genet.* 2005;37:1315–1316.
7. Herbst RS, Heymach JV, Lippman SM. Lung cancer. *N Engl J Med.* 2008;359:1367–1380.
8. Sun S, Schiller JH, Gazdar AF. Lung cancer in never smokers—a different disease. *Nat Rev Cancer.* 2007;7:778–790.
9. Spira A, Beane J, Shah V, et al. Effects of cigarette smoke on the human airway epithelial cell transcriptome. *Proc Natl Acad Sci USA.* 2004;101:10143–10148.
10. Doria-Rose VP, Szabo E. Screening and prevention of lung cancer. In: Kernstine KH, Reckamp KL, eds. *Lung cancer: a multidisciplinary approach to diagnosis and management.* New York: Demos Medical Publishing; 2010. pp. 53–72.
11. Church TR. National Lung Screening Trial Executive Committee. Chest radiography as the comparison for spiral CT in the National Lung Screening Trial. *Acad Radiol.* 2003;10:713–715.
12. Pedersen JH, Ashraf H, Dirksen A, et al. The Danish Randomized lung cancer CT screening trial—overall design and results of the prevalence round. *J Thorac Oncol.* 2009;4:608–614.
13. Lopes Pegna A, Picozzi G, Mascali M, et al. ITALUNG Study Research Group. Design, recruitment and baseline results of the ITALUNG trial for lung cancer screening with low-dose CT. *Lung Cancer.* 2009; 64:34–40.
14. Infante M, Cavuto S, Lutman FR, et al. DANTE Study Group. A randomized study of lung cancer screening with spiral computed tomography: three-year results from the DANTE trial. *Am J Respir Crit Care Med.* 2009;180:445–453.
15. Marchianò A, Calabrò E, Civelli E, et al. Pulmonary nodules: volume repeatability at multidetector CT lung cancer screening. *Radiology.* 2009;251:919–925.
16. Becker N, Delorme S, Kauczor H-U LUSI: the German component of the European trial on the efficacy of multi-slice CT for the early detection of lung cancer. *Onkologie.* 2008;31(Suppl 1):PO320. [Abstract]
17. Baldwin DR, Duffy SW, Wald NJ, Page R, Hansell DM, Field JK. UK Lung Screen (UKLS) nodule management protocol: modelling of a single screen randomised controlled trial of low-dose CT screening for lung cancer. *Thorax.* 2011;66:308–313.
18. The National Lung Screening Trial Research Team. The National Lung Screening Trial: reduced lung-cancer mortality with low-dose computed tomographic screening. *N Engl J Med.* 2011;365:395–409.
19. Brett AS. Journal Watch General Medicine. July 14, 2011.
20. Correspondence. Reduced Lung-Cancer Mortality with CT Screening. *N Engl J Med.* 2011;365:2035–2038.
21. Colice GL, Shafazand S, Griffin JP, et al. Physiologic evaluation of the patient with lung cancer being considered for resectional surgery: ACCP evidenced-based clinical practice guidelines (2nd edition). *Chest.* 2007; 132:161S–167S.

22. Ross PJ, Ashley S, Norton A, et al. Do patients with weight loss have a worse outcome when undergoing chemotherapy for lung cancers? *Br J Cancer*. 2004;90:1905–1911.
23. Colinet B, Jacot W, Bertrand D, et al. oncoLR Health Network. A new simplified comorbidity score as a prognostic factor in non-small-cell lung cancer patients: description and comparison with the Charlson's index. *Br J Cancer*. 2005;93:1098–1105.
24. NCCN Clinical Practice Guidelines in Oncology (NCCN guidelines). Non-Small Cell Lung Cancer. Version 2.2012. NCCN.org. Accessed November 9, 2011.
25. Salyer WR, Eggleston JC, Erozan YS. Efficacy of pleural needle biopsy and pleural fluid cytopathology in the diagnosis of malignant neoplasm involving the pleura. *Chest*. 1975;67:536–539.
26. Nance KV, Shermer RW, Askin FB. Diagnostic efficacy of pleural biopsy as compared with that of pleural fluid examination. *Mod Pathol*. 1991;4:320–324.
27. Prakash UB, Reiman HM. Comparison of needle biopsy with cytologic analysis for the evaluation of pleural effusion: analysis of 414 cases. *Mayo Clin Proc*. 1985;60:158–164.
28. Garcia L, Ducatman BS, Wang HH. The value of multiple fluid specimens in the cytological diagnosis of malignancy. *Mod Pathol*. 1994;7:665–668.
29. Rivera MP, Mehta AC. American College of Chest Physicians. Initial diagnosis of lung cancer: ACCP evidence-based clinical practice guidelines (2nd edition). *Chest*. 2007;132:131S–148S.
30. Milroy R. American College of Chest Physicians. New American College of Chest Physicians Lung Cancer Guidelines: an important addition to the lung cancer guidelines armamentarium. *Chest*. 2007;132:744–746.
31. Paone G, Nicastrì E, Lucantoni G, et al. Endobronchial ultrasound-driven biopsy in the diagnosis of peripheral lung lesions. *Chest*. 2005;128:3551–3557.
32. Gildea TR, Mazzone PJ, Karnak D, Mezziane M, Mehta AC. Electromagnetic navigation diagnostic bronchoscopy: a prospective study. *Am J Respir Crit Care Med*. 2006;174:982–989.
33. De Leyn P, Lardinois D, Van Schil PE, et al. ESTS guidelines for preoperative lymph node staging for nonsmall cell lung cancer. *Eur J Cardiothorac Surg*. 2007;32:1–8.
34. Deterbeck FC, Jantz MA, Wallace M, Vansteenkiste J, Silvestri GA. American College of Chest Physicians. Invasive mediastinal staging of lung cancer: ACCP evidence-based clinical practice guidelines (2nd edition). *Chest*. 2007;132(3 Suppl):202S–220S.
35. Patterson GA, Ginsberg RJ, Poon PY, et al. A prospective evaluation of magnetic resonance imaging, computed tomography, and mediastinoscopy in the preoperative assessment of mediastinal node status in bronchogenic carcinoma. *J Thorac Cardiovasc Surg*. 1987;94:679–684.
36. Gonzalez-Stawinski GV, Lemaire A, Merchant F, et al. A comparative analysis of positron emission tomography and mediastinoscopy in staging non-small cell lung cancer. *J Thorac Cardiovasc Surg*. 2003;126:1900–1905.
37. Tournoy KG, Maddens S, Gosselin R, Van Maele G, van Meerbeeck JP, Kelles A. Integrated FDG-PET/CT does not make invasive staging of the intrathoracic lymph nodes in non-small cell lung cancer redundant: a prospective study. *Thorax*. 2007;62(8):696–701.
38. Pieterman RM, van Putten JW, Meuzelaar JJ, et al. Preoperative staging of non-small-cell lung cancer with positron-emission tomography. *N Engl J Med*. 2000;343:254–261.
39. Kalf V, Hicks RJ, MacManus MP, et al. Clinical impact of (18)F fluorodeoxyglucose positron emission tomography in patients with non-small-cell lung cancer: a prospective study. *J Clin Oncol*. 2001;19:1111–1118.
40. Gould MK, Kuschner WG, Rydzak CE, et al. Test performance of positron emission tomography and computed tomography for mediastinal staging in patients with non-small-cell lung cancer: a meta-analysis. *Ann Intern Med*. 2003;139:879–892.
41. Cerfolio RJ, Ojha B, Bryant AS, Bass CS, Bartalucci AA, Mountz JM. The role of FDG-PET scan in staging patients with nonsmall cell carcinoma. *Ann Thorac Surg*. 2003;76:861–866.
42. Vansteenkiste JF, Stroobants SG, De Leyn PR, Dupont PJ, Verbeke EK. Potential use of FDG-PET scan after induction chemotherapy in surgically staged IIIa-N2 non-small-cell lung cancer: a prospective pilot study. The Leuven Lung Cancer Group. *Ann Oncol*. 1998;9:1193–1198.
43. Fischer B, Lassen U, Mortensen J, et al. Preoperative staging of lung cancer with combined PET-CT. *N Engl J Med*. 2009;361:32–39.
44. Handy JR Jr, Asaph JW, Skokan L, et al. What happens to patients undergoing lung cancer surgery? Outcomes and quality of life before and after surgery. *Chest*. 2002;122:21–30.
45. Micames CG, McCrory DC, Pavey DA, Jowell PS, Gress FG. Endoscopic ultrasound-guided fine-needle aspiration for non-small cell lung cancer staging: a systematic review and metaanalysis. *Chest*. 2007;131:539–548.
46. Gu P, Zhao YZ, Jiang LY, Zhang W, Xin Y, Han BH. Endobronchial ultrasound-guided transbronchial needle aspiration for staging of lung cancer: a systematic review and meta-analysis. *Eur J Cancer*. 2009;45:1389–1396.
47. Wallace MB, Pascual JM, Raimondo M, et al. Minimally invasive endoscopic staging of suspected lung cancer. *JAMA*. 2008;299:540–546.
48. Annema JT, Versteegh MI, Veselic M, Voigt P, Rabe KF. Endoscopic ultrasound-guided fine-needle aspiration in the diagnosis and staging of lung cancer and its impact on surgical staging. *J Clin Oncol*. 2005;23:8357–8361.
49. Tournoy KG, De Ryck F, Vanwalleghem LR, et al. Endoscopic ultrasound reduces surgical mediastinal staging in lung cancer: a randomized trial. *Am J Respir Crit Care Med*. 2008;177:531–535.
50. Harewood GC, Pascual J, Raimondo M. Economic analysis of combined endoscopic and endobronchial ultrasound in the evaluation of patients with suspected non-small cell lung cancer. *Lung Cancer*. 2010;67:366–371.
51. Annema JT, van Meerbeeck JP, Rintoul RC. Mediastinoscopy vs endosonography for mediastinal nodal staging of lung cancer: a randomized trial. *JAMA*. 2010;304:2245–2252.
52. Annema JT, Versteegh MI, Veselic M, et al. Endoscopic ultrasound added to mediastinoscopy for preoperative staging of patients with lung cancer. *JAMA*. 2005;294:931–936.
53. Deterbeck FC, Jantz MA, Wallace M, Vansteenkiste J, Silvestri GA. American College of Chest Physicians. Invasive mediastinal staging of lung cancer: ACCP evidence-based clinical practice guidelines. *Chest*. 2007;132:2025–2205.
54. Iannettoni MD. Staging strategies for lung cancer. Editorial. *JAMA*. 2010;304:20.
55. Ernst A, Eberhardt R, Krasnik M, Herth FJ. Efficacy of endobronchial ultrasound-guided transbronchial needle aspiration of hilar lymph nodes for diagnosing and staging cancer. *J Thorac Oncol*. 2009;4:947–950.
56. Rintoul RC, Tournoy KG, El Daly H, et al. EBUS-TBNA for the clarification of PET positive intra-thoracic lymph nodes—an international multi-centre experience. *J Thorac Oncol*. 2009;4:44–48.
57. Medford AR, Bennett JA, Free CM, Agrawal S. Mediastinal staging procedures in lung cancer: EBUS, TBNA and mediastinoscopy. *Curr Opin Pulm Med*. 2009;15:334–342.
58. Bovio S, Cataldi A, Reimondo G, et al. Prevalence of adrenal incidentaloma in a contemporary computerized tomography series. *J Endocrinol Invest*. 2006;29:298–302.
59. Lam KY, Lo CY. Metastatic tumours of the adrenal glands: a 30-year experience in a teaching hospital. *Clin Endocrinol (Oxf)*. 2002;56:95–101.
60. Ettinghausen SE, Burt ME. Prospective evaluation of unilateral adrenal masses in patients with operable non-small-cell lung cancer. *J Clin Oncol*. 1991;9:1462–1466.
61. Caoili EM, Korobkin M, Francis IR, et al. Adrenal masses: characterization with combined unenhanced and delayed enhanced CT. *Radiology*. 2002;222:629–633.
62. Blake MA, Kalra MK, Sweeney AT, et al. Distinguishing benign from malignant adrenal masses: multi-detector row CT protocol with 10-minute delay. *Radiology*. 2006;238:578–585.
63. Kumar R, Xiu Y, Yu JQ, et al. 18F-FDG PET in evaluation of adrenal lesions in patients with lung cancer. *J Nucl Med*. 2004;45:2058–2062.
64. Bodtger U, Vilmann P, Clementsen P, et al. Clinical impact of endoscopic ultrasound-fine needle aspiration of left adrenal masses in established or suspected lung cancer. *J Thorac Oncol*. 2009;4:1485–1489.
65. Goldstraw P, Crowley J, Chansky K, et al. The IASLC Lung Cancer Staging Project: proposals for the revision of the TNM stage groupings in the forthcoming (seventh) edition of the TNM Classification of malignant tumours. *J Thorac Oncol*. 2007;2:706–714.