

Short Communications

Contact urticaria from panthenol in hair conditioner

P. C. SCHALOCK, F. J. STORRS AND L. MORRISON

Oregon Health Sciences University, Department of Dermatology, L468, Portland, OR 97201, USA

Key words: contact urticaria; panthenol; hair conditioner; hair care products; cosmetics. © Munksgaard, 2000.

Panthenol is the alcohol corresponding to pantothenic acid, with the formula $\text{HOCH}_2\text{C}(\text{CH}_3)_2\text{CHOHCONH}(\text{CH}_2)_2\text{CH}_2\text{OH}$. It is a member of the vitamin B complex (B_5) and a component of coenzyme A. Panthenol is produced synthetically from 2,4-dihydroxy-3,3-dimethylbutyric acid and β -alanine. Common sources are food products such as liver, kidney, yeast, crude molasses, whole grain cereals, milk and rice (1). Panthenol is also a common additive to hair-care products as a conditioning agent (2).

Case Report

A 53-year-old woman, with a previous history of allergic contact dermatitis from balsam of Peru (*Myroxylon Perseae*), nickel and benzoyl peroxide, presented with an account of facial edema, erythema and pruritus within a minute after application of a new hair conditioner, *DHS Conditioner with Panthenol*. She had no shortness of breath but did have diffuse pruritus on her trunk. There was gradual improvement of her symptoms over an hour, after washing off the conditioner. She had previously used panthenol-containing hair coloring products at her hairdresser, with pruritus occurring at the hairline.

The patient was open tested on the volar forearm for 30 min with panthenol 30% pet. and to suds from a 1:5 mixture of her conditioner and water. The tests were negative. The patient was then prick tested through the panthenol and conditioner suds, as well as to histamine hydrochloride (10 mg/ml) and saline solution (0.9%) as positive and negative controls, respectively. Pruritus and erythema began 2 min after pricking and wheals formed within 5 min. After 20 min, the wheals were read as: panthenol, 3+, DHS Conditioner suds, 1+, according to the rating system described by Kanerva et al. (3). The histamine reaction was equal to the panthenol reaction and the saline was completely negative at 30 min after pricking. The pa-

tient discontinued usage of panthenol-containing conditioner after the 1st episode described above.

We spoke with the patient 1 month after prick testing. She reported pruritus and swelling at the hairline after her hairdresser again used panthenol-containing hair coloring. She had had no other urticarial reactions since that episode.

Discussion

Although there have been no previous reports of contact urticaria from panthenol, contact urticaria from hair conditioners has been reported previously from hydroxypropyl trimonium hydrolyzed collagen (Crotein Q) (4, 5) and to hydrolyzed proteins (6). Panthenol, as a coenzyme constituent derived from β -alanine, could be acting in the same manner as Crotein Q, thus causing contact urticaria.

References

1. Lewis R J Sr. *Hawley's condensed chemical dictionary*, 12th edition. New York: Van Nostrand Reinhold, 1993.
2. Weninger J A, McEwen G N, Jr. *International cosmetic ingredient dictionary and handbook*, 7th edition. Washington: Cosmetic, Toiletry and Fragrance Association, 1997.
3. Kanerva L, Estlander T, Jolanki R. Skin testing for immediate hypersensitivity in occupational allergology. In: Menné T, Maibach, H I (eds): *Exogenous dermatoses: environmental dermatitis*, 1991: 103–126.
4. Freeman S, Lee M S. Contact urticaria to hair conditioner. *Contact Dermatitis* 1996; 35: 195–196.
5. Niinimäki A, Niinimäki M, Mäkinen-Kiljunen S, Hanuksela M. Contact urticaria from protein hydrolysates in hair conditioners. *Allergy* 1998; 53: 1078–1082.
6. Pasche-Koo F, Claes M, Hauser C. Contact urticaria with systemic symptoms caused by bovine collagen in a hair conditioner. *Am J Contact Dermat* 1996; 7: 56–57.

Allergic contact dermatitis due to diphenylthiourea in a neoprene slimming suit

MANUEL ALCÁNTARA¹, JORGE MARTÍNEZ-ESCRIBANO², JOSÉ FRÍAS² AND FRANCISCO JAVIER GARCÍA-SELLÉS¹

¹Allergy Department, Virgen de la Arrixaca University Hospital, Ctra Madrid-Cartagena s/n, 30120 El Palmar (Murcia), Spain

² Dermatology Department, Virgen de la Arrixaca University Hospital, Murcia, Spain

Key words: rubber; neoprene; thioureas; diphenylthiourea; allergic contact dermatitis; cross-sensitivity; slimming suit; lack of cross-sensitivity. © Munksgaard, 2000.

Thioureas compounds are potential contact allergens used as accelerators in rubber vulcanization, especially of neoprene (1).

Case Report

A 51-year-old woman, with a previous history of asthma and rhinitis, developed a pruritic erythematovesicular eruption on the upper thighs and buttocks, after wearing a Vulkan[®] neoprene slimming suit (Fig. 1). The results of patch tests with a standard series, a rubber chemical series (including thiourea derivatives) and a piece of neoprene fabric from the slimming suit are summarized in Table 1.

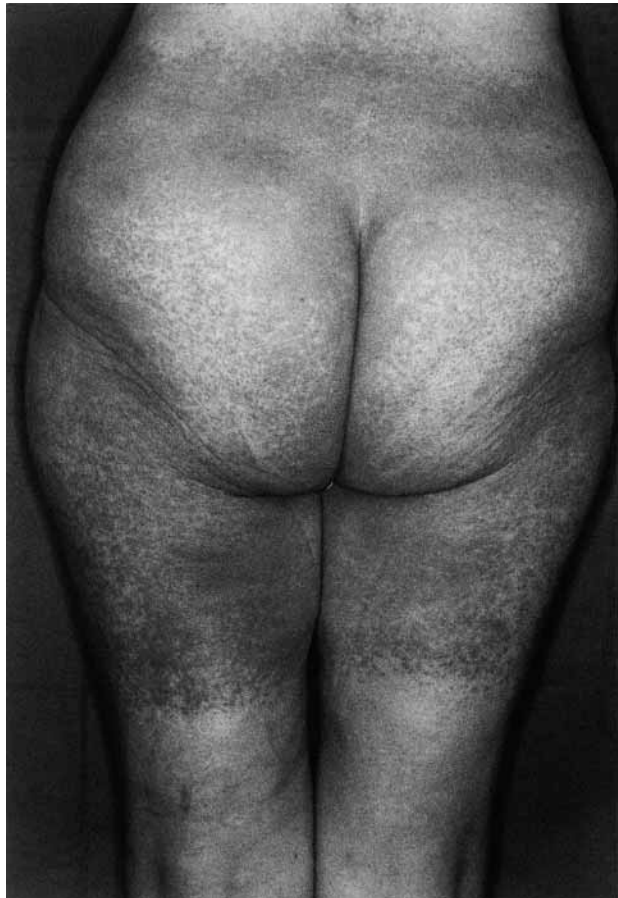

Fig. 1. Allergic contact dermatitis from diphenylthiourea in a neoprene slimming suit.

Table 1. Patch test results

	D2	D4
<i>Standard series</i>		
carba mix	++	++
methylchloroisothiazolinone+ methylisothiazolinone	++	++
<i>Rubber chemical series</i>		
diphenylthiourea	+++	+++
diethylthiourea	-	-
dibutylthiourea	-	-
<i>Neoprene slimming suit</i>		
	+++	+++

Discussion

Sensitization to diphenylthiourea has previously been reported (2), and substituted thioureas as a cause of occupational allergic dermatoses are well documented (3, 4). Neoprene has been the source of sensitization to thiourea compounds in wetsuits, swimming goggles, gloves, shoes and orthopedic devices (4–7). Others products that may contain, or break down into, thiourea compounds are: polyvinyl chloride (PVC) plastic or adhesive, diazo paper, paint or glue removers, anticorrosive agents and certain pesticides. Ikarashi et al. (8) assessed 4 thioureas for their sensitization potential, demonstrating diphenylthiourea to have the highest.

In accordance with other publications (7, 9, 10), no cross-reactions to diethylthiourea and dibutylthiourea were observed in our patient. Patients suspected of contact dermatitis from neoprene need, therefore, to be tested with several substituted thioureas separately.

References

1. Dooms-Goossens A, Chrispeels M T, De Veyder H, Roelands R, Willems L, Degreef H. Contact and photocontact sensitivity problems associated with thiourea and its derivatives: a review of the literature and case-reports. *Br J Dermatol* 1987; 116: 573–579.
2. Fregert S, Trulsson L, Zimerson E. Contact allergic reactions to diphenylthiourea and phenylisothiocyanate in PVC adhesive tape. *Contact Dermatitis* 1982; 8: 38–42.
3. Meding B, Baun H, Bruze M, Roupe G, Trulsson L. Allergic contact dermatitis from diphenylthiourea in Vulkan heat retainers. *Contact Dermatitis* 1990; 22: 812.
4. Kanerva L, Estlander T, Jolanki R. Occupational allergic contact dermatitis caused by thiourea compounds. *Contact Dermatitis* 1994; 31: 242–248.
5. Wilson H T H. Rubber dermatitis. An investigation of 106

- cases of contact dermatitis caused by rubber. *Br J Dermatol* 1969; 81: 175–179.
6. Romaguera C, Grimalt F, Vilaplana J, Castel T. Contact dermatitis to thioureas. *Contact Dermatitis* 1988; 18: 175–176.
 7. Villareal Balza De Vallejo O. Contact dermatitis from diphenylthiourea in a knee brace. *Contact Dermatitis* 1997; 36: 166–167.
 8. Ikarashi Y, Ohno K, Momma J, Tsuchina T, Nakamura

- A. Assessment of contact sensitivity of 4 thiourea rubber accelerators: comparison of 2 mouse lymph node assays with the guinea pig maximization test. *Food Chem Toxicol* 1994; 32: 1067–1072.
9. Adams R M. Contact allergic dermatitis due to diethylthiourea in a wetsuit. *Contact Dermatitis* 1982; 8: 277–278.
10. Reid C M, Van Grutten M, Rycroft R J G. Allergic contact dermatitis from ethylbutylthiourea in neoprene. *Contact Dermatitis* 1993; 28: 193.

Occupational contact dermatitis from diethylene glycol monobutyl ether in a podiatrist

SIBYLLE SCHLIEMANN-WILLERS, ANDREA BAUER AND PETER ELSNER

Department of Dermatology and Allergology, Friedrich Schiller University Jena, Erfurter Str. 35, 07740 Jena, Germany

Key words: Carbitols; diethylene glycol monobutyl ether; glycols; delayed hypersensitivity; airborne; allergic contact dermatitis; occupational; disinfectants. © Munksgaard, 2000.

Case Report

A 37-year-old podiatrist presented newly with acute dyshidrotic hand dermatitis. Sick leave led to resolution of symptoms 3×, while re-exposure to disinfectants and foot-care products at the workplace resulted in relapse. After some months, the patient complained of itching and swelling of the face after work and developed mild eczema of the face and flexures. She had a history of jewellery intolerance, but not of flexural eczema, seasonal rhinitis or asthma. Her son had flexural eczema.

Patch tests were carried out with the European standard, disinfectants, and ointments series and with her own products, including a disinfectant used regularly for instrument disinfection by the patient, without always wearing gloves. Test substances were applied with Finn Chambers® for 2 days, and reactions were evaluated at 2 and 3 days (D) according to the recommendations of the DKG. During patch testing, the patient was on sick leave and her hand dermatitis had improved considerably.

Positive reactions were found only to nickel sulfate at D4 and D3 ((+)/++) and to the instrument disinfectant 0.1% aq. at D3 (0/+). No positive reaction occurred to the disinfectant 0.01% aq. Additional patch testing with the ingredients of the instrument disinfectant showed positive reactions to diethylene glycol monobutyl ether (DGBE) 1% aq. D3 and D4 (?+/+/+). While being patch tested, the patient complained of itch, and a slight flare-up of the hand dermatitis was seen. An atopy prick test was negative. Patch tests with DGBE 1% and 0.1% aq. in 10 control persons were negative at D2, D3 and D4.

Discussion

DGBE is one of the organic solvents known as Carbitols, which are common ingredients of water-based

paints, liquid hard surface cleaners, polishes, and disinfectants. Reports of delayed sensitivity to these compounds are very rare (1), and predictive animal assays showed no delayed-type hypersensitivity to several glycol ethers (2). Dawson et al. (3) first described delayed hypersensitivity in a man who worked with printing inks, and Berlin et al. (4) reported allergic contact dermatitis on the face that occurred after renovation and painting of wallpaper with water-based paint. Involvement of the face in our patient may also be explained by DGBE vapor (5). Hand eczema in a housewife due to a cosmetic cream containing ethyl diglycol, another Carbitol, has recently been reported by Pereira et al. (6).

In our patient, regular use of instrument disinfection containing DGBE was identified as responsible for occupational contact dermatitis of the hands. Since the patient changed her job several months ago, the hand dermatitis has resolved completely.

References

1. Cronin E. *Contact dermatitis*. Edinburgh, London, New York: Churchill Livingstone, 1980: 809–813.
2. Zissu D. Experimental study of cutaneous tolerance to glycol ethers. *Contact Dermatitis* 1995; 32: 74–77.
3. Dawson T A J, Black R J, Strang W C, Millership J S, Davies I. Delayed and immediate hypersensitivity to Carbitols. *Contact Dermatitis* 1989; 21: 52–53.
4. Berlin K, Johanson G, Lindberg M. Hypersensitivity to 2-(2-butoxyethoxy) ethanol. *Contact Dermatitis* 1995; 32: 54.
5. Gibson W B, Keller P R, Foltz D J, Harvey G J. Diethylene glycol monobutyl ether (DGBE) concentrations in room air from application of cleaner formulations to hard surfaces. *J Expo Anal Environ Epidemiol* 1991; 1: 369–383.
6. Pereira F, Pereira C, Lacerda M H. Contact dermatitis to a cream containing chitin and a Carbitol. *Contact Dermatitis* 1998; 38: 290–291.

A case of contact hypersensitivity to platinum salts

E. DASTYCHOVÁ AND V. SEMRÁDOVÁ

1st Department of Dermatology and Venereology, St. Anne's University Hospital Brno, Pekařská 53, 656 91 Brno, Czech Republic

Key words: platinum salts; allergic contact dermatitis; cis-platinum; cisplatin; occupational; chemical process worker; pharmaceutical manufacture; antineoplastics. © Munksgaard, 2000.

A 42-year-old process worker in the manufacture of cis-platinum presented with a widespread papular eczema. 1 year previously, an eczema had begun on the neck and spread to the hands, forearms, and then gradually more widely. He would repeatedly improve on sick-leave, with topical corticosteroids, only to relapse within 2–3 days of returning to work. He had eventually developed a generalized erythroderma. He had no previous personal or family history of atopy.

Patch tests with the European standard series (Trolab) were negative. The following additional substances from his workplace were tested: K [Pt(NH₃)Cl₃] (potassium trichloroamine-platinate) 0.1% aq.; K₂PtCl₄ (potassium tetrachloroplatinate) 0.1% aq.; trans(-)-1,2-diaminocyclohexane-Pt(COO)₂ (oxaliplatin) 0.1% aq. Leukotest (Beiersdorf) units were used, with an application time of 1 day, and additional readings at 2, 3 and 4 days. The tests were positive to all 3 platinum compounds (Table 1). The dermatitis was reported as occupational.

Discussion

Metallic platinum, as used in jewellery, photography, dentistry, and the chemical and electrical industries, rarely contact sensitizes (3, 4, 6, 7).

Soluble platinum salts more commonly cause Type I hypersensitivity reactions than Type IV, allergic rhinitis, conjunctivitis, bronchial asthma or urticaria being referred to as platinosis. Persons with an atopic personal or family history are considered more susceptible to platinosis (3, 5). Respiratory allergy caused by platinum compounds has been reported by others (1, 2, 8, 9), and is more common in smokers (1).

Jirásek & Kalenský (5) reported contact hypersensitivity to platinum compounds in 1975, presenting among employees of a rare metals refinery with confluent maculopapular exanthemas and moderate oedema of the vo-

lar forearms, backs of the hands and, more rarely, the face, neck and décolleté.

Platinum salts show varying immunogenicity (10), hexa- and tetrachloroplatinates being the most potent. Cis-platinum (cisplatin) is an intravenously administered antineoplastic drug, which has been described as a cause of occupational contact *urticaria* (11).

References

1. Baker D B, Gann P H, Brooks S M, Gallagher J, Bernstein I L. Cross-sectional study of platinum salts sensitization among precious metals refinery workers. *Am J Ind Med* 1990; 18: 53–64.
2. Bolm-Audorff U, Bienfait H G, Burkhard J, Bury A H, Merget R, Pressel G, Schultze-Werninghaus G. Prevalence of respiratory allergy in a platinum refinery. *Int Arch Occup Environ Health* 1992; 64: 257–260.
3. Fisher A A. *Contact dermatitis*, 3rd edition. Philadelphia: Lea & Febiger, 1986: 734.
4. Flint G N. A metallurgical approach to metal contact dermatitis. *Contact Dermatitis* 1998; 39: 213–221.
5. Jirásek L, Kalenský J. Přecitlivělost na platinu, rhodium, zlato, měď, antimon a jiné vzácné kovy a profesionální dermatitidy způsobené selénem. *Čs Derm* 1975; 49: 361–368.
6. Kansu G, Aydin A K. Evaluation of the biocompatibility of various dental alloys. Part 2: Allergenic potentials. *Eur J Prosthodont Restor Dent* 1996; 4: 155–161.
7. Koch P, Baum H P. Contact stomatitis due to palladium and platinum in dental alloys. *Contact Dermatitis* 1996; 34: 253–257.
8. Merget R, Caspari C, Kulzer R, Breitstadt R, Rueckmann A, Schultze-Werninghaus G. The sequence of symptoms, sensitization and bronchial hyperresponsiveness in early occupational asthma due to platinum salts. *Int Arch Allergy Immunol* 1995; 107: 406–407.
9. Niezborala M, Garnier R. Allergy to complex platinum salts: a historical prospective cohort study. *Occup Environ Med* 1996; 53: 252–257.
10. Schuppe H C, Kulig J, Kuhn U, Lempertz U, Kind P, Knop J, Becker D. Immunostimulatory effects of platinum compounds: correlation between sensitizing properties in vivo and modulation of receptor-mediated endocytosis in vitro. *Int Arch Allergy Immunol* 1997; 112: 125–132.
11. Schena D, Barba A, Costa G. Occupational contact urticaria due to cisplatin. *Contact Dermatitis* 1996; 34: 220–221.

Table 1. Positive patch tests to platinum salts

	D1	D2	D3	D4
K[Pt(NH ₃)Cl ₃]	+	+++	+++	+++
K ₂ PtCl ₄	+	++	+++	+++
trans(-)-1,2-dach*-Pt(COO) ₂ (oxaliplatin)	++	+++	+++	+++

* dach=diaminocyclohexane.

A series of 3 patients sensitized to reactive dyes during patch testing

S. SOMMER AND S. M. WILKINSON

Department of Dermatology, Leeds General Infirmary, Great George Street, Leeds LS1 3EX, UK

Key words: clothing; allergic contact dermatitis; reactive dyes; active sensitization; patch-testing technique. © Munksgaard, 2000.

In July 1999, additional textile allergens, including 8 reactive dyes, became commercially available. Between July 1999 and February 2000, we patch tested 99 patients suspected of having a clothing dermatitis to this series, 3% of whom became sensitized as a result of the patch test.

Case Reports

Case no. 1

A 9-year-old boy was referred with worsening eczema for more than 4 years. In addition to mild flexural eczema and discoid lesions on the trunk and limbs, the perineum, thighs and midriff were involved. Patch testing was initially performed to standard, medicaments and textiles series, with no positive reactions on day (D) 2 and 4. A diagnosis of atopic eczema was made. He returned after 4 weeks with 2 late reactions and was retested to part of the standard and textiles series, with the following positive reactions on D2 and 4: nickel sulfate 5% petrolatum (pet.) +/+, PTBP-formaldehyde resin 1% pet. +/++ and Reactive Black 5 5% pet. -/+, the last 2 corresponding to the position of the late reactions.

Case no. 2

A 21-year-old barmaid presented with a 3-month history of eczema after the birth of her baby, initially localized to her axillae, but then widespread. There was a past history of asthma and hand eczema and also a family history of atopy. She was patch tested to standard, textiles and face series, with a positive reaction to sodium fusidate 2% pet. +/+ at D2 and 4. This was considered to be of past relevance. She returned after 4 weeks with several late reactions and was patch tested to part of the face and textiles series, with the following reactions on D2 and 4: Reactive Black 5 +/++, Reactive Blue 21 +/++, Reactive Blue 238 +/++, Reactive Orange 107 +/++, Reactive Red 244 +/+, all 5% pet., and phosphorus sesquisulfide 1% pet. -/+.

Case no. 3

An 18-year-old presented with late onset papular lichenified eczema, without a personal or family history of atopy. She was patch tested to standard, textiles and finger tip series, with positive reactions at D2 and 4 to nickel sulfate 5% pet. +/+++ and cobalt chloride 1% pet. +/+++ . After 6 weeks, she was referred back with 5 late reactions to Reactive Blue 21, Blue 238, Orange

107, Red 244 and Violet 5, all 5% pet. Further testing was not performed.

Discussion

For the past 40 years, reactive dyes have been increasingly used because of their wetfastness to colour natural textile fibres. Occupational respiratory symptoms have mainly been reported, including 1 fatal asthma attack, but skin symptoms have been thought to be rare (1, 2). Urticaria, and irritant and allergic contact dermatitis have, however, been described (3–6). Non-occupational sensitization was thought to be unlikely because the dyes became ionized and fixed on the finished garment. Then, a series of 1813 patch-tested patients identified 18 sensitized patients in Italy, only 1 of whom had occupational exposure (7). 2 of the 4 patients patch tested to pieces of clothing reacted positively. However, even in our selected group of patients suspected of having clothing dermatitis, no reactions to reactive dyes could be detected prior to sensitization during patch testing. The prevalence and relevance of contact hypersensitivity to reactive dyes outside Italy has recently been questioned (8).

Until recently, reactive dyes were not commercially available as part of a patch testing series. In July 1999, 5% pet. dilutions of Reactive Black 5, Blue 21, Blue 238, Orange 107, Red 123, Red 228, Red 224 and Violet 5 became available as part of a textiles series. These dilutions are capable of sensitizing patients during patch testing, as evidence by our series of 3 patients out of 99 tested. A lower dilution of 1% pet. was previously recommended and should be safer (5). However, further patch testing will be needed to confirm a dilution as sufficient to elicit reactions without inducing sensitization.

References

1. Stern M A. Occupational asthma from a reactive dye. *Annals of Allergy* 1985; 55: 264.
2. Docker A, Wattie J M, Nordlinger R, Belin L. Contact dermatitis and asthma from reactive dyes. *Contact Dermatitis* 1986; 15: 186–193.
3. Thoren K, Mending B, Nordlinger R, Belin L. Contact dermatitis and asthma from reactive dyes. *Contact Dermatitis* 1986; 15: 186.
4. Alanko K, Keskinen H, Björkstén F, Ojanen S. Immediate-type hypersensitivity to reactive dyes. *Clin Allergy* 1987; 25–31.
5. Estlander T. Allergic dermatoses and respiratory diseases from reactive dyes. *Contact Dermatitis* 1988; 18: 290–297.
6. Wilkinson S M, McGeachan K. Occupational allergic con-

tact dermatitis from reactive dyes. *Contact Dermatitis* 1996; 35: 376.

7. Manzini B M, Motolese A, Conti A, Ferdani G, Seidenari S. Sensitisation to reactive textile dyes in patients with

contact dermatitis. *Contact Dermatitis* 1996; 34: 172–175.
8. Hatch K L, Maibach H I. Textile dye allergic contact dermatitis prevalence. *Contact Dermatitis* 2000; 42: 189–195.

The role of nickel in oral disease[#]

G. DAWN*, G. GUPTA AND A. FORSYTH

Department of Dermatology, Contact Dermatitis Investigation Unit, Royal Infirmary, Castle Street, Glasgow, UK

Key words: nickel; oral disease; patch tests; contact allergy, lack of relevance © Munksgaard, 2000.

The aims of this study were to analyze the patch test results of patients with oral disease, to assess whether nickel was a major allergen (1).

Patients and Methods

All patients with oral disease who had been patch tested in a 12-month period were identified. Prior to patch testing, a full history including patient demographics (MOAHL) and symptoms was recorded. Patch-test results, including number and nature of allergens, were noted.

Patch tests were carried out by applying standardized allergens, in Finn Chambers[®] secured with Scanpor[®] tape, on the upper back. An additional dental series was applied in patients with oral disease. Tests were performed according to ICDRG guidelines and read at 2 and 4 days by the same investigator.

Results

In 1997, 860 patients in total were patch tested. 137 patients (16%) had oral disease and, of these, 23 (17%) had a positive patch-test reaction to nickel. Table 1 shows their demographics. There were many more females in the nickel-positive group and the mean age at presentation was slightly higher than in the nickel-negative group. Duration of disease in both groups was comparable. Oral disease was not related to occupation, hand dermatitis or leg ulceration, in any of the patients. Atopy was present in approximately 25% of patients from both groups.

Of the 137 patients, 77 (56%) had previous dental work: in the nickel-positive group, 20 of 23 (87%) patients did, as opposed to 57 out of 114 (50%) nickel-negative patients. Table 2 lists the features at presentation and shows that oral ulceration and pain were the commonest. In the nickel-positive group, 52% of patients had oral ulceration and/or oral pain.

[#] Presented as a poster at the 58th Annual Meeting of the American Academy of Dermatology in San Francisco, March 2000.

* Address for correspondence: Department of Dermatology, Monklands Hospital, Airdrie, Lanarkshire ML6 0JS, UK

Of the 137 patients with oral disease, 120 (88%) gave a positive patch test. Of these, 37 (31%) had 1 positive reaction, 31 (26%) 2, and 52 (43%) 3 or more. Table 3 lists the allergens and shows that 23 patients (17%) gave a positive reaction to nickel, though, of these, only 2 had a positive reaction to nickel alone, whilst the rest had reactions to 1 or more allergens besides nickel.

Discussion

In a 12-month period, 16% of patients were referred with oral disease. There was a high female ratio in the nickel-positive group, probably reflecting the increased female preponderance in patients with allergic contact derma-

Table 1. Demographics of 137 patients with oral disease referred for patch testing

Patient demographics	Nickel-positive group (n=23)	Nickel-negative group (n=114)
no. patients	23 (17%)	114 (83%)
male: female ratio	1:22	1:1.7
mean age (years)	49	37.9
age range (years)	25–67	3–76
mean duration of symptoms (years)	6.7	5.6
duration of symptoms (range in years)	0.5–30	0.5–43

Table 2. Presenting features in patients with oral disease

Feature*	Nickel-positive group (n=23)	Nickel-negative group (n=114)
oral ulceration	12	42
oral pain	12	45
bleeding from oral mucosa	10	5
oral redness	9	11
burning mouth	5	17
oral discomfort	4	7
oral swelling	2	22
dermatitis around mouth	2	7
fissures	1	9
metallic taste	1	0

*Patients may present with more than 1.

Table 3. 147 allergic reactions in 120 patients with positive patch tests

Allergen	No. patients
fragrances/balsam	31
mercury	24
nickel	23
parabens	9
cobalt	7
gold	6
rubber accelerators	6
colophonium	6
topical antibacterials	6
palladium	4
organic mercurials	2
chromate	1
others	22

titis from nickel (1). Oral ulceration and oral pain were the commonest presenting features. However, there was no significant difference between the nickel-positive and -negative groups.

Patients with a positive reaction to nickel were more likely to have had previous dental work. The 3 main allergens noted were fragrance, mercury (2) and nickel, the 1st perhaps reflecting the high prevalence of allergic contact dermatitis from fragrance in our patch-test

population (1). 17% of patients with oral disease had a positive reaction to other allergens in addition to nickel, with only 2 developing a positive reaction to nickel alone.

As the prevalence of allergic contact dermatitis from nickel in our general patch test population in the same year was 22% (1), the % in patients with oral disease probably reflects the background prevalence of allergic contact dermatitis from nickel. Unlike previous studies, there were not many positive reactions to either gold or palladium (3). We conclude that nickel alone does not play a major rôle in oral disease.

References

1. Dawn G, Gupta G, Forsyth A. The trend of nickel allergy from a Scottish tertiary referral centre. *Contact Dermatitis* 2000; 43: in press.
2. Alanko K, Kanerva L, Jolanki R, Kannas L, Estlander T. Oral mucosal diseases investigated by patch testing with a dental screening series. *Contact Dermatitis* 1996; 34: 263–267.
3. Marcusson J A. Contact allergies to nickel sulfate, gold sodium thiosulfate and palladium chloride in patients claiming side-effects from dental alloy components. *Contact Dermatitis* 1996; 34: 320–322.

Photoallergic eczema caused by sunscreens in a 12-year-old girl

A. PÉREZ FERRIOLS AND A. ALIAGA BONICHE

Department of Dermatology, University General Hospital, Avda. Tres Cruces s/n, Valencia, Spain

Key words: photoallergic contact dermatitis; sunscreens; children; cosmetics; octyl methoxycinnamate; butyl methoxydibenzoylmethane. © Munksgaard, 2000.

The most frequent photosensitive diseases in children generally comprise genodermatoses or processes of unknown etiology (1). Photocontact eczemas are infrequent in this age group.

Case Report

A 12-year-old girl presented with a pruriginous micropapular eruption on the arms and legs. She had been exposed to the sun, after application of a chemical sunblock, 2 days earlier. Skin biopsy showed spongiosis with a superficial lymphocytic infiltrate.

Photopatch testing was performed with the Spanish Photobiology Group sunscreens series (Martí Tor[®]), and the product used by the patient (Nenuco[®] sun cream). A PUVA 500 (Herbert Waldmann, Germany) lamp was used, irradiating for 30 min (9 J/cm²). Positivity was recorded, only on the irradiated side, to ketoprofen 2.5% pet. ++, octyl methoxycinnamate 7.5% pet. ++, butyl methoxydibenzoylmethane 2% pet. ++, and Nenuco[®]

sun cream as is ++. The latter contains both octyl methoxycinnamate and butyl methoxydibenzoylmethane.

After changing to physical sunblocks, the patient remains free of lesions after 3 years of follow-up.

Comment

Photocontact dermatitis due to sunscreens or other allergens is only rarely observed in children. Ferguson (1) described 7 cases of photocontact reactions out of a total of 474 children with photosensitive diseases over a 20-year period. Chemical sunscreens have meanwhile become one of the most frequent causes of photocontact dermatitis (2), and in view of the now widespread use of these products in all age groups, the frequency of allergic reactions in children may be expected to increase.

We are uncertain of the relevance of the ketoprofen patch test positivity in our patient. She and her mother denied the use of non-steroidal anti-inflamma-

tory drugs. Although cross-reactions have been described between ketoprofen and the oxybenzones (3), due to the presence of a common benzoylacetone ring, the chemical formula of ketoprofen and the sunscreen agents responsible for the lesions in our patient appear to bear no similarity.

References

1. Ferguson J. Investigation of the photosensitive child. *Ped Dermatol* 1992; 9: 348–350.
2. De Leo V A, Harber L. Contact photodermatitis. In: *Fisher's contact dermatitis*, 4th edition. Baltimore. Williams and Wilkins, 1995.
3. Leroy D et al. Photodermatitis from ketoprofen with cross-reactivity to fenofibrate and benzophenones. *Photodermatol Photoimmunol Photomed* 1997; 13: 93–97.

Occupational contact urticaria syndrome from cefotiam dihydrochloride in a latex-allergic nurse

HIDEYUKI MIYAKE¹, YOHICHI MORISHIMA¹ AND SABURO KISHIMOTO²

¹Department of Dermatology, Matsushita Memorial Hospital, 5-55 Sotojima-cho, Moriguchi-shi, Osaka 570-8540

²Department of Dermatology, Kyoto Prefectural University of Medicine, Kawaramachi Hirokoji, Kamigyo-ku, Kyoto 602-0841, Japan

Key words: cefotiam dihydrochloride; natural rubber latex; contact urticaria syndrome; scratch test; nurse; health care workers; cephalosporins; antibiotics; occupational © Munksgaard, 2000.

Drugs (1), as well as natural rubber latex (NRL) (2), are known causes of contact urticaria syndrome. NRL-allergic patients may cross-react with fruits (3).

Case Report

A 28-year-old nurse had had atopic dermatitis of the hands and had worked in the surgical section of our hospital for over 8 years. She experienced whealing on her hands while preparing a solution of cefotiam hydrochloride (CTM) in March 1999. 1 week later, she developed urticaria first on her hands and then progressing to generalized whealing with nausea, vomiting, and abdominal pain while carrying out the same work. She made a rapid recovery after symptomatic treatment. She also had a history of itching on the hands after wearing NRL gloves.

Scratch tests were positive to both CTM and latex gloves (Table 1), though open tests were negative to both. Intradermal tests were also positive to cefazolin and sulbactam/cefoperazone, seemingly due to cross-sensitivity. Specific IgE to latex (Pharmacia CAP) was elevated at 1.84 UA/ml, but specific IgEs to chestnut, kiwi, mango, banana, avocado, peanut, tomato, potato and silver birch were all within normal limits.

Discussion

Among drugs, CTM has been the only reported cause of contact urticaria syndrome (4, 5) in recent years in Japan (6–9). In our case, the patient also had contact urticaria due to NRL, which has frequently been associated with allergic hand eczema (10). Although no elevated titers of specific IgE to cross-reacting fruits (11–13)

Table 1. Results of skin tests

Antibiotics and materials	Concentration ($\mu\text{g/ml}$)	Open test	Scratch test	Intradermal test
CTM	300	–	+	ND
	30	–	+	ND
CEZ	300	ND	–	+
SBT/CPZ	300	ND	–	+
FMOX	300	ND	–	–
PIPC	300	ND	–	–
IPM	300	ND	–	–
CS	300	ND	–	–
latex glove (as is)		–	+	ND
the extract solutions of latex glove		–	–	ND
control: saline		–	–	–

CTM: cefotiam dihydrochloride, CEZ: cefazolin sodium, SBT/CPZ: sulbactam sodium/cefoperazon sodium, FMOX: flomoxef sodium PIPC: piperacillin sodium, IPM: imipenem, CS: cilastatin sodium.

were found, we recommended that the patient should avoid eating such fruits.

This is the first reported case of contact urticaria syndrome due to the dual antigens CTM and NRL.

References

1. Fisher A A. *Contact dermatitis*, 3rd edition. Philadelphia: Lea & Febiger, 1986: 686–709.
2. Slater J E. Latex allergy. *J Allergy Clin Immunol* 1994; 94: 139–149.
3. Blanco C, Carrillo T, Castillo R, Quiralte J, Cuevas M. Latex allergy: clinical features and cross-reactivity with fruits. *Annals of Allergy* 1994; 73: 309–314.
4. Maibach H I, Johnson H L. Contact urticaria syndrome. *Arch Dermatol* 1975; 111: 726–730.
5. Von Krough G, Maibach H I. The contact urticaria syndrome – an update review. *J Am Acad Dermatol* 1981; 5: 328–342.
6. Miyahara H, Imayama S, Koga T, Tanahashi T, Hori Y. Occupational contact urticaria syndrome from cefotiam hydrochloride. *Contact Dermatitis* 1993; 29: 210–211.
7. Tadokoro K, Niimi N, Ohtoshi T, Nakajima K, Takafuji S, Onodera K, Suzuki S, Muranaka M. Cefotiam-induced IgE-mediated occupational contact anaphylaxis of nurse; case reports, and a review of the literature. *Clin Exp Allergy* 1994; 24: 127–133.
8. Mizutani H, Ohyanagi S, Shimizu M. Anaphylactic shock related to occupational handling of Cefotiam dihydrochloride. *Clin Exp Dermatol* 1994; 19: 449.
9. Shimizu S, Chen K R, Miyakawa S. Cefotiam-induced contact urticaria syndrome: an occupational condition in Japanese nurses. *Dermatology* 1996; 192: 174–176.
10. Taylor J M, Praditsuwan P. Latex allergy: review of 44 cases including outcome and frequent association with allergic hand eczema. *Arch Dermatol* 1996; 132: 265–271.
11. Yagami T, Michio S, Akitada N, Mamiko S. One of the rubber latex allergens is a lysozyme. *J Allergy Clin Immunol* 1995; 96: 677–696.
12. Garcia Ortiz J C, Alvarez M, Bellido J. Latex allergy in fruit-allergic patients. *Allergy* 1998; 53: 532–536.
13. Hayakawa R, Sugiura M, Tanaka S, Miyachi Y, Kanbe N, Horio T, Mituya K, Ichihashi M, Bito T, Shimizu R, Nakamura T, Higashi N, Natuaki M, Ito M, Takahashi K, Nishioka K, Shimada S, Tsukamoto K, Ikezawa Z, Osuna H, Kaniwa M. Group study on latex allergy. *Environ Dermatol* 1999; 6: 10–16.

Contact allergy to doxepin

DEIRDRE A. BUCKLEY

Department of Dermatology, Ealing Hospital, Uxbridge Road, Middlesex UB1 3HW, UK

Key words: allergic contact dermatitis; doxepin; antihistamines; medicaments. © Munksgaard, 2000.

A 59-year-old Indian man was prescribed 5% doxepin cream (Xepin[®], Bioglan Laboratories Ltd.) for a pruritic rash on the feet. Within 3 weeks, the eruption became generalized and he developed painful swelling of the legs such that he was unable to walk. His symptoms resolved on discontinuing treatment.

Patch testing to the European standard series and to doxepin cream showed a ++ reaction at D4 to the cream. In addition, he had positive reactions to lanolin and p-phenylenediamine, not thought to be of current relevance. The results of further testing to the constituents of the cream, which was carried out 6 months later,

are summarized in Table 1. Patch testing of 20 control patients to 5% doxepin cream was negative.

Comment

Doxepin cream has been marketed in the UK for the last 2 years for the treatment of itch associated with eczema and specifically for contact dermatitis. Recently, a case of allergic contact dermatitis from doxepin has been reported in the UK (1), where the Committee on Safety of Medicines has now received a total of 5 reports of contact allergy to doxepin cream (including this present case). In North America, where doxepin has been licensed since April 1994, a high incidence of contact sensitization has been reported following its use for periods of several days to 1 year (2). Several case reports of doxepin allergy have also been published (3–5).

Historically, topical antihistamines have been avoided for the treatment of itch because of the high incidence of allergic contact dermatitis (3). Doxepin is a dibenzoxepin tricyclic drug with antihistamine activity, blocking both H1 and H2 receptors. Premarketing surveillance studies suggested the incidence of sensitization to topical doxepin was very low, but the trials were for 7 days only and no patch tests were carried out after exposure (3).

Table 1. Patch test results with Xepin[®] cream and its constituents (all pet.)

	D2	D4
Xepin [®] cream (as is)	–	++
5% doxepin hydrochloride	+++	+++
1% doxepin hydrochloride	+++	+++
0.5% doxepin hydrochloride	+++	+++
0.1% doxepin hydrochloride	++	++
0.05% doxepin hydrochloride	++	++
0.01% doxepin hydrochloride	–	–
other excipients of Xepin [®] cream	–	–

The appropriate patch test concentration for doxepin hydrochloride is not known, but in previous cases, positive reactions were seen with concentrations as low as 0.5% (1, 6). In this case, a positive response was seen with concentrations down to 0.05%.

References

1. Wakelin S H, Rycroft R J G. Allergic contact dermatitis from doxepin. *Contact Dermatitis* 1999; 40: 214.
2. Taylor J S, Praditsuwan P, Handel D, Kuffner G. Allergic contact dermatitis from doxepin cream. One-year patch test clinic experience. *Arch Dermatol* 1996; 132: 515–518.
3. Shelley W D, Shelley E D, Talanin N Y. Self-potentiating allergic contact dermatitis caused by doxepin hydrochloride cream. *J Am Acad Dermatol* 1996; 34: 143–144.
4. Greenberg J H. Allergic contact dermatitis from topical doxepin. *Contact Dermatitis* 1995; 33: 281.
5. Bilbao I, Aguirre A, Miguel Vicente J et al. Allergic contact dermatitis due to 5% doxepin cream. *Contact Dermatitis* 1996; 35: 254–255.
6. Taylor J S, Praditsuwan P, Handel D, Kuffner G. Allergic contact dermatitis from doxepin cream. *Arch Dermatol* 1996; 132: 1516–1518.

Chronic urticaria from an acrylic dental prosthesis

TOMAŽ LUNDER AND MIRJAM ROGL-BUTINA

Department of Dermatovenereology, University Medical Centre, Zaloška 2, SI-1525 Ljubljana, Slovenia

Key words: chronic urticaria; dental prosthesis; methyl methacrylate; dental patients; orthodontics; (meth)acrylates; positive patch test. © Munksgaard, 2000.

(Meth)acrylates are an important cause of occupational allergic contact dermatitis in dental personnel (1, 2), as well as of allergic contact gingivostomatitis and other adverse oral mucous membrane reactions from dental prostheses (3, 4). However, systemic allergic reactions to dental acrylic materials are rare (5, 6).

Case Report

A 49-year-old woman presented with widespread wheals; neither impaired respiratory function nor mucosal lesions were seen. This episode of urticaria lasted for a week. She had a past history of asthma and of salicylate intolerance. She had had some brief episodes of urticaria previously, during the past few years. These were mild and ceased rapidly with oral antihistamines. Increased levels of specific IgE against pork and beef meat had already been found and a corresponding diet instituted. Since then, she had remained asymptomatic until the attack of urticaria described above.

Because of severe whealing appearing daily despite

treatment with antihistamines, she was admitted for further investigation. Oral terfenadine (60 mg/day) and hydroxyzine (75 mg/day) were initiated and gradual improvement achieved. However, no cause was found for her urticaria. In spite of treatment, mild flares of wheals recurred for the next 10 months. Then, the patient herself noted a possible association of urticaria with her dental prosthesis, which she had begun to use 2 months before the onset of the disease. When she gave up wearing it for a few days, the wheals disappeared, and she experienced a flare-up following its reinsertion. There were no visible changes of the oral mucosa throughout the illness. The patient denied burning or itching sensations in the mouth, though she did find the prosthesis uncomfortable.

Patch tests were performed according to ICDRG guidelines and read after 2 and 3 days. Patch testing with the European standard series and a dental series (Hermal) was positive (+) to methyl methacrylate. The patient was also positive (+) to the liquid acrylic monomer K 30[®] (Polident, Slovenia) which had been used to make her denture (Table 1). According to the specification of the manufacturer, this monomer contained methyl methacrylate and *N,N*-dimethyl-*p*-toluidine.

Following patch testing, the patient was advised to remove the denture. 2 weeks later, the flares of wheals had ceased, enabling us to terminate treatment with antihistamines. The patient began to use a new denture not containing methyl methacrylate. Since then, she has been free of skin lesions for more than a year.

Discussion

In contrast to the usual clinical course of allergic reactions to compounds in dental prostheses, our patient did not have visible changes of the oral mucosa, or typical oral symptoms. Contact allergy to compounds used in

Table 1. Patch test results

	D2	D3
methyl methacrylate (2% pet.)	+	+
ethyleneglycol dimethacrylate (2% pet.)	–	–
triethyleneglycol dimethacrylate (2% pet.)	–	–
2-hydroxyethyl methacrylate (1% pet.)	–	–
diurethane methacrylate (2% pet.)	–	–
BIS-GMA (2% pet.)	–	–
<i>N,N</i> -dimethyl- <i>p</i> -toluidine (5% pet.)	–	–
benzoyl peroxyde (1% pet.)	–	–
Polident K 30 [®] monomeric liquid (2% pet.)	+	+
Polident K 30 [®] prepolymer powder (2% pet.)	–	–

BIS-GMA: 2,2-bis[4-(2-hydroxy-3-methacryloxypropoxy)phenyl]propane.

dentures has been implicated in the pathogenesis of various oral mucosal diseases, including stomatitis, lichen planus and burning mouth syndrome (4, 7). In some cases, oral mucous membrane reactions related to the use of dental prostheses have been accompanied by systemic reactions (6). Cases of systemic allergic reactions, e.g., urticaria, without visible oral mucosal lesions are very rare. They have been reported in some cases of allergy to nickel (8, 9) and palladium (10) in dentures, the absence of oral lesions being explained as possibly due to buffering by saliva (11) or structural differences between mucosa and epidermis (12).

To our knowledge, this is the 1st report of widespread urticaria, without visible changes of the oral mucosa, caused by allergy to (meth)acrylate in a dental prosthesis.

References

1. Kanerva L, Estlander T, Jolanki R. Occupational skin allergy in the dental profession. *Dermatol Clin* 1994; 12: 517–532.
2. Rustemeyer T, Frosch P J. Occupational skin diseases in dental laboratory technicians (I). Clinical picture and causative factors. *Contact Dermatitis* 1996; 34: 125–133.
3. Fisher A A. Allergic sensitisation of the skin and oral mucosa to acrylic denture materials. *JAMA* 1954; 156: 238–242.
4. Vilaplana J, Romaguera C, Cornellana F. Contact dermatitis and adverse oral mucous membrane reactions related to the use of dental prostheses. *Contact Dermatitis* 1994; 30: 80–84.
5. Nathanson D, Lockhart P. Delayed extraoral hypersensitivity to dental composite material. *Oral Surg Oral Med Oral Pathol* 1979; 47: 329–333.
6. Bauer A, Wollina U. Denture-induced local and systemic reactions to acrylate. *Allergy* 1998; 53: 722–723.
7. Alanko K, Kanerva L, Jolanki R, Estlander T. Oral mucosal diseases investigated by patch testing with a dental screening series. *Contact Dermatitis* 1996; 34: 263–267.
8. España A, Alonso M L, Soria C, Guimaraens D, Ledo A. Chronic urticaria after implantation of 2 nickel-containing dental prostheses in a nickel-allergic patient. *Contact Dermatitis* 1989; 21: 204–206.
9. Fernández-Redondo V, Gomez-Centeno P, Toribio J. Chronic urticaria from a dental bridge. *Contact Dermatitis* 1998; 38: 178–179.
10. Van Joost T, Roesyanto-Mahadi I D. Combined sensitization to palladium and nickel. *Contact Dermatitis* 1990; 22: 227–228.
11. Levantine A V, Bettley F R. Sensitivity to metal dental plate. *Proc R Soc Med* 1974; 67: 1007.
12. Spiechowicz E, Glantz P O, Axell T, Chmielewski W. Oral exposure to a nickel-containing dental alloy of persons with hypersensitive skin reactions to nickel. *Contact Dermatitis* 1984; 10: 206–211.

Allergic contact dermatitis from diethyl sebacate in lanoconazole cream

MASARU TANAKA, SEIICHIRO KOBAYASHI, TAKAYUKI MURATA, AKIKO TANIKAWA AND TAKEJI NISHIKAWA

Department of Dermatology, Keio University School of Medicine, 35 Shinanomachi, Shinjuku, Tokyo 160-8582, Japan

Key words: allergic contact dermatitis; diethyl sebacate; patch testing; topical medicaments; antifungals; emulsifiers. © Munksgaard, 2000.

Case Report

A 39-year-old Japanese man presented at our clinic with a 1-month history of tinea cruris, which had been treated with 1% lanoconazole cream for 3 weeks. Since a pruritic erythematous plaque developed and enlarged, he visited us again and was given a diagnosis of contact

dermatitis. He was treated with hydrocortisone butyrate ointment and the skin lesion gradually subsided. We performed patch testing with individual ingredients and other antifungals. The results revealed positive reactions to lanoconazole cream as is and 5% diethyl sebacate, an emulsifier ingredient of lanoconazole cream. Other components and other antimycotics were all negative

Table 1. Patch test results

Allergen	% vehicle	D2	D3	D17
lanoconazole cream	as is	?+	+	pig.
diethyl sebacate	5% pet.	?+	+	pig.
all other ingredients of lanoconazole cream		–	–	–
lanoconazole ointment	as is	–	–	–
miconazole nitrate cream	as is	–	–	–
clotrimazole cream	as is	–	–	–
amorolfine monohydrochloride cream	as is	–	–	–
terbinafine hydrochloride cream	as is	–	–	–
butenafine hydrochloride cream	as is	–	–	–

pig.: hyperpigmentation.

(Table 1). The remaining tinea was treated with clotrimazole cream and soon improved.

Discussion

This is the 1st report of allergic contact dermatitis from diethyl sebacate in lanoconazole cream. Contact dermatitis from diethyl sebacate is rare and only 4 cases have been reported (1–3), 2 of which were also from Japan. Previous cases were caused by 15 to 30% diethyl sebacate in the product and showed positive reactions to 1% on patch testing (3). The present patient is considered to have been sensitized with a concentration of 5% in the application, since the patient claimed that the cream was

effective for 2 weeks, and that only after that did the lesion then worsen over 1 week. Diethyl sebacate is widely used in Japan and the USA (3).

References

1. Schneider K W. Contact dermatitis due to diethyl sebacate. *Contact Dermatitis* 1980; 6: 506–507.
2. Sasaki E, Hata M, Aramaki J, Honda M. Allergic contact dermatitis due to diethyl sebacate. *Contact Dermatitis* 1997; 36: 172.
3. Kimura M, Kawada A. Contact dermatitis due to diethyl sebacate. *Contact Dermatitis* 1999; 40: 48–49.

Allergic contact dermatitis due to 1,3-butylene glycol

C. DIEGENANT, L. CONSTANDT¹ AND A. GOOSSENS

Department of Dermatology, University Hospital, KU Leuven, Kapucijnenvoer 33, B-3000 Leuven, Belgium;

¹Dermatologist, Waregem, Belgium

Key words: 1,3-butylene glycol; allergic contact dermatitis; cosmetics; patch-testing technique; repeated open application test. © Munksgaard, 2000.

1,3-butylene glycol is a dihydric alcohol widely used in cosmetics and topical medicaments for its excellent humectant and antibacterial effects, good solubility, low irritant, and low toxic properties. It is also used as a humectant in polyurethane, polyester, cellophane, and cigarettes (1). We are aware only of 10 reports of allergic contact dermatitis from it (2, 5–10).

Case Reports

Case no. 1

A 21-year-old woman, with an atopic constitution but no previous history of allergic contact dermatitis, consulted with a history of an itchy erythema over the whole body, accompanied by edema of the face. This had occurred after the use of a “supertanner” cream directly before sunbath use. The lesions had gradually faded after 3 days.

We patch tested the patient with the Belgian standard series (the European standard series supplemented by budesonide 0.1% eth., propylene glycol 10% aq., sorbitan sesquioleate 20% pet., Euxyl K400 1.5% pet., tixocortol pivalate 0.1% pet., and tosylamide/formaldehyde resin 10% pet), the Belgian cosmetic series, and with her own cosmetics and some of the ingredients available. Only the “supertanner” cream (as is) produced a doubtful (?+) reaction after 2 and 4 days; therefore, the patient was asked to perform a ROAT in an elbowfold with the cream, which produced a strong eczematous reaction after 4 days, with a flare-up of the patch test on the back.

1 month later, she was retested with the ingredients, provided by the manufacturer. Readings after 2 and 4 days showed a positive (++) reaction to the “supertanner” cream (as is) and to the mixture oleoyl tyrosine-butylene glycol-oleic acid. Further patch testing with

1,3-butylene glycol 10% aq. was also positive (++) but the related agents propylene glycol 10% aq. and hexylene glycol 10% aq. were negative.

There was also a positive (++) reaction to fragrance mix. The patch test with the perfume used in the “supertanner” cream, however, remained negative.

Case no. 2

A 25-year-old woman, with a previous history of nickel dermatitis and hand eczema, developed acute dermatitis of the face, neck, and upper chest. The face and eyelids were extremely swollen, for which the general practitioner had administered a corticosteroid injection. 3 days previously, she had applied the same “supertanner” cream as in Case no. 1, followed by sunbath exposure. 24 h later, she had developed slight itching that rapidly became worse.

1 month later, patch tests were performed with the Belgian standard and cosmetics series, which remained negative after 2 and 4 days. Only the “supertanner” cream provoked a fiercely itchy papular eczematous response (++) . A patch test with 1,3-butylene glycol 5% aq. again showed a positive (+) reaction after 4 days. The other ingredients were not tested.

Discussion

1,3-butylene glycol has been claimed to be as good a humectant and preservative potentiator as propylene glycol (3, 4), although it is reported to cause less skin irritation than propylene glycol and so can be considered a good substitute for it (1). There are no reports of cross-reactivity between these 2 substances. There are a few reports of contact allergy due to 1,3-butylene glycol in cosmetics, all by Japanese authors (2, 5–10); 1

patient developed occupational dermatitis from butylene glycol in a soap (9, 10). 2 large-scale group studies, including 364 and 272 patients, give frequencies of contact allergy to 1,3-butylene glycol of 0.4% and 1.1%, respectively, of patients tested (1, 2).

Although 1,3-butylene glycol has been considered a safe cosmetic ingredient and a rare contact allergen, we suggest that allergy to it would be reported more frequently if it were tested regularly. 1,3-butylene glycol (5% aq.) is now being added to the Belgian cosmetics series to evaluate the incidence of positive tests and the incidence of possible cross-reactivity with propylene glycol, the latter having been present in the Belgian standard series since 1993. 5% aq. has been proposed as optimal for patch testing by Matsunaga et al. (1), though we did not observe irritant reactions to 10% aq. in 20 control subjects.

References

1. Matsunaga K, Sugai T, Katoh J, Hayakawa R, Kozuka T, Itoh J, Tsuyuki S, Hosono K. Group study on contact sensitivity of 1,3-butylene glycol. *Environ Dermatol* 1997; 4: 195–201.
2. Sugiura M, Hayakawa R. Contact dermatitis due to 1,3-butylene glycol. *Contact Dermatitis* 1997; 37: 90.
3. Fisher A A. Reactions to popular cosmetic humectants. Part III. Glycerin, propylene glycol, and butylene glycol. *Cutis* 1980; 26: 243–244.
4. Fisher A A. *Contact Dermatitis*, 4th edition. Baltimore: Williams and Wilkins, 1995: 285.
5. Yashiro K, Mishimoto M. A case of contact dermatitis due to 1,3-butylene glycol and trisodiumhydroxyethyl ethylenediamine triacetate. *Environ Dermatol* 1999; 6 (suppl 1): 59.
6. Okada Y, Noda H, Matsunaga K, Hamamatsu T, Kawashima R. Cosmetic dermatitis in 1991. *Skin Research* 1993; 35: 75–80.
7. Matsunaga K, Kato C, Takeuchi M, Kato Y. Allergic contact dermatitis from 1,3-butylene glycol. *The Allergy in Practice* 1994; 14: 492–495.
8. Fujimoto Y, Hayakawa R, Suzuki M, Ogino Y, Kato Y, Hanamura A, Sato A, Hirose O. A case with contact dermatitis due to 1,3-butylene glycol. *Environ Dermatol* 1994; 1: 106–110.
9. Xie Z, Hayakawa R, Sugiura M, Kato Y, Takeuchi Y. Causes of 15 cases with occupational contact dermatitis in the secondary industries. *Environ Dermatol* 1999; 6: 22–25.
10. Xie Z, Hayakawa R, Sugiura M, Kato Y, Takeuchi Y. Causative agents and prognosis of 66 patients with occupational contact dermatitis. *Environ Dermatol* 1999; 6: 133–141.

An outbreak of occupational textile dye dermatitis from Disperse Blue 106

FRANCISCO MOTA¹, ELVIRA SILVA¹, PAULO VARELA¹, ANGELO AZENHA² AND ANTÓNIO MASSA¹

Dermatology Departments: ¹Hospital Geral Santo António (HGSA), Rua D. Manuel II, 4050-345 Porto, ²Hospital S. Marcos, Braga, Portugal

Key words: textile dyes; allergic contact dermatitis; patch tests; occupational; Disperse Blue 106; Disperse Blue 124; thin-layer chromatography; cross-sensitivity. © Munksgaard, 2000.

Textile dyes can be responsible for as many as 5.8% of sensitizations detected in contact dermatitis clinics (1–3), but occupational sensitization is rarely reported.

Patients and Methods

5 women, aged 25 to 34 years, worked in a ready-to-wear shop and presented with 3-month histories of eczema of the axillae, neck, upper extremities, anterior abdominal wall, and, sometimes, the face. The garment suspected

was a dark blue smock, introduced as a working uniform in the last 4 months and worn by about 200 employees.

All 5 patients were patch tested with the Portuguese standard series, which includes 2 mixes of 8 disperse dyes (Table 1) (4). They were also tested with pieces of the suspected garment and a modified and extended textile series, including 33 dyes. Patch testing was performed with Finn ChambersTM on ScanporTM tape, with readings according to ICDRG recommendations.

To characterize the suspected garment, textile fiber composition was obtained from the manufacturer, and thin-layer chromatographic (TLC) analysis was performed on a sample of the smock.

Results

All 5 patients had positive reactions to both disperse dye mixes (Table 1), as well as to pieces of the smock, and subsequently to Disperse Blue 106 and 124. Further patch test results and patient characteristics are summarized in Table 2.

TLC of the garment sample identified 2 azo dyes, Disperse Blue 106 and Disperse Red 1. Textile fiber compo-

Table 1. Disperse dye mixes used in the Portuguese standard series

	8% mix	3.2% mix
Disperse Orange 1	1% pet.	0.5% pet.
Disperse Orange 3	1% pet.	0.5% pet.
Disperse Yellow 3	1% pet.	0.5% pet.
Disperse Red 1	1% pet.	0.5% pet.
Disperse Red 17	1% pet.	0.5% pet.
Disperse Blue 35	1% pet.	0.5% pet.
Disperse Blue 106	1% pet.	0.1% pet.
Disperse Blue 124	1% pet.	0.1% pet.

Table 2. Patient clinical data and patch test results

Patient no.	Age (years)	Sites	Standard series	Dyes positive
1	34	axillae neck upper chest hands (dorsum) eyelids	fragrance mix Myroxylon Pereirae MCI+MI dye mix 3.2% dye mix 8% piece of garment	DB 106 DB 124
2 ^A	25	axillae neck upper chest abdominal wall face	nickel dye mix 3.2% dye mix 8% piece of garment	DB 106 DB 124 DY 3 DR 1 and DR 17 DB 35 DY 9 and DY 64
3 ^B	34	neck hands (dorsum) antecubital fold forearm	nickel dye mix 3.2% dye mix 8% piece of garment	DB 106 DB 124 DB 7
4 ^{A,B}	34	neck forearm	dye mix 3.2% dye mix 8% piece of garment	DB 106 DB 124 DB 7
5 ^B	34	neck fists	nickel formaldehyde dye mix 3.2% dye mix 8% piece of garment	DB 106 DB 124

DB=Disperse Blue; DR=Disperse Red; DY=Disperse Yellow.

^A (Patient nos. 2 and 4): personal history of atopy.

^B (Patient nos. 3 to 5): less extensive dermatitis, due to protective sweatshirt underneath the suspected garment.

sition, as submitted by the manufacturer, was a mixture of synthetic acetate and polyamide.

Discussion

Only around 30 disperse dyes are implicated in about 90% of reported textile dye dermatitis (1). Disperse Blue 106 was 1st reported in 1985 as causing textile allergy in 9 patients (5), dark blouses being the offending garment (5, 6). Other reports have since been published implicating blue synthetic garments containing such dye (3, 7–9).

The chromatographic analysis performed identified Disperse Blue 106. The simultaneous reaction in all patients to the weaker, but similar, allergen, Disperse Blue 124, is seen as a cross-reaction (6, 10), though patients sensitized to Disperse Blue 124 do not always cross-react with Disperse Blue 106 (11, 12).

Our results confirm the inability of PPD to serve as a screening allergen for azo dye allergy (6–13). Patient no. 2 (Table 2) showed positive reactions to 8 dyes of 4 different chemical classes (5 azo, 1 anthraquinone, 1 nitro-arylamine and 1 quinoline), which could be interpreted either as multisensitization or as excited skin syndrome. Patient no. 2 also had a positive patch test to Disperse Yellow 64, for which only 1 previous reference was found (14). Patient no. 5 had a positive reaction to formaldehyde, but no reaction to any of the resins included in the textile series.

To the best of our knowledge, this is the 1st report of occupational sensitization to Disperse Blue 106.

References

- Hatch K L, Maibach H I. Textile dye dermatitis. *J Am Acad Dermatol* 1995; 32: 631–639.
- Seidenari S, Manzini B M, Danese P. Contact sensitization to textile dyes: description of 100 subjects. *Contact Dermatitis* 1991; 24: 253–258.
- Sherertz E F. Clothing dermatitis: practical aspects for the clinician. *Am J Contact Dermatitis* 1992; 3: 55–64.
- Sousa-Basto A, Azenha A. Textile dye mixes: useful screening tests for textile dye allergy. *Contact Dermatitis* 1994; 30: 189.
- Menezes-Brandão F, Altermatt C, Pecqueiro M, Bordalo O, Fousseau J. Contact dermatitis to Disperse Blue 106. *Contact Dermatitis* 1985; 13: 80–84.
- Hausen B M, Menezes-Brandão F. Disperse Blue 106, a strong sensitizer. *Contact Dermatitis* 1986; 15: 102–103.
- Hausen B M. Contact allergy to Disperse Blue 106 and Blue 124 in black “velvet” clothes. *Contact Dermatitis* 1993; 28: 169–173.
- Hausen B M, Kulenkamp D, Börries M. Kontakallergie auf blaue dispersionsfarbstoffe in schwarzen “samt-leggings”. *Art Dermatol* 1991; 17: 337–340.
- Dejobert Y, Martin P, Thomas P, Bergoend H. Multiple azo dye sensitization revealed by the wearing of a black “velvet” body. *Contact Dermatitis* 1985; 33: 276–277.
- Menezes-Brandão F, Hausen B M. Cross reaction between Disperse Blue dyes 106 and 124. *Contact Dermatitis* 1987; 16: 289–290.

11. Gonzalez M A, Heras J A, Guimaraens D, Condé-Salazar L. Dermatitis alérgica de contacto de origen textil. *Dermatitis de contacto-Boletín informativo del GEIDC* 1997; 25: 19–21.
12. Balato N, Lembo G, Paruno C, Ayala F. Prevalence of textile dye contact sensitization. *Contact Dermatitis* 1990; 23: 111–112.
13. Cronin E. *Contact dermatitis*. In Cronin E (ed): *Clothing and textiles*. London, UK, Churchill Livingstone; 1980.
14. Calnan C D. Textile dye disperse yellow 64. *Contact Dermatitis* 1977; 3: 209–210.

Di(2-ethylhexyl) phthalate (DOP) in the dotted polyvinyl-chloride grip of cotton gloves as a cause of contact urticaria syndrome

KEIJI SUGIURA^{1,2}, MARIKO SUGIURA², RITSUKO HAYAKAWA² AND KAZUMI SASAKI³

¹Department of Dermatology, Fujita Health University School of Medicine, 1–98 Dengakugakubo, Kutsukake-cho, Toyoake 470–1192, Japan

²Department of Environmental Dermatology, Nagoya University School of Medicine, 1–1-20 Daikominami, Higashi-ku, Nagoya 461–0047, Japan

³Textile and Chemical Technology Division, Technology Department, National Institute of Technology and Evaluation (NITE), Ministry of International Trade and Industry (MITI), 2–49–10, Nishihara, Shibuya-ku, Tokyo 151–0066, Japan

Key words: contact urticaria syndrome; polyvinyl chloride; cotton gloves; plastic grip; di(2-ethylhexyl) phthalate (DOP); di-n-butyl maleate (DBM); cross-sensitivity; occupational; automobile-tire wholesaler. © Munksgaard, 2000.

Case Report

A 49-year-old automobile-tire wholesaler had had chronic urticaria since 1996, treated with oral antihistamines. We hospitalized him in 1997 with generalized urticaria and severe diarrhea. He was treated with intravenous corticosteroid, an oral antihistamine and an oral antiallergic. His condition improved and he was discharged after 3 weeks of treatment. Soon after, his urticaria recurred.

On reviewing his history, his urticaria usually de-

veloped at work while wearing cotton gloves. A use test with his cotton glove was negative, but when we rubbed his forearm with the palmar side of the glove, which was dotted for grip with polyvinyl chloride (PCV), after 20 min, wheals and flares developed on the rubbed area. A skin biopsy from this area showed lymphocytic and eosinophilic infiltration around the dermal capillaries.

2 g of shavings from the PVC dots were put into a 500-ml Kjeldahl flask with 200 ml acetone and heated at 150°C on a sand bath for 60 min. After filtering with a glass filter (3G160), the solution was extracted again with 200 ml methanol for 30 min. We separated the concentrated solution by column chromatography. The separated solution was concentrated to 10 ml by rotary evaporator. The conditions of column chromatography were as follow: column: 15 mm id×250 mm length; filler: silica gel C-100 (Wako Pure Chemical Industries, Ltd, Osaka, Japan) 10 g; eluents: hexane 100 ml, hexane:

Table 1. Results of prick/scratch testing

Material	Conc./ vehicle	30 min	60 min
no. 0	5% pet.	+	+
no. 1	5% pet.	–	–
no. 2	5% pet.	+	+
no. 3	5% pet.	+	+
no. 4	5% pet.	+	+
no. 5	5% pet.	+	+
DOP	2% pet.	+	+
DBM	2% pet.	–	+
BBP	2% pet.	–	–
EHP	2% pet.	–	–
4-nonylphenol	2% pet.	–	–
extraction residue (low molecular PVC)	as is	–	–
stearyl alcohol	2% eth.	–	–
petrolatum	as is	–	–
ethanol	as is	–	–
distilled water	as is	–	–

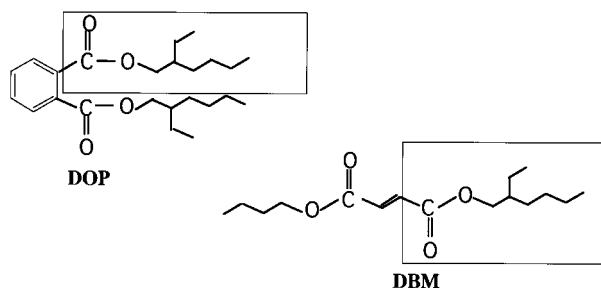


Fig. 1. Chemical structures of DOP and DBM.

chloroform (1:1) 100 ml, chloroform 100 ml, chloroform:methanol (1:1) 100 ml and methanol 100 ml.

We identified the separated chemicals by infrared absorption spectrophotometry and gas chromatography/mass spectrometry (GC/MS).

Infrared absorption spectrophotometry (IR): the separated solutions were put in an agate mortar, respectively, and dried at 60°C; a pellet (3 mm id) for IR was made from the dried material mixed with potassium bromide (KBr); detection was by measuring the infrared absorption spectrum using a Fourier transform infrared spectrophotometer (60SXR).

Gas chromatography/mass spectrometry (GC/MS): 1 ml of the each separated solutions was injected; the conditions were as follows: apparatus: Varian 3400 chromatography system (Varian 3400 Walnut Creek, California, USA) and MAT 90 Mass Spectrometer (Finnigan, Bremen, Germany); column: 5% phenylmethyl silicon (0.25 µm thickness) DB-5MS(J&W), 0.25 mm id×30 m length; carrier gas: helium; column temperature: 50°C (3 min)→rising 10°C/min→320°C (5 min)→cooling; injection mode: 1 µl; injection temperature: 280°C; ionization mode: electron ionization; electron accelerating voltage: 70 V; ion accelerating voltage: 5000 V; ion source temperature: 280°C; mass range: m/z 50–800; scan rate: 1.5 scan/s.

We detected the following chemicals in the extract and separated solutions (numbered as below): di(2-ethylhexyl) phthalate (DOP) in the extract (no. 0), hexane:chloroform elution (no. 2), chloroform elution (no. 3), chloroform:methanol elution (no. 4) and methanol elution (no. 5); butyl benzyl phthalate (BBP) in the extract (no. 0), chloroform elution (no. 3) and chloroform:methanol elution (no. 4). In hexane elution, only oil was detected (no. 1).

We performed prick (water-soluble materials) or scratch (materials in petrolatum) testing with the separated solutions, DOP, di-n-butyl maleate (DBM), BBP, 2-

ethylhexyl phthalate (EHP), 4-nonylphenol, extraction residue (low molecular weight PVC) and stearyl alcohol. As negative controls, we tested distilled water, ethanol and white petrolatum. We found positive wheal-and-flare reactions to solution nos. 0, 2, 3, 4, and 5, and DOP at both 30 min and 60 min, and to DBM at 60 min (Table 1).

Discussion

Phthalic esters, such as DOP, BBP and dimethyl phthalate (DMP), and maleic esters, such as DBM, are widely used as plasticizers in PVC protective gloves. The patient developed stage 3 contact urticaria syndrome (1) when he used cotton gloves coated with PVC dots. The positive results of prick/scratch testing with the extract, solution nos. 1, 3, 4 and 5, and DOP indicated that the most probable cause of the patient's contact urticaria syndrome was DOP. The reaction to the chemically similar DBM (Fig. 1) was considered to be due to cross-sensitivity.

Osmundsen (2) reported a case of contact urticaria due to butylhydroxytoluene (BHT) used as an antioxidant in plastic. Mitchell (3) reported a case of contact urticaria due to an unidentified agent in plastic shower curtains. To our knowledge, there has been no previous report of contact urticaria caused by DOP.

References

1. Amin S, Maibach H I. In: Amin S, Lahti A, Maibach H I (eds): Introduction. *Contact urticaria syndrome*. Boca Raton, FL: CRC Press, 1997: 1–4.
2. Osmundsen P E. Contact urticaria from nickel and plastic additives (butylhydroxytoluene, oleylamide). *Contact Dermatitis* 1980; 6: 452–454.
3. Mitchell J C. Contact urticaria from plastic shower curtains. *Contact Dermatitis* 1986; 9: 329.

The biocide iodopropynyl butylcarbamate (IPBC) as an allergen in cutting oils

I. M. L. MAJOIE AND C. J. W. VAN GINKEL

Department of Dermatology, University Medical Centre Utrecht, P.O. Box 85500, 3508 GA Utrecht, The Netherlands

Key words: allergic contact dermatitis; biocide; preservative; metalworking fluid; cutting oil; iodopropynyl butylcarbamate; occupational. © Munksgaard, 2000.

Additives found in water-based metalworking fluids (MWFs) include biocides, emulsifiers, corrosion inhibitors, coupling agents, extreme-pressure additives, anti-foam agents, hard-water stabilizers, dyes and fragrances (1, 2). In the 1970s, a new biocide was introduced: 3-iodo-2-propynyl-butylcarbamate (INCI: iodopropynyl butylcarbamate; CAS: 55406-53-6). Initially, IPBC was used for water-based paints and wood. Later, it came to be added to metalworking fluids. Now, it is increasingly used in cosmetics, both stay-on and wash-off (3).

Patients and Methods

Patients

In 1995–1999, 23 metalworkers with dermatitis were referred to our department for patch testing, 5 of whom were positive to IPBC.

Patch tests

Patch tests, using Finn Chambers, were performed with the European standard series and an MWF series, sup-

plied by Trolab Hermal (Reinbek, Germany) and Chemotechnique (Malmö, Sweden), respectively. In addition, the MWF in each case was patch tested at 25%, 5% and 1% aq. IPBC, kindly provided by Jan Dekker International (Wormerveer, The Netherlands), was tested at 1%, 0.5% and 0.1% o.o, unless otherwise mentioned. Patch test reactions were scored at 2 and 3 days according to ICDRG guidelines.

Repeated open application test (ROAT)

A ROAT was performed by applying the MWF 2× daily for 1 week on the flexor arm, at its use concentration (usually 5% aq.).

Results

Case no. 1

A 57-year-old non-atopic metalworker had been in such work for 13 years. For 3 years, he had had dermatitis, mainly on the dorsa of the hands. Patch tests with the European standard and MWF series were negative. His MWF (A1) was + only at the 25% dilution (2× in 1 month). IPBC, present in MWF A1, was positive only at 2.5% o.o. (also 2× in 1 month). MWF A1 was replaced by MWF B, which did not contain IPBC, since when the patient has no longer complained of hand eczema.

Case no. 2

A 56-year-old metalworker had been working as such for 32 years. 2 years previously, a new MWF (A1) had been introduced, following which he had developed dermatitis of the dorsal hands and forearms. He had a history of asthma and prick tests were positive for house-dust mite and dog epithelia. Patch tests with the European standard and MWF series were positive to methyl (chloro) isothiazolinone (MCI/MI), which was clinically not relevant. All 3 of his MWFs (A1, A2 and A3) were positive at 25%. IPBC, present in MWFs A1, A2 and A3, was positive at both 2.5% and 0.5% o.o. After changing to an MWF free of IPBC, the dermatitis cleared.

Case no. 3

A 33-year-old metalworker had had dermatitis of the dorsa of the hands, forearms and face for 6 months. He had a previous history of allergic rhinitis and asthma, with positive prick tests to birch and grass pollens, house dust mite and animal epithelia, and a raised total serum IgE (1235 kU/l). Patch tests with the European standard and MWF series showed sensitization to cobalt and colophonium. His MWF (A4) was + at all dilutions as well as at its actual use dilution. IPBC, present in MWF A4, was + at all dilutions tested. For more than 1 year, this patient had been unable to work because of active skin disease. For his company, it was not feasible to replace the brand of IPBC-containing MWF used. Therefore, a change of occupation was advised.

Case no. 4

A 49-year-old manager in a metalworking factory had developed severe hand dermatitis after starting his own company a year ago, having initially been in contact

himself with MWF. Prick tests confirmed reported allergies to cats and horses. Patch tests with the European standard and MWF series were positive to clioquinol and the preservative Bioban CS 1135. His MWF (A4) was + at 25% and 5%. IPBC was + 1% o.o. The supplier of MWF A4 substituted IPBC with a morpholine derivative, since when the patient's dermatitis has improved.

Case no. 5

A 33-year-old non-atopic metalworker had been in such work for 2 years. After the introduction of a new MWF (C1), he had developed dermatitis of the dorsa of the hands and forearms. Patch testing showed + reactions to the preservatives hexahydro-1,3,5-tris (hydroxyethyl) triazine and 1,2-benzisothiazolin-3-one. A ROAT with MWF C1, containing the former of these 2 preservatives, was positive. A change to another MWF (D1) was followed by improvement. However, after a few months, a flare-up of the dermatitis occurred. Both a ROAT with MWF D1, containing IPBC, and patch tests with IPBC at 1% and 0.5% were +. The MWF was again changed, but no follow-up is available due to the patient's subsequent long-term sick-leave for unrelated reasons.

Discussion

Coenraads et al. (4) found a prevalence of eczema of around 11% in Dutch metalworkers. De Boer et al. (5) found skin problems in 58% of 286 metalworkers in another epidemiological study. The contribution of sensitization to such dermatitis varies greatly in reports from 3% to 48% (6–8).

In 1997, Bryld et al. (9) reported 3 cases of allergy to IPBC, one of which was occupational. A recent case of facial dermatitis was reported in which sensitization occurred to IPBC in a cosmetic cream (10). The widespread presence of IPBC currently in moistened toilet tissues incurs further risk, as witnessed by its predecessor methyl dibromo glutaronitrile (11).

IPBC is now commercially available for patch testing, at 0.1% pet. from Chemotechnique (Malmö, Sweden).

References

1. Crow K D. The engineering and chemical aspects of soluble oils. *Br J Dermatol* 1981; 105 (suppl 21): 11–18.
2. Foulds I S, Koh D. Dermatitis from metalworking fluids. *Clinical and Experimental Dermatology* 1990; 15: 157–162.
3. Gruening R. IPBC Preservative combination systems for material protection. *Cosmetics & Toiletries* 1997; 112: 59–65.
4. Coenraads P J, Nater J P, Van der Lende R. Prevalence of eczema and other dermatoses of the hands and arms in The Netherlands. Association with age and occupation. *Clinical and Experimental Dermatology* 1983; 8: 495–503.
5. De Boer E M, Van Ketel W G, Bruynzeel D P. Dermatoses in metal workers (I). Irritant contact dermatitis. *Contact Dermatitis* 1989; 20: 212–218.
6. Alomar A, Condé-Salazar L, Romaguera C. Occupational dermatoses from cutting oils. *Contact Dermatitis* 1985; 12: 129–138.
7. De Boer E M, Van Ketel W G, Bruynzeel D P. Dermatoses

- in metal workers (II). Allergic contact dermatitis. *Contact Dermatitis* 1989; 20: 280–286.
8. Grattan C E H, English J S C, Foulds I S, Rycroft R J G. Cutting fluid dermatitis. *Contact Dermatitis* 1989; 20: 372–376.
 9. Bryld L E, Agner T, Rastogi S C, Menné T. Iodopropynyl butylcarbamate: a new contact allergen. *Contact Dermatitis* 1997; 36: 156–158.

10. Pazzaglia M, Tosti A. Allergic contact dermatitis from 3-iodo-2-propynyl-butylcarbamate in a cosmetic cream. *Contact Dermatitis* 1999; 41: 290.
11. Van Ginkel C J W, Rundervaart G J. Increasing incidence of contact allergy to the new preservative 1,2-dibromo-2,4-dicyanobutane (methylidibromoglutaronitrile). *Br J Dermatol* 1995; 132: 918–920.

Cucumber contact dermatitis

C. O. C. ZACHARIAE

Department of Dermatology, Gentofte Hospital, University of Copenhagen, Niels Andersens Vej 65, DK – 2900 Hellerup, Denmark

Key words: cucumber; allergic contact dermatitis; *Cucumis sativus*; vegetables; plants; greenhouse worker; horticulture; occupational. © Munksgaard, 2000.

Cucumber (*Cucumis sativus*) belongs to the gourd family (Cucurbitaceae), which also includes watermelon, melon, pumpkin, squash and cantaloupe. Besides causing irritant reactions, they can all cause Type I allergies,

especially among catering workers (1, 2). Although skin symptoms are seen, these primarily lead to oral, laryngeal and gastrointestinal reactions (3). Allergic contact dermatitis has not previously been reported from cucumber.

Case Report

A 42-year-old greenhouse worker developed severe work-related eczema of the forearms, lower extremities and, to a lesser degree, the back, 5 months after beginning such work. His job consisted of planting and pruning cucumber plants (Fig. 1) as well as picking cucumbers. The eczema cleared with topical corticosteroids and change of work. The patient had no personal or family history of atopy.

Patch tests with the European standard series, a preservatives series, cucumber stalk, and upper and lower sides of the leaf, gave the results shown in Table 1. As the plants might have been painted with a biological compound against mildew, we retested the patient with fresh non-painted young plants with similar results. Prick tests showed a positive reaction to house dust mite and itching with both sides of cucumber leaf.



Fig. 1. Cucumber plant.

Table 1. Patch-test results

	D2	D3	D7
methylidibromo glutaronitrile 0.3 % pet.	+	++	+
formaldehyde 1.0 % aq.		++	+
cucumber leaf upper side	+	++	+
cucumber stem		fol.	+
cucumber leaf upper side (young plant)	++	++	++
cucumber leaf under side (young plant)	++	++	++
cucumber peel			
cucumber stem (young plant)		fol.	fol.
cucumber ethanol extract		fol.	fol.

Discussion

As cucumber leaves and stalks have irritant hairs on their surface, such irritancy might have explained our patient's patch-test reactions. 10 healthy persons were therefore patch tested with cucumber leaves. 2 such persons had slight redness from cucumber leaf upper side at D3; otherwise no reactions were detected. An ethanol extract of cucumber showed a follicular reaction, while cucumber skin showed no reaction.

No clear relevance for the positive reaction to methyl-dibromo glutaronitrile was found. His positive reaction to formaldehyde might have been relevant, as some of his cleansing agents contained this.

During prick testing, our patient reported itching from cucumber leaf, though no positive reactions could be detected. Wüthrich (4) found cucumber rarely to give immediate-type allergy. Although an association between ragweed pollinosis and hypersensitivity to Cucurbitaceae vegetables has been reported (5), and cucumber has occasionally been reported as causing stomatitis (6), we found no indications that

the positive prick-test reaction to house dust mite was related to the dermatitis.

References

1. Weltfriend S, Kwangsuksith C, Maibach H I. Contact urticaria from cucumber pickle and strawberry. *Contact Dermatitis* 1995; 32: 173–174.
2. Hjort N, Roed-Petersen J. Occupational protein contact dermatitis in food handlers. *Contact Dermatitis* 1976; 2: 28–29.
3. Jordan-Wagner D L, Whisman B A, Goetz D W. Cross-allergenicity among celery, cucumber, carrot, and watermelon. *Ann Allergy* 1993; 71: 70–79.
4. Wüthrich B. Zur Nahrungsmittelallergie. Häufigkeit der Symptome und der allergieauslösenden Nahrungsmittel bei 402 Patienten-kumilchallergie-Nahrungsmittel und Neurodermitis atopica. *Allergologie* 1993; 16: 280–287.
5. Caballero T, Martin-Esteban M. Association between pollen hypersensitivity and edible vegetable allergy. A review. *J Invest Allergol Clin Immunol* 1998; 8: 6–16.
6. Behl P N, Captain R M, Bedi B M S, Gupta S. *Skin-irritant and sensitizing plants found in India, New Delhi*. Irwin Hospital: 1966.

Allergic contact dermatitis from formaldehyde and quaternium-15 in photocopier toner

A. M. ZINA, E. FANAN AND S. BUNDINO

Dipartimento di Discipline Medico-Chirurgiche, Sez. di Dermatologia dell'Università di Torino, Via Cherasco 23, 10126, Torino, Italy

Key words: formaldehyde; formaldehyde releasers, quaternium-15; patch testing; photocopier toner; occupational; airborne; allergic contact dermatitis; office workers. © Munksgaard, 2000.

Concomitant sensitization to formaldehyde and quaternium-15, a well-known formaldehyde releaser, is common. Cosmetics, topical medicaments and industrial materials are the most frequent sources of exposure (1, 2).

Case Report

A 30-year-old driver was occasionally employed on photocopying, for a few days each time and for a few hours each day. He disliked this work intensely and tried in vain to be exempted from it. After some months, he began complaining of worsening pruritus every time he worked with the photocopier. At first this was simply considered a ruse, but he was eventually referred to us. He presented with an itchy faint diffuse erythematous rash on the face and neck, upper trunk and arms, which spontaneously regressed in 1 week. He reported that the itch would start the day after he had begun photocopying, and progressively worsen over 2 or 3 days, while the skin became red, disappearing spontaneously in 1 week

when he returned to work as a driver. Finally, he had begun to scratch if he was just in the same room as the photocopiers.

He was patch tested with the GIRDCA standard series: readings at D2 and D3 were positive to formaldehyde and quaternium-15. A patch test with the photocopier toner as is gave a doubtful reaction. The manufacturer of the photocopier toner confirmed that quaternium-15 was contained in it, though was not prepared to divulge its concentration or function in the product.

Discussion

Photocopier toner has not been reported as a cause of contact dermatitis, though its dust has been related to asthma (3). In this case, we suspect that the heat of the machine in action produced airborne exposure to quaternium-15 and formaldehyde, which was released from the toner. By the time that we examined the patient, an erythematous rash was evident, but for months he had complained solely of pruritus and thus the true nature of his symptoms was not recognized. Photocopying, an

otherwise rather safe activity, must be added to the possible causes of contact dermatitis (4).

References

1. Fransway A F. The problem of preservation in the 1990s (I): statement of the problem, solution(s) of the industry,

- and the current use of formaldehyde and formaldehyde releasing biocides. *Am J Cont Derm* 1991; 2: 6–23.
2. Kränke B, Szolar-Platzer C, Aberer W. Reactions to formaldehyde and formaldehyde releasers in a standard series. *Contact Dermatitis* 1996; 35: 192–193.
 3. Wieriks J. Photocopier toner dust and lung disease. *Lancet* 1996; 348: 1518–1519.
 4. Adams R M. *Occupational skin disease*, 3rd edition. Philadelphia: W B Saunders; 1999: 694–695.

Allergic contact dermatitis from airborne exposure to acrylates

J. L. BONG AND J. S. C. ENGLISH

Department of Dermatology, Queen's Medical Centre, Nottingham NG7 2UH, UK

Key words: allergic contact dermatitis; (meth)acrylates; airborne; occupational; dental patients. © Munksgaard, 2000.

Case Report

A 37-year-old printer originally presented with a 4-year history of hand and periorbital dermatitis which cleared when he was away from work. Patch testing was positive to UV-cured varnish, 2-hydroxymethyl methacrylate, triethyleneglycol dimethacrylate and BIS-GMA. He was moved to an office job with improvement of his dermatitis. Later, he developed severe facial dermatitis after visiting his dentist, who was aware of his allergies and did not use any compound containing (meth)acrylate. His condition resolved with potent topical corticosteroid and has had no further flare-up.

Discussion

(Meth)acrylates are widely used in printing, and allergic contact dermatitis from UV-cured ink is well-docu-

mented (1). Acrylic resins are also commonly used by dentists. Airborne contact allergy to acrylate has been reported in printing (1). In dentistry, most allergic reactions occur in dental staff from direct contact (2). Although our patient was not treated with any acrylic compound by his dentist, small amounts may have been present in dental surgery from previous treatments.

References

1. Nethercott J. Skin problems associated with multifunctional acrylic monomers in ultraviolet curing inks. *Br J Dermatol* 1978; 98: 541–552.
2. Kanerva L, Estlander T, Jolanki R. Allergic contact dermatitis from dental composite resins due to aromatic epoxy acrylates and aliphatic acrylates. *Contact Dermatitis* 1989; 20: 201–211.

Allergic contact dermatitis from chromate and 4-tert-butylphenol-formaldehyde resin in a father and daughter

FÁTIMA PEREIRA AND FÁTIMA CUNHA

Department of Dermatology, Hospital Curry Cabral, Rua da Beneficência, 1000 Lisbon, Portugal

Key words: allergic contact dermatitis; chromate; 4-tert-butylphenol-formaldehyde resin; father; daughter; children; genetics; leather; gloves; shoes. © Munksgaard, 2000.

Case Report

A 7-year-old girl presented with bilateral hand eczema after wearing new leather gloves. 6 months before, she had had an episode of bilateral dorsal foot dermatitis

after wearing leather sandals. Her 38-year-old father also complained of irritation and redness of the dorsa of his feet for the last 2 years, with exacerbation during the summer. They had no personal or family history of atopy. They were patch tested with the Portuguese stan-

lard series and a foot series. The positive results were the same for father and daughter: potassium dichromate, cobalt chloride and 4-tert-butylphenol-formaldehyde resin at D2 (++) and D4 (++) .

Discussion

In both patients, we found relevance for chromate and 4-tert-butylphenol-formaldehyde resin, related to gloves and sandals in the daughter and shoes in the father, though no relevance for cobalt. There are cases reported of contact allergy to the same allergens in monozygous twins and sisters (1, 2) and also reports of HLA antigen and contact allergy associations (3, 4). We have found

no reports of contact sensitivity to the same allergens in parents and children.

References

1. Thestrup-Pedersen K. Contact allergy in monozygous twins. *Contact Dermatitis* 1997; 36: 52–53.
2. Gibson-Smith B, Fleming C J, Forsyth A. Contact sensitivity to tixocortol pivalate in sisters. *Contact Dermatitis* 1998; 38: 351–352.
3. Önder M, Aksakal B, Gülekon A, Makki S, Güler A, Barut A. HLA DR, DQA, DQB and DP antigens in patients allergic to nickel. *Contact Dermatitis* 1995; 33: 434–435.
4. Hegyi E, Buc M, Busová B. Frequency of HLA antigens in persons sensitive to N-isopropyl-N'-phenyl-p-phenylenediamine (IPPD). *Contact Dermatitis* 1993; 28: 194–195.

Hydrolyzed protein shampoo additives are not a common contact allergen

J. P. MCFADDEN, R. J. G. RYCROFT, I. R. WHITE, S. H. WAKELIN AND D. A. BASKETTER¹

St John's Institute of Dermatology, St Thomas's Hospital, London SE1 7EH, UK

¹SEAC Laboratories, Unilever, Sharnbrook, Bedfordshire MK44 1LQ, UK

Key words: keratin; elastin; collagen; contact allergy; contact urticaria; cosmetics; shampoos; hydrolyzed proteins.
© Munksgaard, 2000.

Protein hydrolyzates are added to hair care products and can also be added to soaps, bath gels and creams. There have been occasional reports of contact urticaria from such products (1–4).

We have sequentially patch tested 4 different samples of commercially-used hydrolyzed proteins (5% aq.) from bovine collagen elastin and keratins in 500 patients who attended our contact dermatitis clinic, reading for reactions at 2 and 4 days. We found no positive patch test reactions. Furthermore, we prick tested 25 subjects with scalp dermatitis to these allergens (0.1% aq.), and all were negative.

Reports of contact urticaria from hydrolyzed proteins used in toiletries have appeared since 1990, and in some cases, attacks may be severe (3). In screening a patch-test population, we did not find a positive patch test reaction, which would lead us to postulate that, if it is a contact allergen, it is a relatively rare one. The molecular size of these fragments may well be too high for them to act as contact allergens, but it is possible for larger proteins to act as Type I allergens, and furthermore go on to produce protein contact dermatitis. In other settings, similar animal proteins may cause contact urticaria; indeed, cow dander has been reported as the commonest cause of occupational contact urticaria in Finland (5).

It should also be remembered that other chemicals in hair products may cause contact urticaria (6).

In summary, we found no evidence for hydrolyzed protein acting as a common contact allergen. It is, however, recognized as being capable of producing reactions through a Type I mechanism.

References

1. Kousa M, Strand R, Markinen-Kiljunen S, Hannuksela M. Contact urticaria from hair conditioner. *Contact Dermatitis* 1990; 23: 279.
2. Pasche-Koo F, Claeys M, Hauser C. Contact urticaria with systemic symptoms caused by bovine collagen in a hair conditioner. *Am J Contact Dermatitis* 1996; 7: 56–58.
3. Freeman S, Lee M. Contact urticaria to hair conditioner. *Contact Dermatitis* 1996; 35: 195–196.
4. Niinimäki A, Niinimäki M, Markinen-Kiljunen S, Hannuksela M. Contact urticaria from protein hydrolyzates. *Allergy* 1998; 53: 1078–1082.
5. Kanerva L, Susitavol P. Cow dander; the most common cause of occupational contact urticaria in Finland. *Contact Dermatitis* 1996; 35: 309–310.
6. Torresani C, Periti I, Beski L. Contact urticaria syndrome from formaldehyde with multiple physical urticarias. *Contact Dermatitis* 1996; 35: 174–175.

Contact anaphylaxis due to hair dye

BIJAYLAXMI SAHOO, SANJEEV HANDA, KOMALLA PENCHALLAIAH AND BHUSHAN KUMAR

Department of Dermatology, Venereology and Leprology, Postgraduate Institute of Medical Education & Research, Chandigarh 160 012, India

Key words: contact anaphylaxis; para-phenylenediamine (PPD); hair dye; cosmetics; positive prick test; immediate-type hypersensitivity; contact urticaria. © Munksgaard, 2000.

Case Report

A non-atopic 50-year-old clerk developed swelling of both eyelids 8 h after using Godrej hair dye. Subsequently, the whole face and both lips became swollen. He also developed itchy, exudative lesions on the scalp almost simultaneously. The patient had used another brand of hair dye (Black Rose) for 2 years, though infrequently, but had never experienced similar episodes. There was no history of atopy in the family. On examination, there was extensive periorbital and facial oedema, and multiple eczematous lesions on the scalp. He was unable to open his eyes. No respiratory distress was evident. He was treated with a reducing dose of oral corticosteroid and antihistamines, with clearance within 5 days.

Patch tests with hair dye and the Indian standard series and cosmetics and fragrance series (CODFI), showed sensitivity to Godrej hair dye (10% aq.) (+++), PPD (+++) and nickel sulfate (++). Prick testing revealed sensitivity to Godrej hair dye (10% aq.), with a wheal of 6 mm at 5 min and 10 mm at 20 min, Black Rose hair dye (10% aq.) showing a wheal of only 2 mm at 20 min.

Comment

The most common allergic reaction to PPD-containing hair dyes is contact dermatitis. However, immediate hypersensitivity reactions, including asthma, contact urticaria and anaphylaxis, have also more rarely been described (1–3). This, to our knowledge, is the 1st such report from India.

References

1. Fukunaga T, Kawagoe R, Hozumi H, Kamazaki T. Contact anaphylaxis due to para-phenylene diamine sensitivity to paraphenylenediamine. *Int Arch Allergy Immunol* 1993; 102: 200–204.
2. Belton A L, Chira T. Fatal anaphylactic reaction to hair dye. *American Journal of Forensic Medicine and Pathology* 1997; 18: 290–292.
3. Fukunaga T, Kawagoe K, Hozumi H, Kanzaki T. Contact anaphylaxis due to para-phenylenediamine. *Contact Dermatitis* 1996; 35: 185.

Immediate, anaphylactic and delayed reactions to jellyfish

E. K. EDWARDS JR. AND E. K. EDWARDS SR.

Ridge-Edwards Dermatology Center, 1800 N. Federal Highway, Pompano Beach, Florida 33062, and Department of Dermatology and Cutaneous Surgery, University of Miami School of Medicine, Miami, Florida, USA

Key words: jellyfish; coelenterates; Portuguese man-of-war; *Physalia physalis*; contact urticaria; anaphylaxis; allergic contact dermatitis; emergency medicine. © Munksgaard, 2000.

Case Report

A 16-year-old male surfer was seen as an emergency 30 min after an encounter with a colony of Portuguese man-of-war while surfing off the coast of South Florida. He presented with dozens of 20–30 cm long urticarial streaks on the arms, chest, and face. Within 10 min, he exhibited anxiety, angioedema, coryza, dyspnea, lacrimation, and a sensation of chest constriction. He was immediately given i.v. volume expanders, epinephrine, soluble methylprednisone, diphenhydramine, and metaproterenol by inhalation, to reduce bronchospasm. Within 1 h, all symptoms abated, and 1 h later, the patient was discharged from the emergency room. 1 week after this

incident, he developed an acute, pruritic vesicular eruption which followed the course of the original urticarial streaks. This was treated with a potent topical corticosteroid and cleared after several days.

Discussion

Jellyfish are coelenterates and some species such as the Portuguese man-of-war (*Physalia physalis*) can cause serious systemic reactions in susceptible individuals. The fluid contained in the nematocysts, which are the stinging cells, contains neurotoxins phospholipase A and B, as well as other biologically-active peptides (1, 2).

The simultaneous occurrence of immediate and delay-

ed hypersensitivity is unusual but is being reported with increasing frequency (3, 4). Our patient exhibited typical Type I and Type IV immunologic mechanisms which encompassed contact urticaria, anaphylaxis, and allergic contact dermatitis. Those physicians working near to the coast should be aware of the immunology of jellyfish envenomations, and on the alert for immediate, anaphylactic, and delayed hypersensitivity reactions which may require emergency treatment.

Occupational UVA-induced allergic photodermatitis in a welder due to hydrochlorothiazide and ramipril

S. N. WAGNER, F. WELKE AND M. GOOS

Department of Dermatology, School of Medicine, University of Essen, Hufelandstr. 55, D-45122 Essen, Germany

Key words: photodermatitis; allergic; occupational; UV-induced; welder; ramipril; hydrochlorothiazide; medicaments; adverse drug reactions. © Munksgaard, 2000.

Thiazides commonly cause cutaneous allergic drug reactions, including photosensitivity eruptions (1), and angiotensin-converting enzyme (ACE) inhibitors, of both thiol and non-thiol classes, cause lichen planus- or psoriasis-like drug eruptions or pemphigus/pemphigoid (2, 3). Cutaneous photosensitivity to ACE inhibitors, particularly to the non-thiol ramipril, is less well-known.

Materials heated to more than 2500°C usually emit significant amounts of UV-radiation. Welding arcs often reach temperatures of more than 6000°K (4). Thus, welding is one of the most important occupational sources of UV-radiation. Despite this, very little has so far been reported on the direct or indirect effects of welding on the skin.

Case Report

In July 1997, a 63-year-old welder presented with a 6-year history of edema, erythema, and eczema, along with burning sensations and slowly increasing heat-sensitivity, confined to the face, neck, and, intermittently, extensor forearms. This had started abruptly in spring 1991 with burning and erythema of the face after welding. Within the next few months, especially during summer 1991, the patient had increasing aggravation of skin lesions, initially with edema, erythema, and heat sensitivity, and later with eczema confined to the face, neck, and extensor forearms. He reported worsening of symptoms on exposure to sunlight, but also during welding, with intense burning sensations, even though he used welding goggles or a welding shield to cover the face and/or eyes. In August 1991, diagnosis of contact dermatitis and treatment with topical corticosteroids had resulted in intermittent improvement. On patch testing, he was allergic to fragrance mix and a washing paste. He subsequently avoided applications containing these allergens. Due to his symptomatic heat sensitivity, he also avoided long exposures to sunlight and started using a sunscreen.

References

1. Burnett J. Jellyfish envenomation syndromes. *J Am Acad Dermatol* 1986; 14: 100–106.
2. Burnett J. Venomous coelenterates: chemistry, toxicology, and immunology. *Toxicon* 1987; 25: 581–602.
3. Ohtaki N, Satoh A. Delayed flare-up reactions caused by jellyfish. *Contact Dermatitis* 1993; 28: 112–113.
4. Veraldi S, Carrera C. Delayed cutaneous reactions to jellyfish. *Int J Dermatol* 2000; 39: 28–29.

Despite these efforts, the patient repeatedly had rapid onset of symptoms on welding and remission of such symptoms when off work. Unlike his working colleagues, he reported acute exacerbation of erythema and edema, along with burning sensations, with a 1-day exposure to welding, following a 3-week sick leave with complete clearance of skin lesions in January 1992. The following year, he avoided welding at work and changed his job in June 1993. From that time, his skin condition remained stable with mild eczema and, due to continuing precautions, only slight aggravation in summer.

On presentation in July 1997, the patient showed mild eczema of the face and neck, with submental sparing. He reported drug therapy for essential hypertension, starting in autumn 1990 with a combination of hydrochlorothiazide and ramipril, and from 1992, with ramipril alone. Photopatch tests showed strongly positive reactions to hydrochlorothiazide as well as to ramipril 2 and 3 days after irradiation with 10 J/cm² UVA (320–400 nm). Unirradiated patch tests or patch tests irradiated with UVB or visible light remained negative. Patch tests revealed no reactions to working materials.

Avoidance of ramipril by substitution with another class of antihypertensive agent, use of sunscreens containing a potent UVA-photoabsorber, and treatment with topical corticosteroids resulted in gradual improvement of skin lesions over some weeks. On follow-up over the next few months, his skin lesions cleared completely.

Discussion

Radiation emittance by welding arcs comprises a broad range of wavelengths, i.e., infrared, visible, and ultraviolet light, including the complete spectrum of UVA (4). UV-radiation can occur at exposure levels exceeding those within recommended limits not only in unprotected non-welding individuals near welding stations, but also in welders themselves even if welding helmets are used (5–7). In practice, helmets are often abandoned in

favour of shields or just goggles, as our patient admitted to.

Coincidental photoallergic reactions to 2 different chemical compounds raises the possibility of cross-sensitivity between hydrochlorothiazide and ACE inhibitors (8), though these could simply have been double sensitization. Whereas hydrochlorothiazide is a well-known photoallergen (1), this is the 1st report of photoallergy to ramipril. Physicians should be alert to the possibility of photodermatitis from welding operations.

References

1. Ljunggren B, Bjellerup M. Systemic drug photosensitivity. *Photodermatol* 1986; 3: 26–35.
2. Flageul B, Foldes C, Wallach D, Vignon-Pennamen M D, Cottenot I. Captopril-induced lichen planus pemphigoides

- with pemphigus-like features. *Dermatologica* 1986; 173: 248–255.
3. Ogg G S, Bhogal B S, Hashimoto T, Coleman R, Barker J N. Ramipril-associated lichen planus pemphigoides. *Br J Dermatol* 1997; 136: 412–414.
 4. Sutter E W. Die Schutzwirkung von Abschirmungen für Schweißarbeitenplätze. *Zbl Arbeitsmedizin* 1992; 42: 363–371.
 5. Shehade S A, Roberts P J, Diffey B L, Foulds I S. Photodermatitis due to spot welding. *Br J Dermatol* 1987; 117: 117–119.
 6. Tenkate T S D, Collins M J. Personal ultraviolet radiation exposure of workers in a welding environment. *Am Ind Hyg Assoc J* 1997; 58: 43–48.
 7. Tenkate T S D, Collins M J. Angles of entry of ultraviolet radiation into welding helmets. *Am Ind Hyg Assoc J* 1997; 58: 54–56.
 8. Jaffe I A. The adverse effects profile of sulfhydryl compounds in man. *Am Med* 1986; 80: 471–476.

Systemic contact dermatitis from implanted disulfiram

MARTA KIEĆ-ŚWIERCZYŃSKA, BEATA KRĘCISZ AND BARBARA FABICKA

The Nofer Institute of Occupational Medicine, 8 Św. Teresy Street, 90-950 Łódź, Poland

Key words: disulfiram; tetraethylthiuram disulfide; rubber accelerator; alcoholism; allergy; systemic contact dermatitis; medicaments. © Munksgaard, 2000.

Erythema, urticaria, and pruritus develop shortly after alcohol is consumed by persons who have ingested disulfiram (tetraethylthiuram disulfide, Antabuse). The alcohol-disulfiram reaction is non-allergic. When disulfiram is administered orally or implanted subcutaneously, its reaction with ethanol is based on inhibition of aldehyde dehydrogenase. This block in the metabolism of ingested ethanol results in the accumulation of toxic levels of acetaldehyde, a substrate for the aldehyde dehydrogenase enzyme. Tetraethylthiuram disulfide is also used as an accelerator, activator, stabilizer and vulcanizing agent for various rubber products. Sensitization to thiurams from rubber products may cause ethanol intolerance with accompanying skin lesions. Disulfiram may also be a source of primary sensitivity and, therefore, may cause secondary intolerance to rubber products (1).

Case Report

A 49-year-old cashier in a pharmaceutical company was admitted with suspected ethanol poisoning. 3 months previously, she had been implanted with Esperal® (Kela NV, Belgium) in her left buttock. A pruritic erythema had developed at the site of the implant after 2 weeks.

2 days before her admission, she had started drinking alcohol. A generalized erythema with numerous papules had appeared on the face and extremities, and the dermatitis at the site of the implant had become more severe. The serum ethanol level was 270 mg%. Methanol was not detected.

Table 1 shows the positive patch test results (*Chemotechnique Diagnostics*, Malmö, Sweden). Prick tests with inhalation allergens (*Allergopharma*, Germany) and latex (*Stallergen*, France) were negative. The patient did not report any previous intolerance of rubber products. During her admission, the Esperal® implant was removed.

Discussion

Esperal® (disulfiram) in the form of oral drug or implant may cause allergy (2, 3). Widespread contact dermatitis developing in rubber-sensitive individuals following ingestion of disulfiram has been reported (4–6). Topical exposure to thiuram can also produce an Antabuse reaction when drinking alcohol (1). The same symptoms may be produced if a disulfiram-treated patient absorbs alcohol through the skin from cologne, aftershave lotion, alcohol-based tar gel or beer-containing shampoo (7, 8).

Table 1. Positive patch test results

	D2	D4
European standard series		
thiuram mix	+++	+++
Myroxylon Pereirae	+	++
formaldehyde	+	++
methylchloroisothiazolinone/ methylisothiazolinone	–	+
Rubber additives series		
tetramethylthiuram monosulfide	+	+
tetraethylthiuram disulfide	+++	+++
zinc dimethyldithiocarbamate	–	+

In our patient, the dermatitis was initially present only at the site of the implant. Ingestion of alcohol caused the dermatitis to become generalized. The patient did not report any previous skin lesions at sites of contact with rubber. The results of patch tests were strongly positive to tetraethylthiuram disulfide. The patient also cross-reacted to another thiuram (tetramethylthiuram monosulfide). Reaction to tetramethylthiuram disulfide, the most frequent source of rubber allergy, was not observed.

References

1. Fisher A A. *Contact dermatitis*, 4th edition. Williams & Wilkins, Baltimore, 1995.
2. Van Hecke E, Vermander F. Allergic contact dermatitis by oral disulfiram. *Contact Dermatitis* 1984; 10: 254.
3. Lachapelle J M. Allergic "contact" dermatitis from disulfiram implants. *Contact Dermatitis* 1975; 2: 218–220.
4. Van Ketel W G. Rubber, alcohol and eczema. *Dermatologica* 1968; 136: 442–444.
5. Wilson W B. Side-effects of disulfiram. *Br Med J* 1962; 2: 1610–1611.
6. Webb P K, Bibbs S C. Disulfiram hypersensitivity and rubber contact dermatitis. *JAMP* 1979; 241: 2061.
7. Ellis C N, Mitchell A J, Beardsley G R. Tar gel interaction with disulfiram. *Arch Dermatol* 1979; 115: 1367–1368.
8. Stoll D, King L E Jr. Disulfiram – alcohol skin reaction to beer-containing shampoo. *JAMA* 1980; 224: 2045.

Sorbic acid: an unusual cause of systemic contact dermatitis in an infant

N. RAISON-PEYRON, J. M. MEYNADIER AND J. MEYNADIER

Service de Dermato-Allergologie-Photobiologie, Hôpital Saint-Eloi, 2 Avenue Bertin Sans, 34000 Montpellier, France

Key words: systemic contact dermatitis; sorbic acid; moistened toilet tissue; infant; children; allergic contact dermatitis; preservatives; cosmetics; medicaments; corticosteroids; foods; E200. © Munksgaard, 2000.

Case Report

A 1-year-old girl, without a personal or family history of atopy, presented with itchy, erythematous scaly lesions, confined to both hands for 4 months. The fingertips were affected, associated with nail dystrophy. Her lesions worsened with a topical corticosteroid (desonide 0.1% cream), the eczema extending to the anterior aspects of both wrists.

Patch testing with the European standard series elicited only an IR reaction to cobalt chloride at D2 and D3. We performed patch tests with the infant's emollients and hygiene products (shampoos and soaps). The results were negative, but patch testing with the corticosteroid cream and certain of its ingredients showed a positive reaction to sorbic acid (2% pet.) (+ D2, ++ D3). Other ingredients of this cream, especially the corticosteroid itself, were negative.

Following these results, a careful history from the mother revealed that she often used moistened toilet tissues to clean her hands. Examination of the list of ingredients of these toilet tissues revealed the presence of sorbic acid. Avoidance of these hygiene products and treatment with a corticosteroid free from sorbic acid resulted in rapid improvement of the cutaneous lesions. However, by mistake, the mother again used these moistened toilet tissues to clean the infant's hands, and the same cutaneous lesions reappeared within 24 h. This recurrence and the worsening of the lesions with the corticosteroid cream containing sorbic acid argued that

this contact dermatitis was probably caused by sorbic acid.

Furthermore, several weeks later, reactivation of hand eczema occurred in spite of avoiding hygiene products containing sorbic acid. We suspected systemic contact dermatitis from alimentary ingestion of sorbic acid. Thus, we gave to her mother a list of foods to be avoided. With a sorbic-acid-free diet, and no associated topical treatment, the dermatitis greatly improved.

Discussion

Sorbic acid (E200) and its salts (E201, E202 and E203) are widely used as preservatives in foods. Sorbic acid is present naturally in several red fruits. It is also a preservative of many cosmetic products and topical medicaments containing fatty acids or polyoxyethylene esters (1).

Contact dermatitis from this preservative is relatively rare (2, 3) compared to other preservatives such as methylchloroisothiazolinone/methylisothiazolinone or methylchloro glutaronitrile, which are the most commonly used preservatives in moistened toilet tissues. Sorbic acid is well-known as causing non-immunological contact urticaria, non-specific erythema and burning mouth syndrome (4–7).

Systemic contact dermatitis from ingestion of sorbic acid is uncommon. Only 2 cases have been reported in adults (8, 9). This is the 1st case in an infant, who was

initially sensitized to sorbic acid by moistened toilet tissues.

References

1. Fisher A A. Dermatitis to preservatives and other additives in cosmetics and medications. In: *Contact dermatitis*. Philadelphia: Lea and Febiger, 1986: 241–243.
2. Patrizi A et al. Allergic contact dermatitis caused by sorbic acid: rare occurrence. *Am J Contact Dermatitis* 1999; 10: 52.
3. Ramsing D W, Menné T. Contact sensitivity to sorbic acid. *Contact Dermatitis* 1993; 28: 124–125.
4. Fisher A A. Sorbic acid: a cause of immediate non-allergic facial erythema. An update. *Cutis* 1998; 61: 17.
5. Clemmensen O, Hjorth N. Perioral contact urticaria from sorbic acid and benzoic acid in a salad dressing. *Contact Dermatitis* 1982; 8: 1–6.
6. Rietschel R. Contact urticaria from synthetic cassia oil and sorbic acid limited to the face. *Contact Dermatitis* 1978; 4: 347–349.
7. Lahti A. Skin reactions to some antimicrobial agents. *Contact Dermatitis* 1978; 4: 302–303.
8. Grater W C. Hypersensitivity skin reactions to F.D and C.D dyes. *Cutis* 1976; 17: 1163–1165.
9. Giordano-Labadie F. Systemic contact dermatitis from sorbic acid. *Contact Dermatitis* 1996; 34: 61–62.

Contact dermatitis from parabens used as preservatives in eyedrops

J. VILAPLANA AND C. ROMAGUERA

Unidad de Alergia, Servicio de Dermatología, Hospital Clinic, Barcelona, Spain

Key words: eyedrops; allergic contact dermatitis; parabens; preservatives; medicaments; ophthalmics. © Munksgaard, 2000.

Previous reports rarely include the parabens (1) as contact allergens in eyedrops (2–4).

solubilized in phenoxyethanol, an even rarer sensitizer, but worth patch testing if all else is negative.

Case Report

A 62-year-old farmer had begun treatment 1 year ago with eyedrops containing methylparaben and propylparaben as preservatives. 1 month previously, he had developed conjunctivitis and eyelid dermatitis.

On patch testing, he was ++ at D2 and D4 to the eyedrops (Clarvisan®) as is, and to parabens in the standard series. The eyedrops as is were negative in 25 controls. 1 month later, he was further patch tested with the constituents of the eyedrops, and was ++ at D2 and D4 only to methylparaben and propylparaben, each 3% pet. 25 controls were again negative to all constituents.

Comment

Parabens are said to be among the eyedrop preservatives capable of causing superficial conjunctival inflammation (5), but not usually sensitization (6). Parabens may be

References

1. Rudzki E, Kecik T, Portacha L, Rebandel P, Pauk M. Incidence of hypersensitivity to antibiotics and preservatives in eyedrops. *Klin Oczna* 1995; 97: 66–67.
2. Herbst R A, Maibach H I. Contact dermatitis caused by allergy to ophthalmic drugs and contact lens solutions. *Contact Dermatitis* 1991; 25: 305–312.
3. Herbst R A, Maibach H I. Contact dermatitis caused by allergy to ophthalmics: an update. *Contact Dermatitis* 1992; 27: 335–336.
4. Herbst R A, Maibach H I. Allergic contact dermatitis from ophthalmics: update 1997. *Contact Dermatitis* 1997; 37: 252–253.
5. Becquet F, Goldschild M, Moldovan M S, Ettaiche M, Gastaud P, Baudoin C. Histopathological effects of topical ophthalmic preservatives on rat corneconjunctival surface. *Curr Eye Res* 1998; 17: 419–425.
6. Vadot E, Piasentin D. Incidence of allergy to eyedrops. Results of a prospective survey in a hospital milieu. *J Fr Ophthalmol* 1986; 9: 41–43.

Delayed-type hypersensitivity to heparin with tolerance of its intravenous administration

ROLAND IRION, HELMUT GALL AND RALF-UWE PETER

Department of Dermatology, University of Ulm, Oberer Eselsberg 40, D-89081 Ulm, Germany

Key words: anticoagulation; delayed-type hypersensitivity; heparin-induced thrombocytopenia; heparin; heparinoid; hirudin; intravenous administration; medicaments; prevention; adverse drug reactions. © Munksgaard, 2000.

High-molecular-weight and low-molecular-weight fractionated heparins are now widely used as anticoagulants. Hypersensitivity may present as immediate reactions (urticaria, asthma, anaphylactic shock (1, 13, 18)), Type II hypersensitivity (heparin-induced thrombocytopenia (8, 11, 17)), and delayed-type hypersensitivity (eczematous reaction at site of injection, systemic contact dermatitis (2, 7, 16, 18)).

Patients and Methods

Patients

Patient no. 1, female, 58 years: around a laparoscopy, administration of Mono-embolex[®], total of 5 subcutaneous (s.c.) injections, on the 4th day at the site of injection several erythematous macules ~4 cm in diameter, persisting for 14 days.

Patient no. 2, female, 37 years: following a herniotomy, administration of s.c. heparin injections (heparin sodium, Braun) for 5 days, 3 days after discontinuation infiltrated erythema within region of injection site.

Patient no. 3, female, 64 years: after s.c. injections of

heparin sodium (total of 3 injections), after 2 days erythema with peeling within region of injection site, with subsequent spread over whole abdomen.

Patient no. 4, female, 54 years: around a total prosthetic replacement, administration of s.c. Clexane[®] injections, after 3–4 days persisting erythema within region of injection site.

Patient no. 5, female, 62 years: around an osteosynthesis operation, postoperative administration of s.c. injections (Mono-embolex[®]) for 7 days with no cutaneous reactions; 2 days later, after changing to Clexane[®], persisting erythema within region of injection sites; worsening of symptoms after changing to Calciparin[®].

Prick testing

Prick testing was carried out with a series of low- and high-molecular-weight heparins, as well as the heparinoids danaparoid sodium and sodium pentosanpolysulfate, using the original preparations undiluted on the volar forearm. An immediate reading was carried out after 20 min, and late readings at day (D) 1, 2, 3 and 4.

Table 1. Results of prick, i.d., patch and s.c. tests with a heparin series and heparinoids (strongest test reactions at D1–4 indicated)

Preparations		Patient no. 1	2	3	4	5
heparin sodium (Braun)	prick	–	–	–	+	–
	i.d.	++	–	+	++	++
	patch	–	–	–	–	++
high-molecular-weight heparin	s.c.	NT	+	+	NT	+
heparin sodium (Ratiopharm)	prick	–	–	–	–	–
	i.d.	++	++	–	+++	++
	patch	–	–	–	–	–
high-molecular-weight heparin	s.c.	NT	NT	NT	NT	NT
Fraxiparin [®] (nadroparin calcium)	prick	–	(+)	–	+	–
	i.d.	+	+	+	++	++
	patch	–	–	–	–	++
low-molecular-weight heparin	s.c.	+	NT	+	+	+
Clexane 40 [®] (enoxaparin sodium)	prick	+	+	–	+	–
	i.d.	++	(+)	+	++	+
	patch	–	–	–	++	–
low-molecular-weight heparin	s.c.	NT	+	NT	+	NT
Orgaran [®] (danaparoid sodium)	prick	–	–	–	–	–
	i.d.	–	–	–	++	–
	patch	–	–	–	–	++
heparinoid	s.c.	+	–	+	+	+
SP 54 [®] (pentosanpolysulfate)	prick	–	–	–	–	–
	i.d.	–	–	–	–	–
	patch	–	–	–	–	–
heparinoid	s.c.	–	–	(+)	–	–

i.d.=intradermal, s.c.=subcutaneous, NT=not tested.

Intradermal (i.d.) testing

I.d. testing was carried out with the above-mentioned series of heparins and both heparinoids, again using the original preparations, on the other volar forearm. Readings took place at 20 min, D1, D2, D3 and D4.

Patch testing

Patch testing was carried out on the back with the original preparations undiluted, both with and without tape stripping. Readings were made at D2, D3 and D4.

Provocation testing

S.c. injections into abdominal skin took place with different types of heparin, each time with a therapeutic dose, as well as the heparinoids danaparoid sodium and sodium pentosanpolysulfate.

Intravenous (i.v.) provocation took place at the end of the testing with 5000 IE (international units) heparin sodium (Roche) in 500 ml NaCl 0.9% for 4 h. The follow-up period was 2 days.

Results

Results of prick, i.d., patch and s.c. provocation tests are shown in Table 1. Prick testing with the heparin series and heparinoids was negative at the immediate readings, and predominantly negative at the late readings. I.d. testing was negative at the immediate readings, began to become positive at D2, and infiltrated erythema and papules were still sometimes visible at D4. All patients were negative to the heparinoid sodium pentosanpolysulfate. After s.c. provocation, in cases of positive reactions, infiltrated plaques occurred after 1–2 days at the sites of injection; in contrast, sodium pentosanpolysulfate was tolerated without any reaction. As opposed to this, positive test reactions were noticed in 4 out of 5 patients to danaparoid sodium. The concluding i.v. provocation testing with heparin sodium (Roche) turned out to be negative in all patients.

Discussion

Delayed-type hypersensitivity to s.c. heparin is documented in several case reports and reviews (2, 7, 15, 16), but the question of the i.v. compatibility of heparin in such patients remains debatable. Systemic contact dermatitis might theoretically occur, but this did not happen in our patients. The literature documents only individual cases, reflecting the problematical situation (4, 10, 15). Possible reasons for i.v. tolerance might be difference in antigenic presentation and preferential homing of selectively sensitized thymus-dependent lymphocytes in the dermis (12). Delayed-type hypersensitivity to transdermally administered estradiol can be similarly associated with oral compatibility of the same drug (4). We consider i.v. provocation with heparin to be justified in patients with verified delayed-type hypersensitivity requiring heparin for life-saving surgical procedures.

The semisynthetic heparinoids danaparoid sodium (Orgaran®) and pentosanpolysulfate (SP 54®) are available as therapeutic alternatives. Both have comparable pharmacological characteristics, though they have poly-

saccharide chains with a different chemical structure from heparin. In our patients, pentosanpolysulfate seemed to be the better, in agreement with previous reports (3, 5, 6).

Recombinant hirudin (lepirudin, Refludan®) is available as a further alternative to heparin, and is a protein with differing chemical structure but similar pharmacological characteristics. In Germany, Refludan® is authorized for i.v. anticoagulation in adults with heparin-associated thrombocytopenia type II with thromboembolic complications. Since September 1998, a 2nd hirudin preparation (desirudin, Revasc®) has been authorized (only s.c.) in Germany (9) for anticoagulation in hip and knee replacements.

References

- Bernstein I L. Anaphylaxis to heparin sodium. *J Am Acad Dermatol* 1956; 161: 1379–1381.
- Bircher A J, Flückinger S, Büchner A. Eczematous infiltrates plaques: a type IV allergic reaction. *Br J Dermatol* 1990; 123: 507–514.
- Boehncke W H, Weber L, Gall H. Tolerance to intravenous administration of heparin, an heparinoid in a patient with delayed-type hypersensitivity to heparins and heparinoids. *Contact Dermatitis* 1996; 35: 73–75.
- Boehncke W H, Gall H. Type-IV hypersensitivity to topical estradiol in a patient tolerant to it orally. *Contact Dermatitis* 1996; 35: 187–188.
- Erdmann S, Hertl M, Merk F. Spättypreaktionen auf Heparine und Heparinoide – Hirudin als therapeutische Alternative. *Z Hautkr* 1998; 73: 505–510.
- Gall H, Leiter U, Peter R U. Spättyp-Allergie auf Heparine bei guter Verträglichkeit von Natriumpentosanpolysulfat. *Dermatosen* 1998; 46: 212–215.
- Gonzalo Garijo M A, Arranz Revenga F. Type IV hypersensitivity to subcutaneous heparin: a new case. *J Investig Allergol Clin Immunol* 1996; 6: 388–391.
- Harenberg, J, Huhle G, Piazzolo L, Malsch R. Niedermolekulare Heparine. Prophylaxe und Therapie thromboembolischer Erkrankungen. *Hautarzt* 1997; 48: 852–864.
- Kempkes-Matthes B et al. Therapie der Heparin-induzierten Thrombozytopenie. In: Kempkes-Matthes B (ed): Heparin-induzierte Thrombozytopenie. *Uni-Med* 1999: 42–49.
- Koch P, Bahmer F A, Schäfer H. Tolerance of intravenous low-molecular-weight heparin after eczematous reaction to subcutaneous heparin. *Contact Dermatitis* 1991; 25: 205–206.
- Hofmann A, Kresse R, Lechler E. Heparin-induzierte Hautnekrose bei Heparin-induzierter Thrombozytopenie Typ II (HIT II) mit aortalen Thromben. *Z Hautkr* 1997; 72: 210–212.
- Picker L J, Butcher E C. Physiological and molecular mechanisms of lymphocyte homing. *Ann Rev Immunol* 1992; 10: 561–591.
- Raijka G, Skog E. On the question of heparin hypersensitivity. *Acta Dermato-venereologica* 1962; 42: 27–34.
- Tosti A, Padova P, Patrizi A, Minghetti G, Veronesi S. Unusual reaction to subcutaneous heparin. *Contact Dermatitis* 1985; 13: 190.
- Trautmann A, Bröcker E B, Klein C E. Spättypallergie auf Heparine. *Z Hautkr* 1998; 72: 447–450.
- Valsecchi R, Rozzoni M, Cainelli T. Allergy to subcutaneous heparin. *Contact Dermatitis* 1992; 26: 129–130.
- Wartekin T E, Chong B E, Greinacher A. Heparin-induced thrombocytopenia: towards consensus. *Thromb Haemostas* 1998; 79: 1–7.

Occupational contact dermatitis from ylang-ylang oil

C. ROMAGUERA AND J. VILAPLANA

Unidad de Alergia, Servicio de Dermatología, Hospital Clinic, Barcelona, Spain

Key words: occupational; allergic contact dermatitis; ylang-ylang oil; cosmetics; beauticians; beauty therapists; aromatherapists. © Munksgaard, 2000.

Case Report

A 40-year-old beautician, with no personal or family history of atopy, presented with a 6-month history of itchy erythema and vesiculation on the hands after her day's work, during which she did not wear gloves. On stopping work, she was completely cured within 1 month. She began working again with no problems. 20 days later, coinciding with the application of a massage lotion, she noticed intense itching and, 2 days later, developed hand eczema. On stopping working, she once again became free from all symptoms, and patch tests were carried out with the following results:

	D2	D4
TRUE Test standard series	—	—
Chemotechnique cosmetic series	—	—
massage lotion Locion Ripey® as is	+++	+++
Chemotechnique perfume series:		
ylang-ylang oil 2% pet.	+	++

Patch tests in 20 controls with Locion Ripey® as is were all negative.

The manufacturer of the massage lotion was asked about the possible presence in it of this essential oil and we received no reply, but later chromatographic analysis confirmed its existence.

Comment

A patient wrapping cosmetics was positive to nickel and fragrance mix in the standard series and positive to cinnamic alcohol, cinnamal and ylang-ylang oil in a fragrance series (1). An aromatherapist (2) and a beauty therapist (3) have previously been reported as patch test positive to ylang-ylang oil, among other essential oils.

References

1. Kanerva L, Estlander T, Jolanki R. Occupation contact dermatitis caused by ylang-ylang oil. *Contact Dermatitis* 1995; 33: 198–199.
2. Cockayne S E, Gawkrödger D J. Occupational contact dermatitis in an aromatherapist. *Contact Dermatitis* 1997; 37: 306–307.
3. Keane F M, Smith H R, White I R, Rycroft R J G. Occupational allergic contact dermatitis in 2 aromatherapists. *Contact Dermatitis* 2000; 43: 49–51.