

Case report

Peripheral neuropathy in systemic vasculitis and other autoimmune diseases – a report of five cases emphasizing the importance of etiologic characterization

Rita Rodrigues^{a,*}, Mariana Branco^a, Renata Silva^a, Luís Ruano^{a,b}, Luís Fontão^a, Marta Lopes^c, Horácio Scigliano^d, Ricardo Taipa^e, Manuel Melo Pires^e, Catarina Santos^a

^a Neurology Department, Centro Hospitalar de Entre o Douro e Vouga, Santa Maria da Feira, Portugal

^b Public Health and Forensic Sciences and Medical Education Department, Faculty of Medicine of Porto University, Porto, Portugal

^c Neurology Department, Hospital Privado de Braga Sul, Trofa Saúde Hospitais, Braga, Portugal

^d Anatomic Pathology UNILABS, Santa Maria da Feira, Portugal

^e Neuropathology Unit, Department of Neurosciences, Centro Hospitalar Universitário do Porto, Porto, Portugal

ARTICLE INFO

Keywords:

Multiple mononeuropathy
Acquired polyneuropathy
Systemic vasculitis
Neuropathology
Nerve biopsy

ABSTRACT

Introduction: Peripheral neuropathies may present in the context of systemic vasculitis and other autoimmune diseases. The etiologic characterization is crucial to define the treatment and prognosis in secondary vasculitis. The purpose of this study is to describe the pathway of etiologic investigation including the role of nerve biopsy.

Methods: Retrospective analysis of patients seen in the neuromuscular outpatient clinic during the last four years with peripheral neuropathy in the context of systemic vasculitis or other autoimmune diseases.

Results: We present five patients with stepwise progressive sensorimotor deficits of upper and lower limbs. All patients presented with systemic features and one of them had an established diagnosis of systemic vasculitis. They underwent an extended blood panel, including autoimmune and serologic tests. Electromyography and nerve conduction studies revealed asymmetric axonal sensorimotor polyneuropathies in four patients, and an axonal sensorimotor multiple mononeuropathy in one. Four patients underwent nerve biopsy and the other performed a skin biopsy, with findings suggestive of possible vasculitic processes. The etiologies identified included microscopic polyangiitis, HBV-related polyarteritis nodosa and two eosinophilic granulomatosis with polyangiitis. In the last patient a specific etiology could not be established.

Conclusion: This series reveals the etiologic and phenotypic diversity of peripheral neuropathies related with systemic vasculitis. The therapeutic approach and prognosis were distinct in each patient, emphasizing the importance of a prompt diagnosis and appropriate treatment.

1. Introduction

Peripheral nervous system impairment in systemic vasculitis is often related with poor functional prognosis and increased morbidity, with sensorimotor deficits that are sometimes irreversible [1,2].

Either primary or secondary to autoimmune diseases, vasculitis affecting small arteries or large arterioles are more likely to produce a peripheral neuropathy [3,4]. The primary vasculitis most commonly associated with neuropathy includes polyarteritis nodosa (PAN), essential mixed cryoglobulinemic and anti-neutrophil cytoplasmic antibodies (ANCA) associated vasculitis [5–8]. Among the autoimmune diseases, rheumatoid arthritis, hepatitis B virus (HBV)-associated PAN, and hepatitis C virus (HCV)-related cryoglobulinemic vasculitis are the

most frequent [5,7,8].

The treatment and prognosis of these neuropathies is variable and depend on a correct and individualized etiologic characterization.

2. Methods

We conducted a retrospective study of patients with peripheral neuropathy in the context of systemic vasculitis, seen in the last four years in our neuromuscular outpatient clinic. All patients gave informed consent for publication.

* Corresponding author at: Rua Dr. Cândido de Pinho, 4520-211 Santa Maria da Feira, Portugal.

E-mail address: rita.rodrigues@chedv.min-saude.pt (R. Rodrigues).

<https://doi.org/10.1016/j.ensci.2020.100272>

Received 8 July 2020; Received in revised form 24 August 2020; Accepted 9 September 2020

Available online 11 September 2020

2405-6502/ © 2020 The Authors. Published by Elsevier B.V. This is an open access article under the CC BY-NC-ND license (<http://creativecommons.org/licenses/by-nc-nd/4.0/>).

3. Results

3.1. Patient 1

A 57-year-old male presented with a four-month history of progressive lower limbs livedo and myalgias, plantar dysesthesias and bilateral foot drop. He also had a productive cough, bilateral ankle edema and a constitutional syndrome with involuntary weight loss of 9 kg in two months. A week before the admission he noticed tactile and thermoalgebraic hypoesthesia in the left ulnar nerve territory.

Blood panel showed mild normocytic-normochromic anemia, erythrocyte sedimentation rate (ESR) of 92 mm/h, creatinine of 1.4 mg/dl. He was positive for ANA, ANCA anti-myeloperoxidase, anti-SSA and anti-SSB. HIV, HBV and HCV serologies were negative. Upper and lower gastrointestinal endoscopy, abdominal and renal ultrasound were unremarkable. Chest CT-scan revealed only discrete pleuroparenchymal fibrocatarrical densities in both apices. Cerebrospinal fluid (CSF) analysis was normal. Nerve conduction studies (NCS) revealed an absence or reduction in amplitude of sensory nerve action potentials (SNAP) in the lower limbs. Electromyography (EMG) of lower limb muscles was normal, in keeping with a mild sensory axonal polyneuropathy. A skin biopsy identified an intense inflammatory infiltrate mainly lymphocytic into a skin arteriole wall (Fig. 1A), with internal elastic lamina disruption and fibrinoid necrosis (Fig. 1B). These changes were compatible with a leukocytoclastic vasculitis, supporting the diagnosis of a clinically probable vasculitic neuropathy associated with microscopic

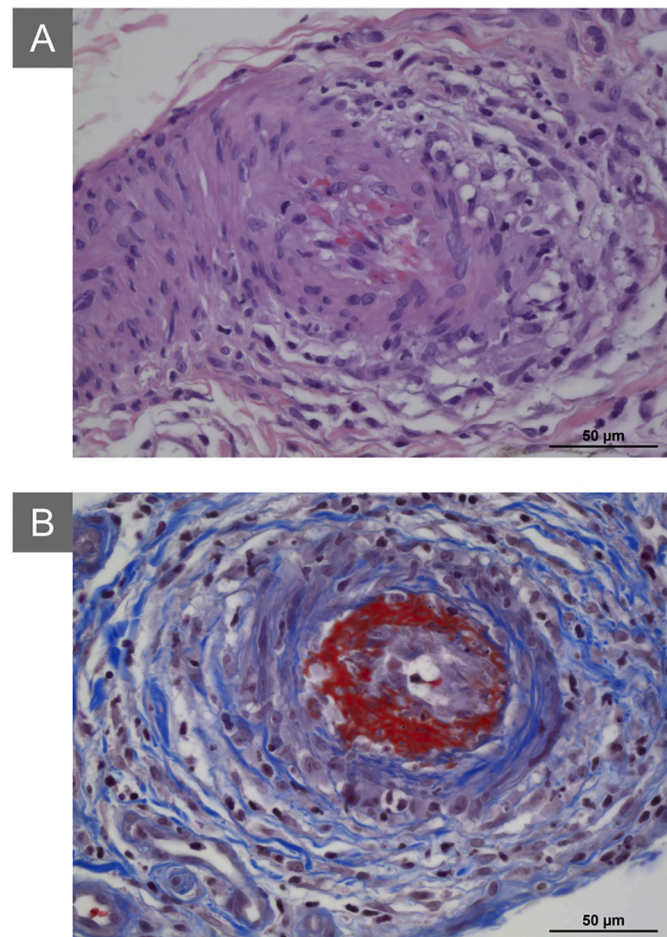


Fig. 1. Microscopic polyangiitis (skin histology) (A) H&E, Skin arteriole with an intense inflammatory infiltrate mainly composed of small lymphocytes into its wall (B) Masson's trichrome, Skin arteriole with disruption of the internal elastic lamina and fibrinoid necrosis. Scale bar: 50 µm (A and B).

polyangiitis, by Peripheral Nerve Society (PNS) criteria [9].

Patient was started on intravenous methylprednisolone 1 g/day during 3 days and then oral prednisolone 1 mg/kg/day, with a clear improvement of pain and constitutional syndrome. Three months later, he was almost completely recovered of motor deficit and corticotherapy was tapered off. Although neurologically stabilized, cyclophosphamide 100 mg/day and then azathioprine 75 mg/day were needed due to renal impairment.

After two years, he reported a relapse of motor deficits and neuropathic pain. He was restarted on oral prednisolone 1 mg/kg/day and azathioprine dose was increased to 100 mg/day, with complete recovery of symptoms within two weeks. The dosages were gradually tapered off, and he is currently under azathioprine 75 mg/day and prednisolone 5 mg/day, without new neurological symptoms.

3.2. Patient 2

A 53-year-old male presented with progressive bilateral lower limb edema, plantar dysesthesias and hypoesthesia in bilateral sural nerves territory, beginning four months earlier, evolving to left foot drop a month later, and right median nerve territory hypoesthesia (thermoalgebraic, vibratory and light touch) and lower limb rash two months after the onset. Blood panel showed an active HBV infection. NCS revealed an absence in SNAP in the lower limbs and a reduction in amplitude of compound motor action potentials (CMAP) in the tibial and peroneal nerves. EMG showed signs of chronic reinnervation and active denervation in distal muscles of the lower limbs, with a slight asymmetric distribution. These findings are consistent with chronic, moderately severe, asymmetric sensorimotor axonal polyneuropathy. A sural nerve biopsy showed perivascular inflammatory infiltrate in a vessel of the perineurium (Fig. 2A) with asymmetric nerve fibre loss (Fig. 2B), suggesting a vasculitic process and allowing the diagnosis of a clinically probable vasculitic neuropathy due to HBV-related polyarteritis nodosa by PNS criteria [9].

He was treated with oral prednisolone 60 mg/day with partial response and was started on tenofovir 2 months after with complete remission of the clinical picture. Three years later, he remains under tenofovir with undetectable viral load and neurologically asymptomatic.

3.3. Patient 3

A 54-year old female, with eosinophilic granulomatosis with polyangiitis (EGPA) with pulmonary involvement and peripheral eosinophilia, presented with progressive lower limbs paresthesias, left foot drop and bilateral painful plantar dysesthesias, beginning four weeks before. One week before, she noticed pretibial skin lesions, bilateral ankle edema and bilateral lower limb tactile hypoesthesia. The day before, she reported involvement of the right foot with bilateral foot drop, and hypoesthesia in the right cubital nerve territory associated with weakness in the fifth finger flexion. She was under a prednisolone tapering regimen, with a decrease to 20 mg/day 2 months before and to 10 mg/day fifteen days before the presentation.

Blood panel revealed eosinophilia of 9200, slightly elevated IgE levels and ANCA anti-myeloperoxidase positive. Chest CT-scan showed patchy upper lobe ground-glass opacities, septal thickening and centrilobular micronodules suggestive of chronic eosinophilic pneumonia. NCS revealed an absence or reduction in SNAP in the lower and upper limbs and an absence or reduction of CMAP in the lower limbs. EMG showed signs of chronic reinnervation and active denervation in distal muscles of the lower limbs, with a symmetric distribution, which is in keeping with a severe sensorimotor axonal polyneuropathy with active denervation. Sural nerve biopsy revealed asymmetric nerve fibre loss (Fig. 3A) and cicatricial changes in the vessel wall with internal elastic lamina disruption (Fig. 3B), supporting a clinically probable vasculitic neuropathy by PNS criteria [9].

The diagnosis of peripheral neuropathy associated with EGPA was

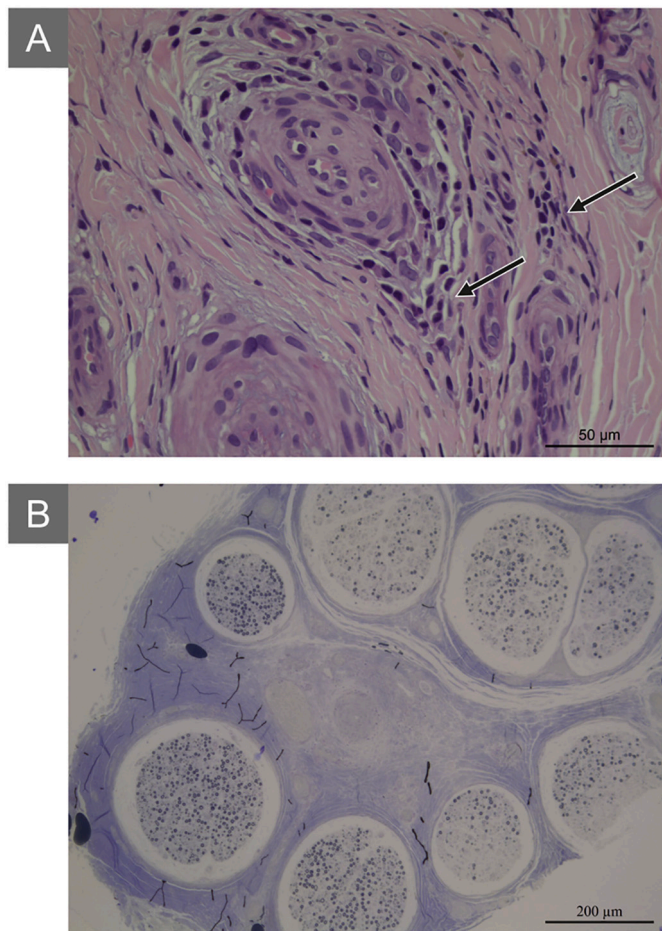


Fig. 2. HBV-related polyarteritis nodosa (sural nerve histology) (A) H&E, Perivascular inflammatory infiltrate surrounding a vessel in the perineurve (arrow) (B) Toluidine blue, Typical asymmetric nerve fibre degeneration (within and between fascicles) secondary to an ischemic etiology. Scale bar: 50 µm (A) and 200 µm (B). (For interpretation of the references to colour in this figure legend, the reader is referred to the web version of this article.)

established, and intravenous cyclophosphamide was started with resolution of neurological symptoms after 3 months. She is free of neurological symptoms since then. However, because of the severe pulmonary impairment, she is currently waiting for a lung transplant.

3.4. Patient 4

A 67-year-old female, with past medical history of asthma and breast cancer HER2+ treated with extended lumpectomy, chemotherapy and radiotherapy, and under trastuzumab each three weeks, presented with progressive distal sensorimotor deficits. She reported bilateral plantar paresthesias and dysesthesias beginning nine days before, evolving to right hand along with a weakness of the right thumb opposition, and then lower limb petechiae, progressive distal tactile and thermoalgebraic hypoesthesia and bilateral foot drop, losing the ability to walk three days before the admission. She had started montelukast due to uncontrolled asthma a week before the symptoms onset.

Blood panel revealed mild normocytic-normochromic anemia, eosinophilia of 13,800, IgE levels higher than 5000 U/l and ESR of 102 mm/h. Autoimmunity tests were negative. Chest CT-scan revealed mild bilateral fibrocontractile changes. CSF analysis was unremarkable. NCS revealed an absence or reduction in SNAP in the lower and upper limbs and an absence or reduction of CMAP in the lower limbs. EMG showed signs of chronic reinnervation and active denervation in distal muscles of the lower limbs, with a symmetric distribution, which is

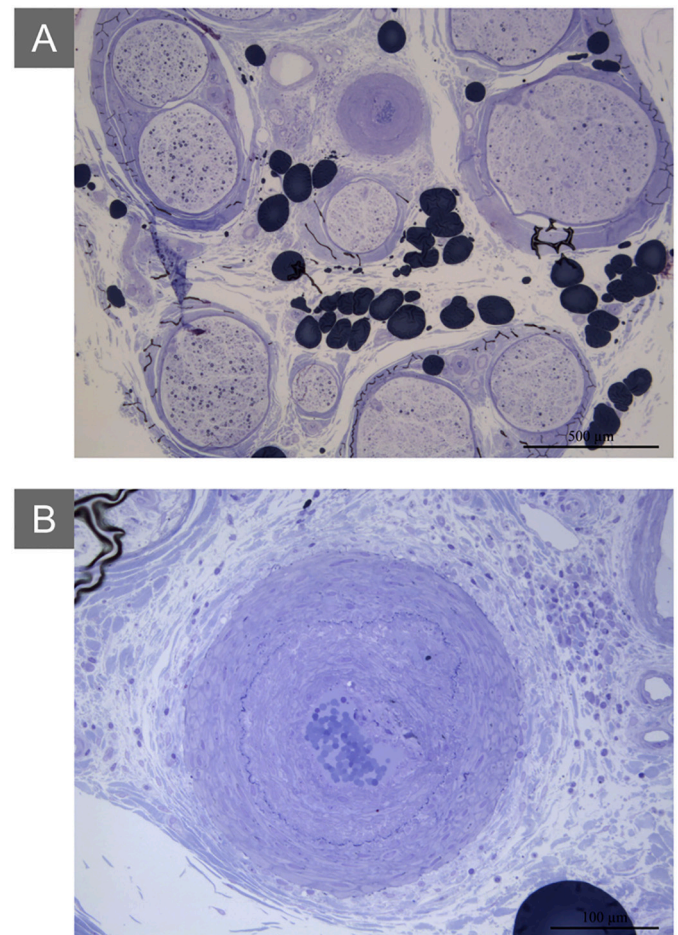


Fig. 3. Eosinophilic granulomatosis with polyangiitis (sural nerve histology), toluidine blue (A) Asymmetric nerve fibre degeneration with no vascular or perivascular inflammatory infiltrate (B) Fibrocontractile changes in the perineurve vessel wall with internal elastic lamina disruption. Scale bar: 50 µm (A) and 100 µm (B). (For interpretation of the references to colour in this figure legend, the reader is referred to the web version of this article.)

concordant with a severe sensorimotor axonal polyneuropathy with active denervation. A skin biopsy showed neutrophilic infiltrate into a skin vessel wall (Fig. 4A) suggesting a leukocytoclastic vasculitis. A sural nerve biopsy revealed cicatricial aspects in a perineurve vessel, including disruption of internal elastic lamina, circumferential intimal hyperplasia (Fig. 4B and C) and intraluminal angiogenesis suggestive of vessel recanalization (Fig. 4B), compatible with a previous vasculitic process. These findings supported the diagnosis of a clinically probable vasculitic neuropathy associated with EGPA by PNS criteria [9].

Montelukast was discontinued and intravenous methylprednisolone 1 g/day during 3 days was started, followed by oral prednisolone 1 mg/kg/day. Patient was discharged after a month slightly better, but still unable to walk.

3.5. Patient 5

A 34-year-old female, with past medical history of rosacea, presented with progressive sensorimotor deficits beginning three weeks before, with tactile hypoesthesia and dysesthesia in the left sural nerve territory. Two weeks after, she developed hypoesthesia and dysesthesia in the right median nerve territory and weakness of the right hand. Three days prior to admission she refers the onset of moderate right hand arthralgia, mostly in the morning, without inflammatory signs.

Blood panel was unremarkable, except for a mild hypocomplementemia and low levels of IgA. CSF analysis showed mild pleocytosis

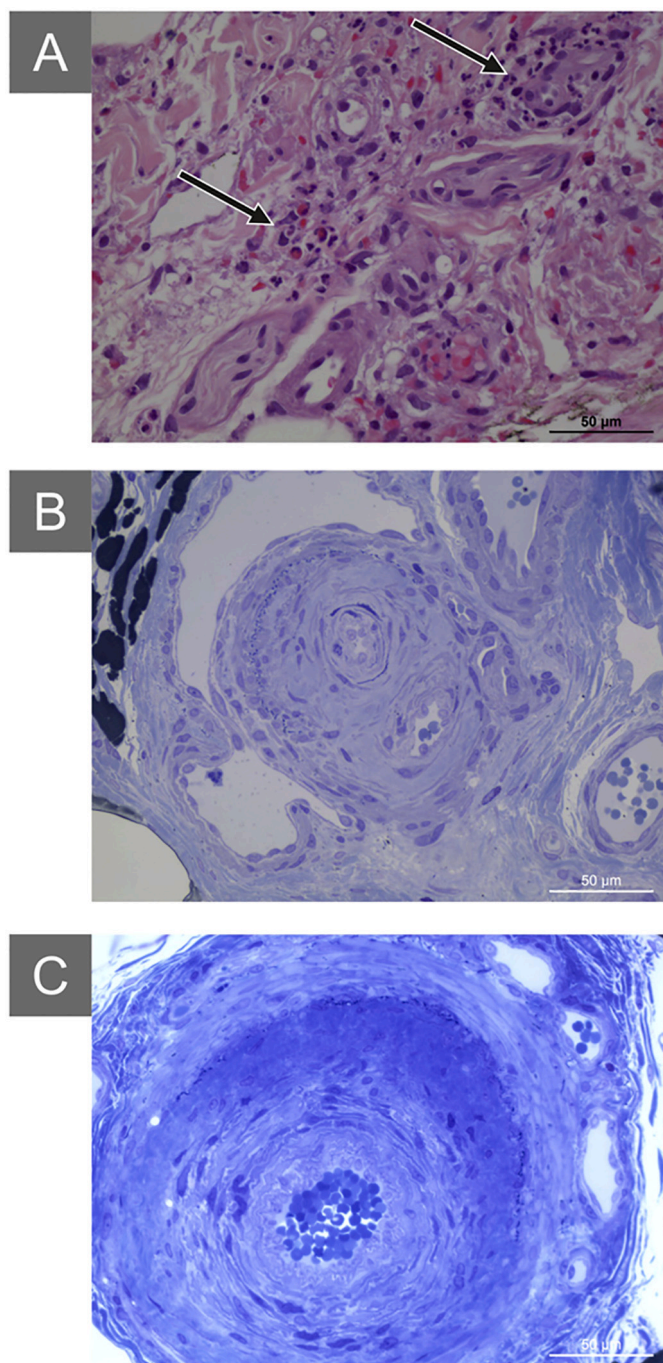


Fig. 4. Eosinophilic granulomatosis with polyangiitis (A) Skin histology, H&E, Inflammatory infiltrate (arrow) mainly composed of small lymphocytes (CD3+, CD10+, CD20-) into a skin arteriole wall (B and C) Perineurium vessels from sural nerve histology, toluidine blue, Perineurium vessels with cicatricial aspects including disruption of internal elastic lamina, circumferential intimal hyperplasia (B and C) and intraluminal angiogenesis (B). Scale bar: 50 µm (A, B and C). (For interpretation of the references to colour in this figure legend, the reader is referred to the web version of this article.)

(29 leukocytes with 51.7% of mononuclear cells) with normal glucose and proteins. The neurophysiological findings were compatible with a multiplex mononeuropathy, revealing an axonal compromise of the right median nerve and the left sural nerve, with a normal EMG. Sural nerve biopsy revealed severe axonal neuropathy, without evidence of regeneration, but with an asymmetric involvement of nerve fibres (Fig. 5), suggesting a clinically probable vasculitic neuropathy by PNS

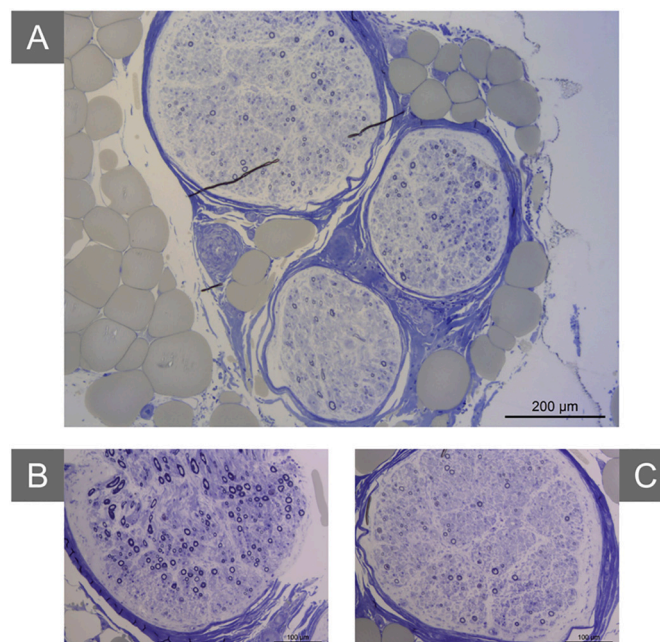


Fig. 5. Undetermined systemic autoimmune disease. Histology of sural nerve, toluidine blue. Severe and active axonal neuropathy with an asymmetric involvement of nerve fibres. Scale bar: 200 µm (A) and 100 µm (B and C). (For interpretation of the references to colour in this figure legend, the reader is referred to the web version of this article.)

criteria [9].

Considering the presence of a peripheral neuropathy associated with a suspected autoimmune disease of unknown etiology, patient was started on oral prednisolone 20 mg/day. However, she did not report any improvement and stopped it because of adverse effects. The symptoms resolved spontaneously one year later and she remains asymptomatic for two years even with no medication.

4. Conclusion

Vasculitic neuropathy has a characteristic clinical presentation with progressive sensorimotor symptoms developing over weeks to months [5,7]. Most patients experience one or more acute attacks, with a stepwise installation of the deficits, but one-third have a chronic slowly progressive course [5,7,8]. Peripheral nervous system vasculitis exhibits three patterns of clinical involvement [3,7]. The commonest and most distinctive one is a multiple mononeuropathy, occurring in 35–65% of the patients with vasculitic neuropathy [3,5]. However, these patients may also present with a distal asymmetric polyneuropathy or, more rarely, a distal symmetric polyneuropathy [3,8]. In this series, all the patients presented with an asymmetric sensorimotor deficit, with a stepwise progression, featuring a pattern of overlapping multiple mononeuropathies, evolving to distal asymmetric polyneuropathies in the first four patients. The constitutional symptoms, as asthenia, anorexia and involuntary weight loss, the skin lesions and/or the specific organ involvement suggested an underlying systemic vasculitis and, although nonspecific, provided clues to the etiological diagnosis.

Despite the clinical similarities, the extensive diagnostic evaluation revealed distinct underlying aetiologies which determined different therapeutic approaches and prognosis. In the first patient, the peripheral nerve involvement was evident at the time of initial presentation. In addition to systemic symptoms, the stepwise progression of the neurological deficits raised the hypothesis of a vasculitic etiology. The diagnosis of a microscopic polyangiitis was supported by laboratory and pathological tests, and the treatment with corticosteroids was started

with a complete resolution of the peripheral neuropathy. The second patient also presented with a stepwise progressive peripheral neuropathy but with more subtle systemic symptoms. The diagnosis of a HBV-related polyarthritis nodosa was decisive to start a directed antiviral treatment besides corticotherapy, emphasizing the importance of a specific etiological diagnosis for initiating the proper treatment. In the third patient, the diagnosis of EGPA was already known and the peripheral neuropathy was not a presenting symptom. However, in this case, the confirmation of a probable peripheral nerve vasculitis supported the escalation of therapy allowing a better neurological prognosis. In the fourth patient, it was the investigation of the neurological symptoms that led to the diagnosis of EGPA. Some authors have reported EGPA as a potential side effect in individuals with moderate to severe asthma on leukotriene receptor antagonists, such as montelukast [10,11]. Because of this reported association, we decided to stop montelukast in addition to the beginning of corticotherapy. This patient also had a past medical history of breast cancer and was under trastuzumab, a monoclonal antibody that was previously reported to cause cutaneous vasculitis [12]. Even though we cannot establish causality between this therapy and the peripheral neuropathy, we believe that this vasculitis must be multifactorial and the chemotherapy may contribute to the clinical picture. To our best knowledge this is the first case of peripheral neuropathy and EGPA described in a patient under trastuzumab. Finally, the last patient had an atypical presentation and course of a possible vascular or vasculitic neuropathy that was assumed to be a part of a systemic autoimmune disease of unknown etiology. The pathological findings in the perinerve were crucial to support this belief and to guide the treatment.

In fact, the pathological studies were very important for the management of our patients, because even without definitive criteria of vasculitic neuropathy, the suggestive neuropathological findings supported our clinical suspicion and supported the use of immunosuppressive therapies. In the first patient, the nerve biopsy was not performed because the patient exhibited typical skin lesions that were more accessible and allowed a prompt diagnosis. In fact, in patients with skin involvement, given its greater accessibility, the skin biopsy can anticipate the decision-making process when the nerve biopsy is delayed, as occurred in two of the patients presented. However, our cases emphasize that the nerve biopsy may be useful to clarify the mechanism of the neuropathy, and it should be considered whenever a vasculitic neuropathy is suspected or as the final step in the diagnostic investigation of a neuropathy of unknown origin [3]. The nerve selection for biopsy was based on careful neurological and neurophysiological examination and a combined muscle biopsy was not performed. Although, it has been suggested that the addition of muscle biopsy improves the yield of definite vasculitis, we also know that one of the most important decisions regarding diagnostic yield is related to the selection of the biopsy site, being crucial to biopsy an affected sensory nerve (with or without muscle) [13,14]. In our experience, the nerve biopsy alone proved to be effective in establishing the diagnosis.

In conclusion, we believe that the etiologic characterization of peripheral neuropathies in the context of systemic vasculitis and other autoimmune diseases is essential to define the natural history and the prognosis of these patients, to prevent potential complications and to optimize the therapeutic approaches. Considering the broad etiologic and phenotypic diversity of peripheral neuropathies, the management of these patients must be individualized in order to identify the underlying etiology.

Declarations

The authors declare that there is no conflict of interest regarding the publication of this paper.

All procedures performed in studies involving human participants were in accordance with the ethical standards of the institutional research committee and with the 1964 Helsinki Declaration and its later amendments or comparable ethical standards.

All patients gave written informed consent for publication.

References

- [1] I.M. Cojocaru, M. Cojocaru, I. Silosi, C.D. Vrabie, Peripheral nervous system manifestations in systemic autoimmune diseases, *Maedica* 9 (3) (2014) 289–294.
- [2] S.M. Helfgott, S. Bhattacharyya, Clinical manifestations and diagnosis of vasculitic neuropathies, in: T.W. Post (Ed.), *UpToDate*, UpToDate Inc., Waltham, MA, 2019, <http://www.uptodate.com>, Accessed date: 1 June 2020.
- [3] M.P. Collins, Dyck PJB, Vasculitides. *Peripheral Nerve Disorders: Pathology and Genetics*, first edition, International Society of Neuropathology, 2014, pp. 175–192.
- [4] A. Vrancken, G. Said, Vasculitic Neuropathy, *Handb. Clin. Neurol.* 115 (26) (2013) 463–483.
- [5] M.P. Collins, W.D. Arnold, J.T. Kissel, The neuropathies of vasculitis, *Neurol. Clin.* 31 (2013) 557–595.
- [6] F. Blaes, Diagnosis and therapeutic options for peripheral vasculitic neuropathy, *Therap. Adv. Musculoskeletal Dis.* 7 (2) (2015) 45–55.
- [7] M.P. Collins, R.D. Hadden, The nonsystemic vasculitic neuropathies, *Nat. Rev. Neurol.* 13 (5) (2017) 302–316.
- [8] N. Beachy, K. Satkowiak, K.G. Gwathmey, Vasculitic Neuropathies, *Semin. Neurol.* 39 (5) (2019) 608–619.
- [9] M.P. Collins, P.J.B. Dyck, G.S. Gronseth, L. Guillevin, R.D. Hadden, D. Heuss, J.M. Léger, N.C. Notermans, J.D. Pollard, G. Said, G. Sobue, A. Vrancken, J.T. Kissel, Peripheral Nerve Society. Peripheral Nerve Society Guideline on the classification, diagnosis, investigation, and immunosuppressive therapy of non-systemic vasculitic neuropathy: executive summary, *J. Peripher. Nerv. Syst.* 15 (3) (2010) 176–184.
- [10] D.L. McDanel, B.A. Muller, The linkage between Churg-Strauss syndrome and leukotriene receptor antagonists: fact or fiction? *Ther. Clin. Risk Manag.* 1 (2) (2005) 125–140.
- [11] J.M. Tuggey, H.S.R. Hosker, Churg-Strauss syndrome associated with montelukast therapy, *Thorax* 55 (2000) 805–806.
- [12] M. Wong, J. Grossman, B.H. Hahn, A.L. Cava, Cutaneous vasculitis in breast cancer treated with chemotherapy - FOCIS Centers of Excellence Review, *Clin. Immunol.* 129 (2008) 3–9.
- [13] C. Vital, A. Vital, M.H. Canon, A. Jaffré, J.F. Viillard, J.M. Ragnaud, C. Brechenmacher, A. Laguény, Combined nerve and muscle biopsy in the diagnosis of vasculitic neuropathy. A 16-year retrospective study of 202 cases, *J. Peripher. Nerv. Syst.* 11 (2006) 20–29.
- [14] K.G. Gwathmey, T.M. Burns, M.P. Collins, P.J.B. Dyck, Vasculitic neuropathies, *Lancet Neurol.* 13 (1) (2014) 67–82.